



Providing Choice & Value

Generic CT and MRI Contrast Agents



**FRESENIUS
KABI**

CONTACT REP

AJNR

Spontaneous intracranial hypotension: spinal MR findings.

B M Rabin, S Roychowdhury, J R Meyer, B A Cohen, K D LaPat and E J Russell

AJNR Am J Neuroradiol 1998, 19 (6) 1034-1039

<http://www.ajnr.org/content/19/6/1034>

This information is current as
of July 6, 2025.

Spontaneous Intracranial Hypotension: Spinal MR Findings

Barry M. Rabin, Sudipta Roychowdhury, Joel R. Meyer, Bruce A. Cohen, Kenneth D. LaPat, and Eric J. Russell

Summary: We report three patients with spontaneous intracranial hypotension in whom spinal MR imaging revealed ventral extradural fluid collections that were centered at the cervicothoracic junction in two patients and extended throughout the entire spine in the third patient. These spinal fluid collections most likely resulted from the accumulation of CSF at the site of dural leakage. Knowledge of this association can be helpful in the selection of imaging studies to facilitate diagnosis and treatment.

Spontaneous intracranial hypotension (SIH) is a syndrome of low CSF pressure characterized by postural headaches in patients without any history of dural puncture or penetrating trauma. Originally described by Schaltenbrand in 1938 (1), SIH is thought to result from an occult CSF leak (1, 2) resulting in decreased CSF volume and, consequently, in low CSF pressure. Recent reports have emphasized the intracranial MR findings in SIH, which include diffuse pachymeningeal enhancement, subdural fluid collections, and downward displacement of the cerebral structures (2–8). There has been only brief mention of associated spinal imaging findings (2, 3, 6, 9). We evaluate the spinal MR findings in three patients with SIH and discuss diagnostic and therapeutic considerations.

Case Reports

Case 1

A previously healthy 29-year-old woman presented with severe positional headaches, aggravated by sitting or standing and relieved by lying down. Intracranial MR imaging revealed diffuse dural enhancement, bilateral convexity, and clival subdural collections. A subsequent lumbar puncture revealed a depressed opening CSF pressure of 40 mm H₂O, but extensive studies of the CSF disclosed no other abnormalities. Serologic studies for collagen-vascular diseases and other systemic conditions were unrevealing.

A few months later, Lhermitte sign developed; that is, electrical sensations that radiated to both upper extremities with

straining. A repeat brain MR study showed tonsillar herniation and persistent dural enhancement (Fig 1A). Spinal MR imaging at this time showed a large ventral extradural fluid collection that extended over the length of the entire spine, causing mild spinal cord compression (Fig 1B and C). This collection was hyperintense relative to CSF on proton density-weighted images and was isointense with CSF on T1- and T2-weighted sequences. The collection did not enhance with intravenous contrast material. Findings at ¹¹¹In-DTPA cisternography were normal.

The patient was treated with analgesics but her symptoms persisted. A diagnostic posterior fossa craniotomy, performed to exclude an inflammatory or neoplastic process, revealed significant dural venous engorgement; however, a right-sided occipital meningeal biopsy specimen showed no dural abnormality. SIH was diagnosed, and the patient was treated with steroids, which produced some symptomatic relief.

A 4-month follow-up MR study of the brain and spine showed resolution of the tonsillar herniation but persistent intracranial dural enhancement and a ventral spinal extradural fluid collection. Owing to the persistent symptoms, standard myelography was performed 1 month later with 14 mL of iohexol (240 mg I/mL) via a lumbar puncture. The examination initially showed ventral compression of the thecal sac by a nonopacified ventral extradural mass, which corresponded to the spinal fluid collection seen on MR images. Delayed filming after 20 minutes with the patient in a supine position showed opacification of the ventral extradural collection, indicating communication between the collection and the thecal sac. However, the exact site of communication between the thecal sac and the ventral fluid collection could not be determined. Postmyelographic CT of the entire spine performed with the patient supine after approximately 30 minutes showed differential opacification of the thecal sac and the ventral fluid collection.

Over the next few months, after discontinuation of steroid treatment, the patient's symptoms improved to almost complete resolution.

Case 2

A 27-year-old previously healthy woman presented with a 2-week history of positional headaches associated with horizontal diplopia. The neurologic examination was otherwise normal. Routine laboratory studies, including erythrocyte sedimentation rate, were normal. Two attempted lumbar

Received December 23, 1996; accepted after revision November 11, 1997.

Presented in part at the annual meeting of the American Society of Neuroradiology, Seattle, June 1996.

From the Departments of Radiology (B.M.R., S.R., E.J.R.) and Neurology (B.A.C.), Northwestern Memorial Hospital, Northwestern University Medical School, Chicago; the Department of Radiology, Evanston Hospital, Northwestern University Medical School, Evanston (J.R.M.); and the Department of Radiology, Trinity Hospital, Chicago (K.D.L.).

Address reprint requests to Barry M. Rabin, MD, Department of Radiology, Olson Pavilion, Northwestern Memorial Hospital, 710 N Fairbanks Ct, Chicago, IL 60611.

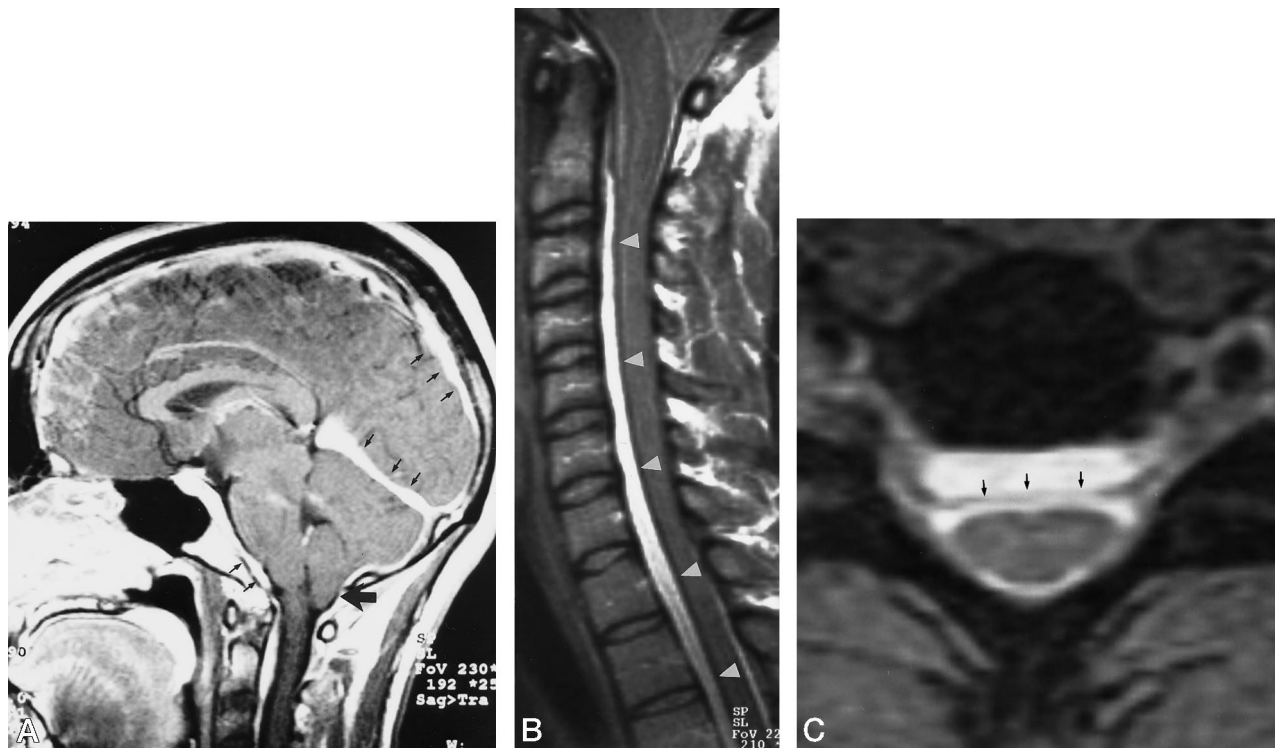


FIG 1. Case 1: 29-year-old woman with severe positional headaches, aggravated by sitting or standing and relieved by lying down. A, Midline sagittal contrast-enhanced T1-weighted (330/15/2) image of the brain shows marked enhancement of thickened pachymeninges (small arrows) and downward displacement of the cerebellar tonsils (large arrow).

B, Sagittal proton density-weighted (2000/19/1) image of the cervical spine shows a large ventral extradural fluid collection (arrowheads) that is hyperintense relative to CSF. The collection was isointense with CSF on T1- and T2-weighted images. There is no contrast enhancement of the collection or adjacent dura. There is moderate compression of the spinal cord. Thoracic and lumbar MR images (not shown) showed continuation of this cyst to the lumbosacral junction.

C, Axial T2-weighted gradient-echo (700/15/4) image at the C6–7 shows the ventral extradural fluid collection separated from the thecal sac by hypointense dura (arrows).

punctures, one of which was fluoroscopically guided, were unsuccessful in obtaining CSF (ie, a “dry tap”). Later aspiration yielded 5 mL of CSF, which showed elevated protein (462 mg/mL). Intracranial contrast-enhanced MR imaging performed before the lumbar puncture showed diffuse pachymeningeal enhancement and bilateral convexity, subdural fluid collections, supporting the diagnosis of SIH.

Spinal MR imaging performed after the initial failed lumbar puncture revealed a ventral extradural fluid collection at the cervicothoracic junction that was isointense with CSF on all sequences. The collection enhanced mildly with intravenous contrast administration. No significant spinal cord compression was noted. Adjacent to this collection were dilated epidural veins (Fig 2).

Indium-111 DTPA cisternography showed limited ascent of the radionuclide to the level of the basal cisterns, consistent with intracranial hypotension. There was early visualization of the bladder. A definite site of CSF leak was not identified.

The patient did not respond to analgesics, so a lumbar epidural blood patch was performed, which provided temporary relief, although the headache recurred within a few days. A second epidural patch was placed within the thoracic spine at T9–10, closer to the extradural fluid collection, which resulted in prompt relief of symptoms without recurrence.

Case 3

A 37-year-old previously healthy woman awoke with diffuse postural headache associated with nausea, vomiting, and vertigo. Neurologic examination revealed a positive Romberg sign, and gaze to either side elicited unsustained horizontal nystag-

mus. The remainder of the neurologic examination was normal. A lumbar puncture revealed an unmeasurable opening pressure, a white blood cell count of 11 mm^3 ($10^6/\text{L}$) (69% lymphocytes, 31% monocytes), a protein level of 85 mg/dL, and a normal glucose level. Cultures were sterile, and cytologic examination was normal.

Intracranial MR imaging performed before the lumbar puncture showed diffuse dural enhancement and bilateral convexity, clival subdural collections, supporting the diagnosis of SIH.

Spinal MR imaging performed before the lumbar puncture revealed a ventral extradural fluid collection at the cervicothoracic junction that was isointense with CSF. There was mild enhancement of the collection and adjacent dura with intravenous contrast administration. No significant spinal cord compression was noted (Fig 3). Indium-111 DTPA cisternography showed limited ascent of the radionuclide to the level of the cervicothoracic junction and early bladder visualization without a demonstrable site of CSF leak.

SIH was diagnosed, and the patient was treated with a lumbar epidural blood patch at L2–3, resulting in complete and sustained resolution of symptoms.

Discussion

Spontaneous intracranial hypotension is defined as a syndrome of reduced CSF pressure that occurs in the absence of dural puncture, surgery, or trauma (1–3). The pathogenesis is usually considered to be an occult CSF leak through small defects in the meninges with a resultant decrease in CSF volume and

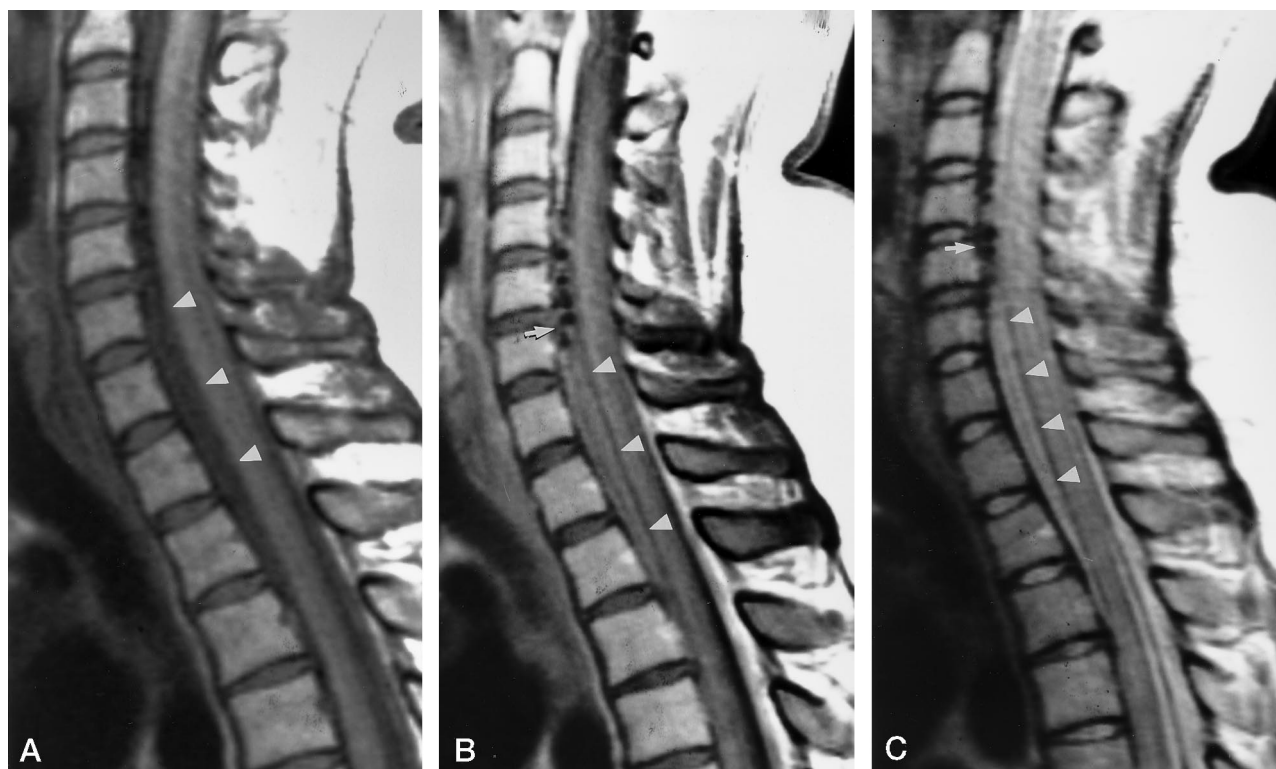


FIG 2. Case 2: 27-year-old woman with 2-week history of positional headaches associated with horizontal diplopia. Sagittal T1-weighted (600/12/5) (A), contrast-enhanced T1-weighted (600/12/5) (B), and proton density-weighted (3500/22/2) (C) images of the cervicothoracic spine show a small ventral extradural fluid collection (arrowheads) that is isointense with CSF. Note the mild enhancement of the fluid collection on the contrast-enhanced image (B). In addition, prominent flow voids are evident in the ventral epidural space at C-3 to C-5 (arrow, B and C) adjacent to the fluid collection, caused by prominent epidural veins. The intracranial dural enhancement continues into the upper cervical spine.

pressure (2, 3). The characteristic headache in SIH is similar to postlumbar puncture postural headache in that it is aggravated by sitting or standing and relieved by lying down (2, 3, 6). Other associated symptoms, seen less commonly, include stiff neck, nausea and vomiting, diplopia, and cranial neuropathies, producing vertigo, tinnitus, photophobia, and changes in hearing (3, 6). CSF may be normal or reveal increased protein, xanthochromia, or lymphocytic pleocytosis. By definition, the CSF pressure in SIH is low (less than 60 mm H₂O) and may be unobtainable via lumbar puncture, the so-called dry tap (2, 4). Treatment options for intractable headache in SIH are similar to those for postdural puncture headache and include bed rest, analgesics, sedatives, oral caffeine, intravenous hydration, epidural blood patch, or epidural saline infusion (2). The usual clinical course of SIH in most patients is spontaneous resolution over a period of weeks to months.

The diagnostic intracranial imaging findings of SIH have been well described in the literature and are thought to be a result of low CSF pressure (2–8). On T1-weighted sequences with intravenous contrast administration, there is diffuse, intense pachymeningeal enhancement with characteristic continuous involvement of the dura and sparing of the leptomeninges. Fishman and Dillon (3) postulated the cause of intracranial pachymeningeal enhancement in SIH to be vascular dilatation within the dura mater rather than

meningeal inflammation. With low CSF pressure, there is secondary vascular, predominantly venous, dilatation in the dura mater in accordance with the Monro-Kellie rule (3), which states that the CSF volume fluctuates with intracranial blood volume in an intact skull. Support for this theory of pathogenesis includes lack of dural inflammation detected on meningeal biopsy specimens (5, 6) and, as in our case 1, dural venous engorgement observed during meningeal biopsy. Other intracranial MR findings include subdural fluid collections (2–4, 6, 8), thought to result from hydrostatic pressure changes in the CSF (6), and downward displacement of the brain structures seen on midsagittal images (4), presumably caused by low CSF pressure, as observed in our case 1. Slitlike ventricles and small basal cisterns and sylvian fissures have also been described on cross-sectional imaging studies.

The spinal manifestations of SIH have only been alluded to in the literature (2, 3, 6, 9). Rando and Fishman (2) reported two patients with SIH. One patient had leakage of intrathecal contrast and radionuclide into the extradural space at the C6–7 level on CT myelography and cisternography, respectively. The second patient had a leak at the C7–T1 level on radionuclide cisternography, which corresponded to MR findings of dilated perineural root sleeves, thought to be the site of CSF leakage. Fishman and Dillon (3) described a case of SIH with accumulation

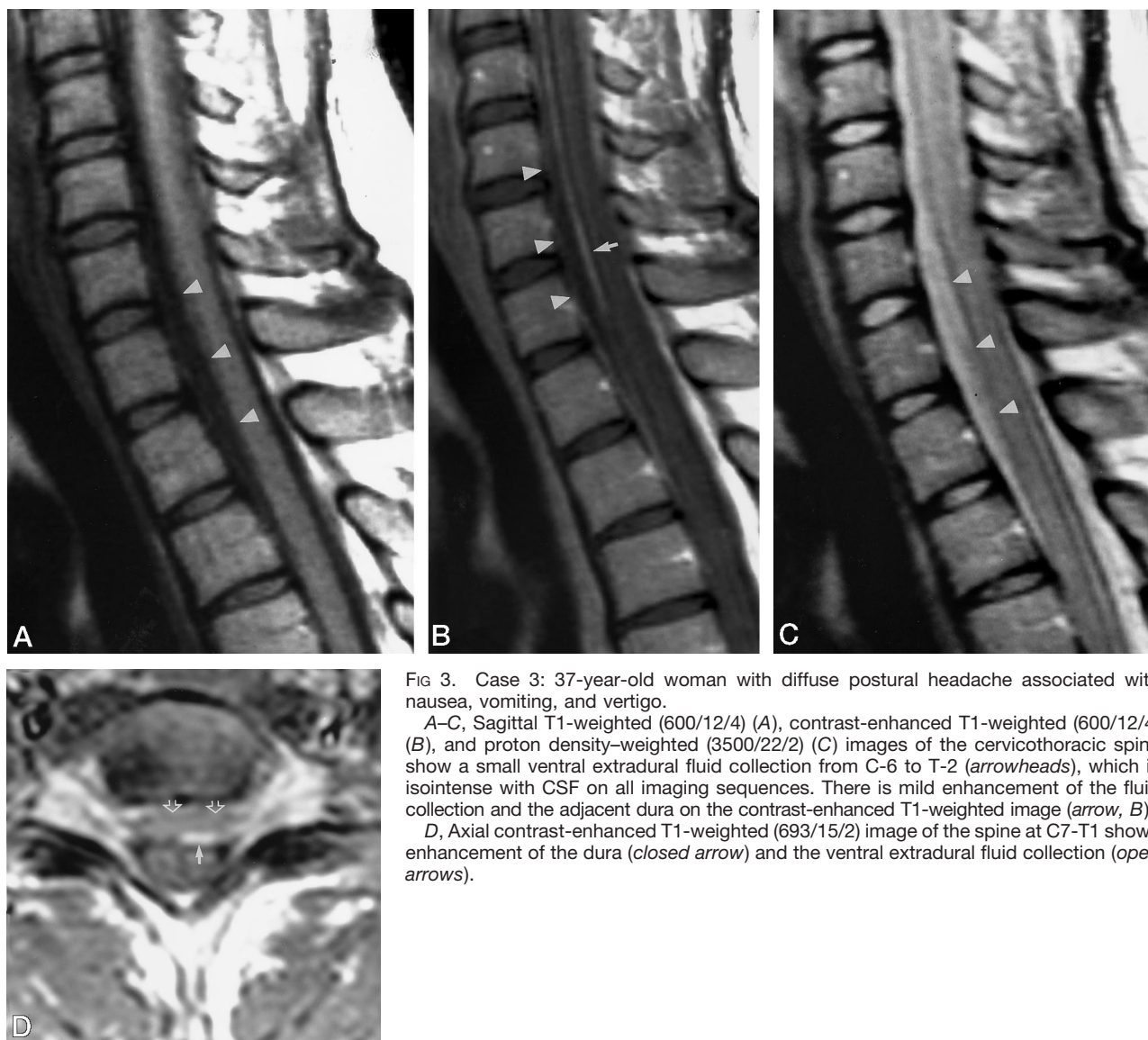


FIG 3. Case 3: 37-year-old woman with diffuse postural headache associated with nausea, vomiting, and vertigo.

A–C, Sagittal T1-weighted (600/12/4) (A), contrast-enhanced T1-weighted (600/12/4) (B), and proton density-weighted (3500/22/2) (C) images of the cervicothoracic spine show a small ventral extradural fluid collection from C-6 to T-2 (arrowheads), which is isointense with CSF on all imaging sequences. There is mild enhancement of the fluid collection and the adjacent dura on the contrast-enhanced T1-weighted image (arrow, B).

D, Axial contrast-enhanced T1-weighted (693/15/2) image of the spine at C7-T1 shows enhancement of the dura (closed arrow) and the ventral extradural fluid collection (open arrows).

of radionuclide and intrathecal iodinated contrast at the T12-L1 level on cisternography and myelography, respectively. Mokri et al (6) described a case of SIH with a collection of fluid within the cervical spine on MR imaging. Schievink et al (9) reported 11 cases of SIH with spinal CSF leaks documented by radionuclide cisternography and CT myelography.

Although spinal imaging is not a necessity for the diagnosis of SIH, these examinations may be ordered because of spinal symptoms caused by the fluid collection or by clinicians unfamiliar with the syndrome who want to exclude a spinal block after an unsuccessful spinal tap. The spinal MR was performed in case 1 because of myelopathic symptoms; it was ordered in cases 2 and 3 to exclude an obstructing mass lesion as the cause of the dry tap or low opening pressure, respectively.

While spinal MR imaging is not essential for the diagnosis of SIH, our cases suggest that spinal extradural fluid collections may be an important finding on spinal MR images in patients with SIH, and they

support this diagnosis. These spinal fluid collections tend to be isointense with CSF on T1- and T2-weighted MR images. In one of our cases, the collection was hyperintense relative to CSF on the proton density-weighted images, which was thought to be due to decreased CSF pulsation within the extradural collection, which is relatively isolated relative to CSF in the subarachnoid space of the thecal sac and thus does not exhibit the characteristic signal loss of pulsatile subarachnoid CSF (10). Another possible cause of the increased signal intensity of the spinal collection may be increased protein content within the collection as compared with CSF. Mild enhancement of the fluid collection or the adjacent dura may occur. The origin of the enhancement is uncertain, but it may represent delayed leakage of contrast material into the collection, analogous to spinal subdural enhancement after suboccipital craniectomy (11) or to enhancement of pineal cysts (12). Dural enhancement is probably due to dural venous engorgement related to compression by the cyst. One case showed

prominent flow voids adjacent to the spinal fluid collection that were believed to represent epidural veins that were dilated because of impaired venous drainage consequent to compression by the spinal cyst.

Spinal fluid collections may or may not be symptomatic, depending on their size and relative mass effect upon the spinal cord or nerve roots. One patient with a large spinal cyst had myelopathic symptoms and Lhermitte sign as a result of cord compression. The other patients had no symptoms referable to smaller spinal cysts.

While the intracranial subdural fluid collections in SIH are believed to be due to CSF hydrostatic changes (2), the spinal fluid collections are likely caused by extradural CSF leakage and accumulation. This theory is supported by the observed communication between the extradural spinal collection and the thecal sac seen at CT myelography in our case 1 as well as by cases described in the literature (2, 3, 9). Although we found no direct evidence of a focal leak of radionuclide, cisternography can document the extraarachnoid accumulation of tracer, suggesting a site of CSF leakage (2, 3, 9). Furthermore, early bladder visualization stemming from rapid systemic absorption of radionuclide can suggest an occult leak (2), as seen in two of our patients. Other investigators have identified dilated nerve root sheaths (Tarlov cysts) in patients with SIH that may predispose to small dural tears (2, 3). Our cases showed no such variants.

While spinal MR imaging will not show the direct site of CSF leak, the location of the spinal fluid collection may correspond to the region of CSF leakage (ie, cervical, thoracic, or lumbar locations). It may be more useful to attempt direct localization of the CSF leak with CT myelography or radionuclide cisternography first. If direct localization is unsuccessful, as it was in all three of our cases, spinal MR imaging may be useful to show the region of the CSF leak.

In two of our patients, the spinal extradural fluid collections were located at the cervicothoracic junction, indirectly implicating this region as the site of CSF leakage. In the third patient, the extradural cyst involved the entire spine, and the site of CSF leakage could not be determined. In the two patients described by Rando and Fishman (2), CSF leaks were documented at the cervicothoracic junction by radionuclide cisternography. Furthermore, the cysts were ventrally located in the patients reported by Rando and Fishman (2) as well as in all of our patients. Schievink et al (9) reported CSF leaks occurring in the cervical spine in two patients, the cervicothoracic junction in three patients, the thoracic spine in five patients, and the lumbar spine in one patient. Thus, the ventral cervicothoracic junction and the thoracic spine appear to be the most common locations for the occult tear and subsequent CSF leakage.

None of our patients responded to conservative management. Two of them had epidural blood patches, one experienced prompt sustained symptomatic relief from a lumbar epidural blood patch, and the other required a second epidural blood patch, which was placed at a higher level, in the thoracic

spine, after failure of the initial lumbar patch. Alternatively, epidural blood patches can be performed on an inclined table from a lumbar approach with Trendelenburg positioning, which allows the blood to be directed to the thoracic or cervical levels (13). Identifying the location of the spinal fluid collection might help direct the placement of a therapeutic epidural blood patch in patients who do not respond to conservative therapy (14). In our cases, MR identification of the extradural cysts suggested the level of the CSF leak in spite of nonlocalizing findings on radionuclide cisternography, which has been reported to have a 30% false-negative rate (9).

The differential diagnosis of spinal extramedullary cystic lesions includes epidural hematoma and abscess, type 1 meningeal cyst, arachnoid cyst (type 3 meningeal cyst), and neurenteric cyst. The spinal cyst associated with SIH can be differentiated from epidural hematoma by its isointensity with CSF on T1-weighted MR images. Epidural abscesses usually show thick peripheral enhancement, unlike SIH-associated cysts. In addition, the clinical findings with hematoma and abscess would allow differentiation. Type 1 meningeal cysts may mimic SIH-associated cysts; however, they are usually dorsally located within the spinal canal (15), unlike the ventrally located SIH fluid collections. The clinical and intracranial imaging findings of SIH would allow further differentiation. Arachnoid cysts are typically intradural extramedullary lesions, unlike the extradural cysts in SIH. Neurenteric cysts are also intradural extramedullary in location and may or may not have associated vertebral body anomalies (16).

Conclusion

Our cases support the contention that SIH is associated with spinal extradural fluid collections that most likely represent leakage of CSF. In patients with diffuse intracranial pachymeningeal enhancement, spinal MR imaging may be helpful in suggesting the diagnosis of SIH by identifying such extradural fluid collections. Anatomic localization of the site of CSF leakage with both direct (CT myelography and radionuclide cisternography) and indirect methods (spinal MR imaging) may help guide therapeutic placement of epidural blood patches in patients who do not respond to conservative therapy.

References

1. Schaltenbrand G. **Neure anshaungun zur pathophysiologie der liquorzirkulation.** *Zentrabl Neurochir* 1938;3:290-300
2. Rando T, Fishman R. **Spontaneous intracranial hypotension: report of two cases and review of the literature.** *Neurology* 1992;42:481-487
3. Fishman R, Dillon D. **Dural enhancement and cerebral displacement secondary to intracranial hypotension.** *Neurology* 1993;43:609-611
4. Pannullo S, Reich J, Krol G, Deck M, Posner J. **MRI changes associated with intracranial hypotension and meningeal enhancement on MRI.** *Neurology* 1993;43:919-926
5. Good D, Ghobrial M. **Pathological changes associated with intracranial hypotension and meningeal enhancement on MRI.** *Neurology* 1993;43:2698-2700
6. Mokri B, Parisi J, Scheithauer B, Piepgras D, Miller G. **Meningeal biopsy in intracranial hypotension: meningeal enhancement on MRI.** *Neurology* 1995;45:1801-1807
7. Hochman M, Naidich T, Kobetz S, Fernandez-Maitin A. **Sponta-**

- neous intracranial hypotension with pachymeningeal enhancement on MRI.** *Neurology* 1992;42:1628–1630
8. Sipe J, Zyroff J, Waltz T. **Primary intracranial hypotension and bilateral isodense subdural hematomas.** *Neurology* 1981;31:334–337
 9. Schievink W, Meyer F, Atkinson J, Mokri B. **Spontaneous spinal cerebrospinal fluid leaks and intracranial hypotension.** *J Neurosurg* 1996;84:598–605
 10. Rubin JB, Enzmann DR. **Imaging of spinal CSF pulsation by 2DFT MR.** *AJNR Am J Neuroradiol* 1987;8:297–306
 11. Shaw W, Weinberger E, Brewer D, Geyer J, Berger J, Blaser S. **Spinal subdural enhancement after suboccipital craniectomy.** *AJNR Am J Neuroradiol* 1996;17:1373–1377
 12. Mamourian A, Yarnell T. **Enhancement of pineal cysts on MR images.** *AJNR Am J Neuroradiol* 1991;12:773–774
 13. Fishman R. **Intracranial hypotension (letter).** *Neurology* 1994;44:1981
 14. Benzon H, Nemickas R, Molloy R, Ahmad S, Melen O, Cohen B. **Lumbar and thoracic epidural blood injections for spontaneous intracranial hypotension.** *Anesthesiology* 1996;85:920–922
 15. Nabors M, Pait T, Byrd E, et al. **Updated assessment and current classification of spinal meningeal cysts.** *J Neurosurg* 1988;68:366–377
 16. Geremia G, Russell E, Clasen R. **MR imaging characteristics of a neuroenteric cyst.** *AJNR Am J Neuroradiol* 1988;9:978–980

Please see the Editorial on page 1001 in this issue.