



Get Clarity On Generics

Cost-Effective CT & MRI Contrast Agents



FRESENIUS
KABI

WATCH VIDEO

AJNR

Clinical experience with diffusion-weighted MR in patients with acute stroke.

K O Lövblad, H J Laubach, A E Baird, F Curtin, G Schlaug, R R Edelman and S Warach

AJNR Am J Neuroradiol 1998, 19 (6) 1061-1066

<http://www.ajnr.org/content/19/6/1061>

This information is current as
of August 9, 2025.

Clinical Experience with Diffusion-Weighted MR in Patients with Acute Stroke

Karl-Olof Lövblad, Hans-Joachim Laubach, Alison E. Baird, François Curtin, Gottfried Schlaug, Robert R. Edelman, and Steven Warach

PURPOSE: Our purpose was to evaluate the clinical efficacy, sensitivity, and specificity of echo-planar diffusion-weighted MR imaging in patients with acute infarction.

METHODS: We retrospectively analyzed 194 cases of acute ischemic stroke diagnosed clinically within 24 hours of onset and studied with echo-planar diffusion-weighted MR imaging. Examinations were considered to be positive for infarction when an increase in signal was noted on images acquired at a high b value but absent on images with a low b value. A final clinical diagnosis of acute stroke was used as the standard of reference. A subset of 48 patients scanned within 6 hours was also analyzed.

RESULTS: Diffusion-weighted MR imaging studies were positive in 133 of 151 cases of infarction (88% sensitivity) and negative in 41 of 43 cases with no infarction (95% specificity). Two cases identified as positive on diffusion-weighted images had nonischemic diagnoses (1.5% false-positive rate). Diffusion-weighted imaging had a positive predictive value of 98.5% and a negative predictive value of 69.5%. Use of T2-weighted sequences as well as diffusion-weighted imaging produced no false-positive findings. Of the negative scans, 69.5% corresponded to transient ischemic attacks or infarcts (mostly small brain stem infarcts). When only cases scanned within 6 hours of onset were considered, the sensitivity rose to 94% and the specificity to 100%.

CONCLUSION: Despite bias due to dependence between diffusion-weighted imaging and the final diagnosis, this analysis suggests high sensitivity and specificity for echo-planar diffusion-weighted imaging in the diagnosis of acute cerebral infarction, although negative scans did not rule out an ischemic pathogenesis.

Conventional MR images may not show positive findings in cases of ischemic infarction for 8 to 12 hours after onset (1, 2), a time period beyond that when neuroprotective drugs are most likely to be given and more likely to be effective (3–7). Diffusion-

weighted MR images, on the other hand, can show regions of ischemic injury within minutes after stroke onset (8–10). Studies of diffusion-weighted imaging in humans suffering acute stroke have confirmed the diagnostic capability and superiority of this technique relative to T2-weighted imaging within the first few hours after stroke onset (11–16). The area of acute ischemic infarction becomes hyperintense (bright) on early diffusion-weighted images because of the shift of water from extracellular to intracellular compartments in the formation of cytotoxic edema that results from failure of sodium potassium ATPase function caused by a net drop in the apparent diffusion coefficient (ADC) of water. Since diffusion-weighted imaging in itself is a highly motion-sensitive technique, it was at first difficult to implement in the clinical setting. Moreover, the first studies performed on clinical scanners only permitted acquisition of a single section. The advent of echo-planar imaging, with its higher gradients and shorter imaging times (individual images obtained on the order of 100 milliseconds), allows acquisition of whole-brain scans in a matter of seconds and effectively eliminates bulk mo-

Received September 23, 1997; accepted after revision December 8.

Dr. Lövblad was supported by a grant from the Schweizerischer Nationalfonds zur Förderung der wissenschaftlichen Forschung (grant 81 BE-42645); Alison Baird was supported by the Neil Hamilton Fairley Fellowship of the NHMRC of Australia and the Bushell Fellowship of the RACP. The work was also supported by grants from NINDS, AHA, Harcourt General Charitable Foundation, and the Friends of Beth Israel Hospital.

Presented at the annual meeting of the American Society of Neuroradiology, Seattle, June 1996.

From the Departments of Radiology (K-O.L., H-J.L., R.R.E.) and Neurology (A.E.B., G.S., S.W.), Beth Israel Deaconess Medical Center, Harvard Medical School, Boston, Mass; and the Department of Medical Statistics, University Hospital of Geneva, Switzerland (F.C.).

Address reprint requests to Karl-Olof Lövblad, MD, Department of Neuroradiology, IDR, Inselspital, Freiburgstrasse, CH-3010 Bern, Switzerland.

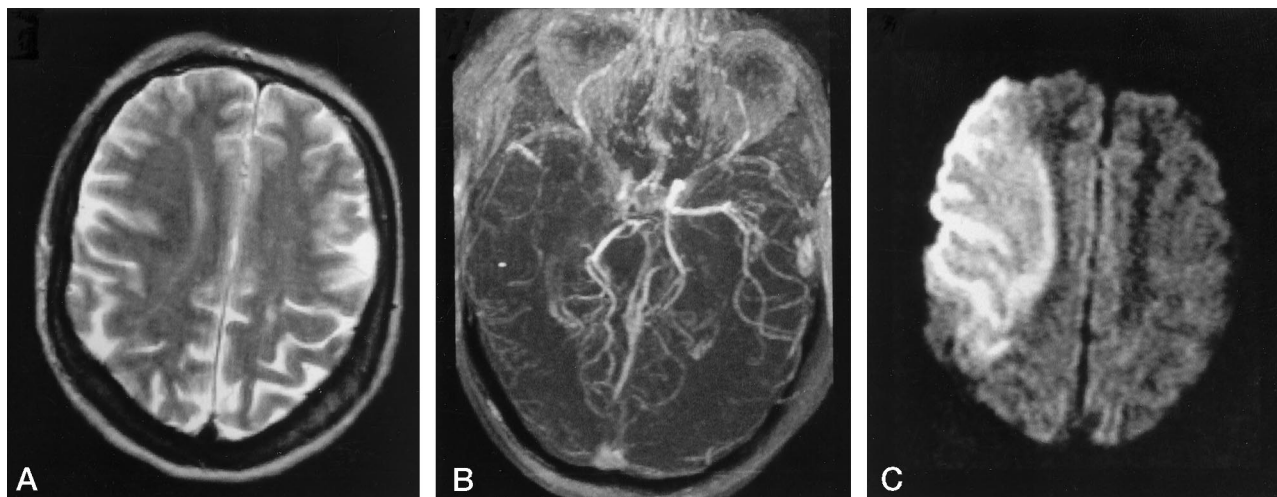


FIG 1. 67-year-old man examined 16 hours after onset of symptoms.

T2-weighted image (A) is negative; MR angiogram (B) shows complete occlusion of the right middle cerebral artery (MCA). Echo-planar diffusion-weighted image (C) at the maximum b value shows an extensive MCA infarction on the right.

tion artifacts caused by head movement or by physiological motion, such as CSF flow and brain pulsation, making diffusion-weighted imaging applicable to any stroke patient who has no contraindication to MR imaging (12).

As scanners capable of performing echo-planar diffusion-weighted imaging are now becoming widely available commercially for routine clinical use, it is important to define the sensitivity, specificity, and predictive value of diffusion-weighted imaging in the diagnosis of ischemic stroke so that the technique may be applied and interpreted correctly. Therefore, the aim of this study was to evaluate both the sensitivity and specificity of echo-planar diffusion-weighted MR imaging in the examination of patients with suspected acute cerebral ischemia.

Methods

Our study group consisted of 194 patients (94 men and 100 women, 20 to 99 years old) in whom probable or definite acute ischemic stroke had been diagnosed clinically within 24 hours after onset and who were examined with diffusion-weighted MR imaging. Patients with nonfocal or nonspecific neurologic changes were not included in this analysis, nor were patients with worsening or chronic deficits. In all cases, the final clinical diagnosis was taken from the patients' medical records, and it was used as the standard of reference. This diagnosis was based on clinical assessment and neuroimaging without attempt to blind the neurologist from the results of the diffusion-weighted imaging studies. All patients were scanned within 24 hours of onset of signs and symptoms, defined as the time the patient was last known to be well. A diffusion-weighted image positive for stroke was considered to be one on which hyperintensity appeared in a clinically relevant region. An otherwise abnormal diffusion-weighted image, such as one with an obvious region of hypointensity, which is expected in acute hemorrhage (17, 18), was not considered positive for ischemic stroke.

The first 44 patients were examined on a prototype whole-body 1.5-T system capable of echo-planar imaging. On the prototype whole-body 1.5-T echo-planar imaging system, diffusion imaging was done using a multisection, single-shot, spin-echo, echo-planar imaging sequence. Typical sequence parameters were TE = 100, matrix size = 128×128 , field of view

(FOV) = 250×250 , section thickness = 7 mm, with no gap between sections. The diffusion gradient was applied in the transverse (section-select) direction. Diffusion gradient strength varied from 0 to 30 mT/m by increments of 5 mT/m, resulting in seven b values ranging from 0 to 1271 s/mm². Total acquisition time for all seven diffusion sensitivities was 48 seconds. For technical reasons, some of the measurements had results from fewer than seven b values. The remaining studies ($n = 150$) were performed on a different 1.5-T echo-planar imaging system. For diffusion-weighted imaging on this system, we used only two b values (0 and 1000 s/mm²). Typical imaging parameters were TE = 118, matrix size = 128×128 , FOV = 260×260 , section thickness = 7 mm, with no gap between the 20 sections covering the whole brain.

The MR diffusion sequence at $b = 1000$ was run three times, with diffusion gradients applied in each of the x , y , and z directions. To minimize the effects of diffusion anisotropy, an average of all three diffusion directions was calculated to give the trace of the diffusion tensor. No special head restraints were used apart from the standard padding. No cardiac or respiratory gating was used. In emergency practice, ADC values were not calculated. The sensitivity and specificity of the diagnostic test by diffusion-weighted imaging versus the standard diagnosis was assessed by cross tabulation. The 95% confidence intervals (95% CI) were calculated.

Results

Diffusion-weighted images were positive in 133 of 151 cases of infarction (88% sensitivity; 95% CI: 83% to 93%) and negative in 41 of 43 cases without infarction (95% specificity; 95% CI: 92% to 98%). Diffusion-weighted imaging had a positive predictive value of 98.5% (95% CI: 97% to 100%) and a negative predictive value of 69.5% (95% CI: 63% to 76%). Relative hyperintensities on diffusion-weighted images were observed in clinically relevant brain regions in 135 (70%) of 194 cases (Figs 1–4). Of these, two cases had nonischemic diagnoses (1.5% false-positive rate). One false-positive finding was a cerebral abscess, the other was a brain tumor (Fig 5), which presented as a seizure followed by a prolonged postictal hemiparesis. Of the 59 negative cases, 23 had a final diagnosis of transient ischemic attack (TIA), 18

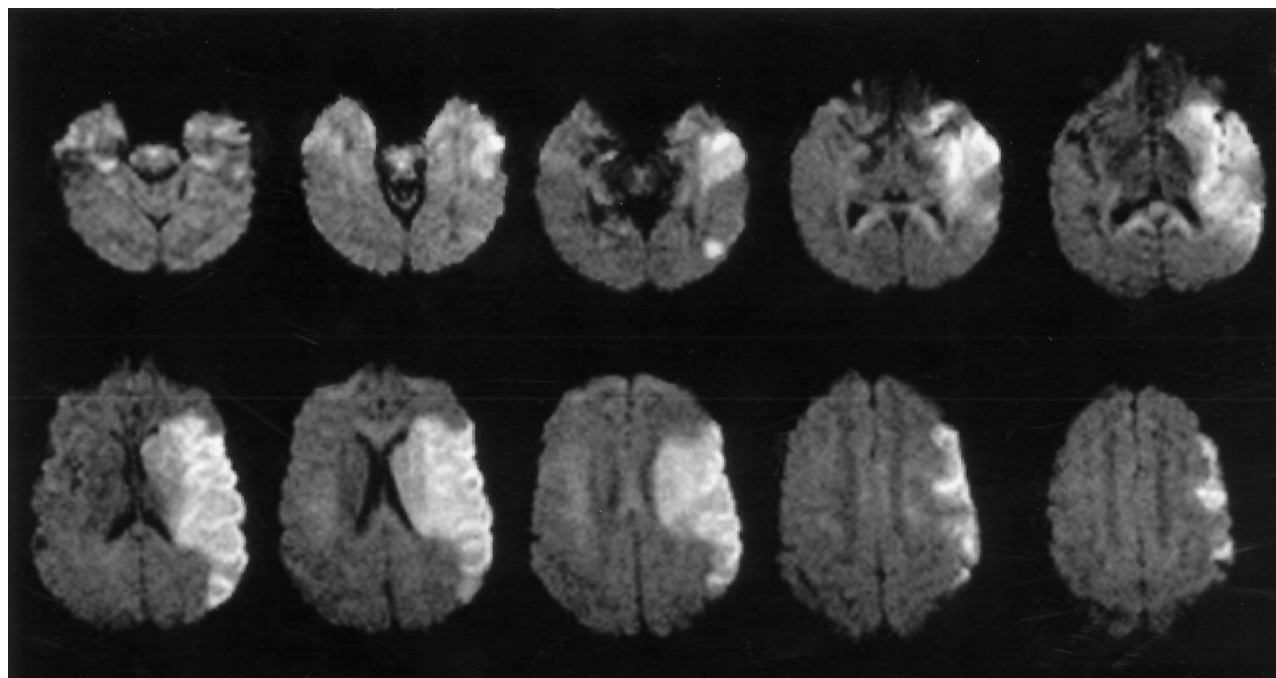


FIG 2. Large acute left MCA occlusion shown as an area of hyperintensity on a diffusion-weighted image obtained at a high b value.

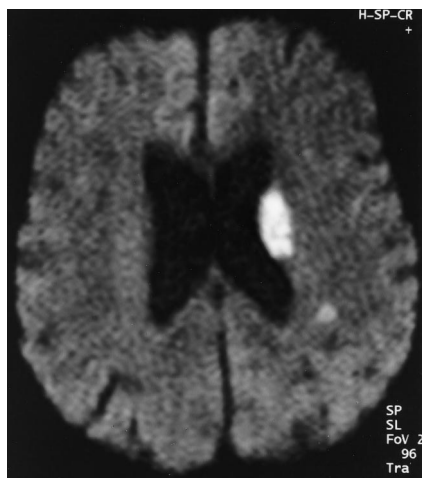


FIG 3. 75-year-old patient with acute neurologic symptoms 19 hours after onset of symptoms. Diffusion-weighted image at a maximum b value shows an area of hyperintensity in the paraventricular left internal capsule.

had a final diagnosis of stroke, two were classified as peripheral vertigo, two were migrainous events, two were seizures, nine were intracerebral hemorrhages (Fig 6), two were dementia, and one was a factitious disorder. The cases with no hyperintense lesion on diffusion-weighted images also had no hyperintense lesion diagnostic of stroke on T2-weighted or proton density-weighted images. Of the 18 patients who had negative diffusion-weighted images and in whom the final diagnosis was stroke, most had nondisabling or resolving deficits suggestive of small infarcts with a localization in the brain stem. One patient with a negative diffusion-weighted image and stroke had fluctuating signs and symptoms localized to the territory of the left posterior cerebral artery (during the

course of his admission, progressive and fixed deficits developed, evolving to occlusion of the left posterior cerebral artery with characteristic lesions found on follow-up diffusion-weighted and T2-weighted images).

When patients scanned within 6 hours of symptom onset were considered, we had a total of 48 cases. Eight of these patients had typical hematomas with an area of central signal loss, and eight patients had normal scans; the remaining 32 scans were found to contain hyperintensities corresponding to a stroke. In the acute phase, diffusion-weighted imaging was therefore positive in 32 of 34 cases of infarction (94% sensitivity) and negative in 14 of 14 cases in which there was not a final diagnosis of stroke (100% specificity).

Discussion

In this analysis, diffusion-weighted imaging showed a high sensitivity, specificity, and positive predictive value in the diagnosis of ischemic stroke. The negative predictive value was only moderate at 69.5%, and a final diagnosis of TIA or stroke was made in (coincidentally) 69.5% of the cases. Thus, a negative diffusion-weighted imaging study did not rule out a diagnosis of stroke or ischemia. Most of the false-negative findings of stroke were in patients who seemed to have lesions that were beyond the spatial resolution of the scanner (minor or resolving deficits clinically localized to the brain stem). Note that patients were selected for inclusion if they had a high prior probability of an ischemic stroke on the basis of clinical criteria, and that, owing to spectrum bias, the values would likely be different in a random sample of patients with neurologic disorders (19). However, the present analysis more closely approximates how the test will be used in clinical practice to assess patients

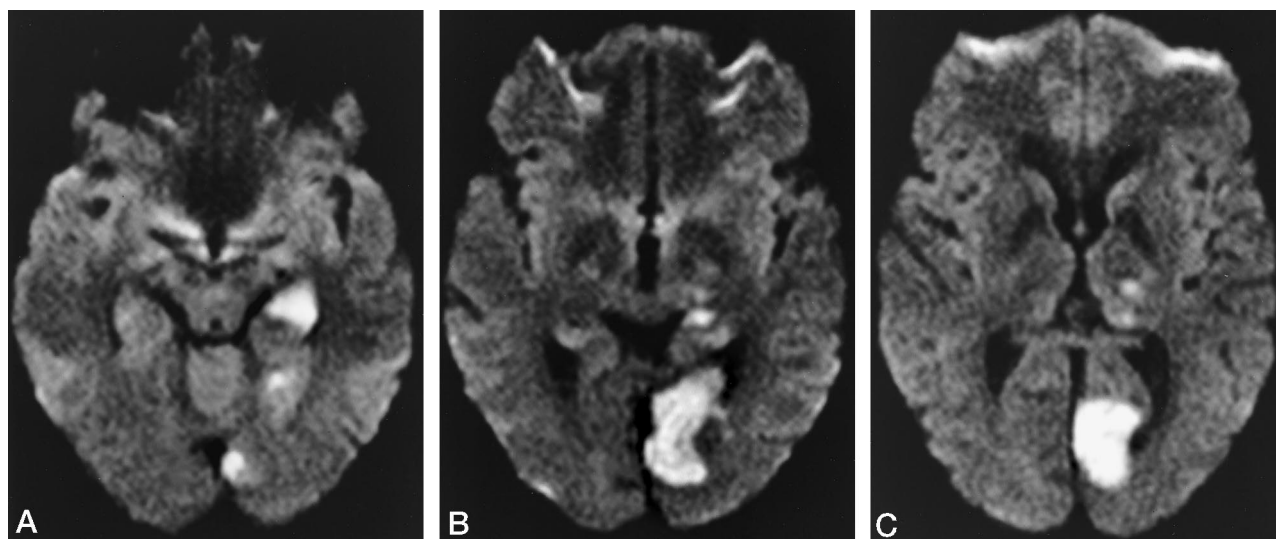


FIG 4. 27-year-old woman with a right-sided hemianopia and right-sided hypoesthesia.

Diffusion-weighted images show the presence of hyperintense ischemic changes in the medial temporal lobe (A), the occipital lobe (B), and the left thalamus (C).

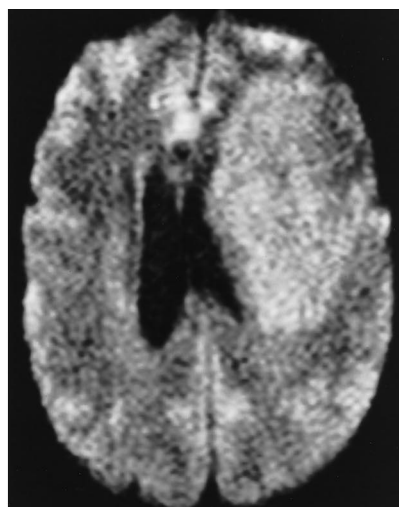


FIG 5. 54-year-old man with right-sided hemiparesis. Diffusion-weighted image shows a right-sided hyperintensity in the area corresponding to the MCA; however, this proved to be a brain tumor and represents a false-positive finding.

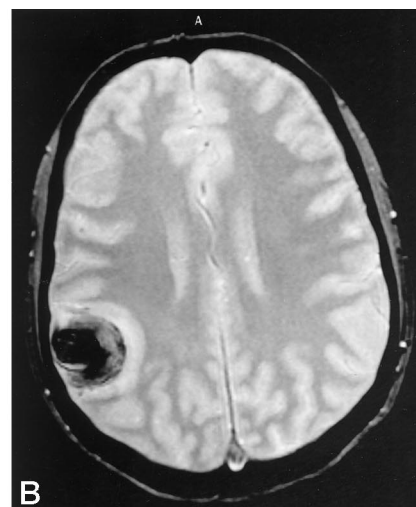
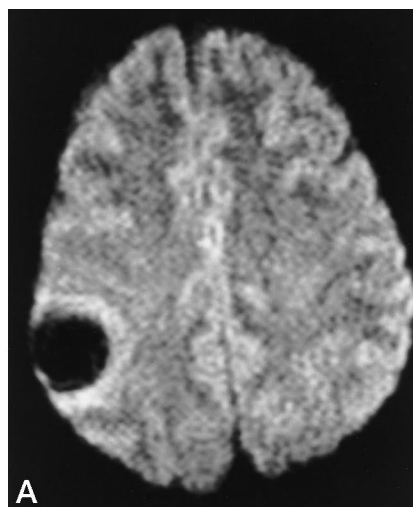


FIG 6. 29-year-old woman with left-sided weakness.

Diffusion-weighted image (A) shows a right-sided round area with signal loss, corresponding to the hematoma seen on the susceptibility-weighted T2-weighted fast low-angle shot image (B).

with signs and symptoms suggestive of acute stroke. As diffusion-weighted imaging is part of the diagnostic process, a positive diffusion-weighted study is likely to increase the probability of a positive diagnosis, just as a negative diffusion-weighted study is likely to increase the probability of a negative diagnosis. This leads to an increase in the sensitivity and specificity of diffusion-weighted imaging; however, in the absence of a real reference standard for the diagnosis of stroke, such a bias is difficult to avoid.

Because no effort was made to blind the clinicians to the diffusion-weighted imaging results or the radiologist to the clinical information, the clinical diagnosis and interpretation of the scan results may have been biased by the other information. Despite the

potential for bias, 30% of the patients with negative diffusion-weighted imaging studies (and negative T2-weighted studies) were nonetheless considered to have stroke, suggesting that the final diagnoses were not unduly influenced by the scan results. In this study, we considered a positive finding to be the presence of an area of hyperintensity on the diffusion-weighted image acquired at a maximal b value; therefore, we considered the hematomas as negative findings, even if they did contain a positive finding of signal loss. On the other hand, the two nonischemic lesions that were hyperintense were considered to be positive findings radiologically.

Strokes with negative findings on conventional T2-weighted images have been reported previously

(1, 20) and tended to occur in small vessels and/or the brain stem. Bryan et al (1) reported that in the sub-acute stage, by which time both T2-weighted images and CT scans should show infarcts, sensitivity for lesion detection is 88%, a number similar to our reported sensitivity for diffusion-weighted imaging in the acute stage. Since diffusion-weighted studies can depict lesions within minutes after onset, whereas T2-weighted images may not show positive findings until 8 to 12 hours after onset (2), the sensitivities between these two studies should in principle be equivalent. The recent demonstration of the effectiveness of tissue plasminogen activator and the development of potentially successful neuroprotective drugs in the treatment of ischemic stroke have created a need for more accurate early diagnosis (3–7). CT of the brain, which has long been considered useful in cases in which it is necessary to exclude subarachnoid hemorrhage or intracerebral hematomas, has traditionally been considered insensitive in depicting positive evidence of ischemic injury within the first several hours after symptom onset. Although careful and painstaking evaluation of CT scans can improve the diagnostic yield very early on (21, 22), great expertise and extensive experience are required to detect subtle signs of tissue damage, such as lower CT attenuation values, denoting edema, or dense cerebral arteries, indicating acute thrombosis. By comparison, on diffusion-weighted images, the hyperintensities due to acute ischemic injury are of striking contrast and require little sophisticated training or judgment to identify with certainty. Indeed, the technique has been likened to a possible ECG for the diagnosis of acute stroke: the light-bulb effect of areas of restricted diffusion being almost diagnostic of stroke (23). Nuclear medicine techniques, such as single-photon emission CT or positron emission tomography, have been able to show changes in local blood flow and metabolism, but these changes are not to be considered direct markers of neuronal damage and the techniques are invasive, require the administration of radioactive tracers, and are not readily available clinically at most sites (24–26). Conventional MR imaging, especially T2-weighted sequences, is known to be sensitive to tissue edema, but has a high rate of false-negative results in the first 24 hours after an event (1, 2). MR scanners with higher fields (1.5 T) in combination with gradient-echo susceptibility-weighted techniques can now detect signs of acute intracerebral hemorrhage (17) when a strongly susceptibility-weighted sequence is used. Echo-planar diffusion-weighted imaging has also recently been shown to be sensitive to hemorrhage (18). This combination could render CT obsolete in the setting of acute stroke, since MR imaging could be used to detect both ischemia and hematomas, an advantage of considerable benefit in the era of cost-effective medicine. The time required to scan a patient with both a susceptibility-weighted pulse sequence and a diffusion-weighted echo-planar sequence is equivalent to the time it takes to perform

a head CT scan, providing more diagnostic information in the same amount of time.

A recent report (27) has shown that diffusion-weighted imaging might have a role in establishing the origin of infarction in the acute phase; indeed, this technique can, in selected cases, show multiple small areas of infarction that are more likely to be of embolic than thrombotic origin, information that may be helpful in the acute work-up of patients and in planning therapy. Our analysis shows a high sensitivity and specificity for echo-planar diffusion-weighted imaging in the diagnosis of acute cerebral infarction. True-negative findings were either TIAs or nonischemic events; false-negative findings could be explained by symptomatic hypoperfusion or small strokes below the spatial resolution of the technique as well as by small brain stem strokes. Although we found no significant difference in the detection of stroke with diffusion-weighted imaging as compared with data sets of images acquired with both systems, diffusion-weighted imaging performed with the gradients applied in three directions allowed us to rule out the effects of anisotropy by reconstructing trace images (28); it was then possible to detect small lesions that might be hidden, for instance, in the internal capsule. Calculating the ADC (29), which allows more precise determination of the age of an infarct, is also of potential use. Until recently, this measurement could only be made retrospectively and did not have an impact on patient management, which is why it was not performed in this study. However, the development of software that allows rapid calculation of ADC on the imaging console should make this assessment possible in the near future. Determination of the ADC would also make possible the fast detection of false-positive findings, such as those found in our series. Diffusion-weighted imaging itself can also help to differentiate cytotoxic from vasogenic edema (30).

Conclusion

Our results require confirmation using a prospective, blinded experimental design, but they argue for the diagnostic utility of diffusion-weighted MR imaging, a technique that appears to be a powerful new tool in the diagnosis (31, 32), management, and eventual follow-up (33) of patients with clinical signs compatible with acute stroke. Our results are even stronger when we include patients scanned within the first 6 hours of symptom onset, with a specificity of 100% and a sensitivity of 94%. This result is of special interest when considering neuroprotective treatment for these patients. Moreover, mounting evidence, also acquired with diffusion-weighted imaging (34), suggests that ischemic lesions might continue to grow beyond this strict time frame of 6 hours, making intervention desirable, in some cases, as late as 24 hours after onset of symptoms. The increasing availability of echo-planar scanners, as well of newer diffusion-weighted imaging sequences that can run on conventional low-field scanners (35), should make

this technique available in most hospitals that have an MR scanner, not just in a few select research centers.

References

1. Bryan RN, Levy LM, Whitlow WD, Killian JM, Preziosi TJ, Rosario JA. **Diagnosis of acute cerebral infarction: comparison of CT and MR imaging.** *AJNR Am J Neuroradiol* 1991;12:611–620
2. Yuh WT, Crain MR, Loes DJ, Greene GM, Ryals TJ, Sato Y. **MR imaging of cerebral ischemia: findings in the first 24 hours.** *AJNR Am J Neuroradiol* 1991;12:621–629
3. Siesjö BK. **Pathophysiology and treatment of focal cerebral ischemia, I: pathophysiology.** *J Neurosurg* 1992;77:169–184
4. Siesjö BK. **Pathophysiology and treatment of focal cerebral ischemia, II: mechanisms of damage and treatment.** *J Neurosurg* 1992;77:337–354
5. Fisher M, Bogousslavsky J. **Evolving toward effective therapy for acute ischemic stroke.** *JAMA* 1993;270:360–364
6. The NINDS rt-PA stroke study group. **Tissue plasminogen activator for acute ischemic stroke.** *N Engl J Med* 1995;333:1581–1587
7. Minematsu K, Fisher M, Li L, et al. **Effects of a novel NMDA antagonist on experimental stroke rapidly and quantitatively assessed by diffusion-weighted MRI.** *Neurology* 1993;43:397–403
8. Le Bihan D, Breton E, Lallemand D, Grenier P, Cabanis E, Laval-Jeantet M. **MR Imaging of intravoxel incoherent motions: application to diffusion and perfusion in neurologic disorders.** *Radiology* 1986;161:401–407
9. Moseley ME, Cohen Y, Mintorovitch J, et al. **Early detection of regional cerebral ischemia in cats: comparison of diffusion- and T2-weighted MRI and spectroscopy.** *Magn Reson Med* 1990;14:330–346
10. van Gelderen P, de Vleeschouwer MHM, DesPres D, Pekar J, van Zijl PCM, Moonen CTW. **Water diffusion and acute stroke.** *Magn Reson Med* 1994;31:154–163
11. Warach S, Chien D, Li W, Ronthal M, Edelman RR. **Fast magnetic resonance diffusion-weighted imaging of acute stroke.** *Neurology* 1992;42:1717–1723
12. Warach S, Gaa J, Siewert B, Wielopolski P, Edelman RR. **Acute human stroke studies by whole brain echo planar diffusion-weighted magnetic resonance imaging.** *Ann Neurol* 1995;37:231–241
13. Sorensen AG, Buonanno FS, Gonzalez RG, et al. **Hyperacute stroke: evaluation with combined multisection diffusion-weighted and hemodynamically-weighted echo-planar MR imaging.** *Radiology* 1996;199:391–401
14. Marks MP, De Crespigny A, Lentz D, Enzmann DR, Albers GW, Moseley ME. **Acute and chronic stroke: navigated spin-echo diffusion-weighted MR imaging.** *Radiology* 1996;199:403–408
15. Warach SJ, Dashe JF, Edelman RR. **Clinical outcome in ischemic stroke predicted by early diffusion-weighted and perfusion magnetic resonance imaging: a preliminary analysis.** *J Cereb Blood Flow Metab* 1996;16:53–59
16. Chien D, Kwong KK, Gress DR, Buonanno FS, Buxton RB, Rosen BR. **MR Diffusion imaging of cerebral infarction in humans.** *AJNR Am J Neuroradiol* 1992;13:1097–1102
17. Patel MR, Edelman RR, Warach S. **Detection of hyperacute primary intraparenchymal hemorrhage by magnetic resonance imaging.** *Stroke* 1996;27:2321–2324
18. Ebisu T, Tanaka C, Umeda M, Kitamura M, et al. **Hemorrhagic and nonhemorrhagic stroke: diagnosis with diffusion-weighted and T2-weighted echo-planar MR imaging.** *Radiology* 1997;203:823–828
19. Ransohoff DF, Feinstein AR. **Problems of spectrum and bias in evaluating the efficacy of diagnostic tests.** *N Engl J Med* 1978;299:926–930
20. Alberts MJ, Faulstich ME, Gray L. **Stroke with negative brain magnetic resonance imaging.** *Stroke* 1992;23:663–667
21. von Kummer R, Holle R, Gzryska U, et al. **Interobserver agreement in assessing CT signs of middle cerebral artery infarction.** *AJNR Am J Neuroradiol* 1996;17:1743–1748
22. Lövblad KO, Ozdoba C, Remonda L, Schroth G. **Computed tomography attenuation values in acute basilar occlusion.** *Cerebrovasc Dis* 1994;4:407–411
23. Koroshetz WJ, Gonzalez G. **Diffusion-weighted MRI: an ECG for "brain attack"?** *Ann Neurol* 1997;41:565–566
24. Marchal G, Serrati C, Rioux P, et al. **PET imaging of cerebral perfusion and oxygen consumption in acute ischaemic stroke: relation to outcome.** *Lancet* 1993;341:925–927
25. Davis SM, Chua MG, Lichtenstein M, Rossiter SC, Binns D, Hopper JL. **Cerebral hypoperfusion in stroke prognosis and brain recovery.** *Stroke* 1993;24:1691–1696
26. Baird AE, Austin MC, McKay WG, Donnan GA. **Sensitivity and specificity of 99mTc-HMPAO SPECT cerebral perfusion measurements during the first 48 hours for the localization of cerebral infarction.** *Stroke* 1997;28:976–980
27. Gass A, Hennerici MG, Gaa J, Schwartz A. **Rapid recovery from left hemiplegia.** *Lancet* 1997;349:772
28. Warach S, Boska M, Welch KMA. **Pitfalls and potential of clinical diffusion-weighted MR imaging in acute stroke.** *Stroke* 1997;28:481–482
29. Schlaug G, Siewert B, Benfield A, Edelman RR, Warach S. **Time course of the apparent diffusion coefficient (ADC) abnormality in human stroke.** *Neurology* 1997;49:113–119
30. Schaefer PW, Buonanno FS, Gonzalez RG, Schwamm LH. **Diffusion-weighted imaging discriminates between cytotoxic and vasogenic edema in a patient with eclampsia.** *Stroke* 1997;28:1082–1085
31. Lutsep HL, Albers GW, DeCrespigny A, Kamat GN, Marks MP, Moseley ME. **Clinical utility of diffusion-weighted magnetic resonance imaging in the assessment of ischemic stroke.** *Ann Neurol* 1997;41:574–580
32. Lövblad KO, Baird AE, Schlaug G, et al. **Ischemic lesion volumes in acute stroke by diffusion-weighted magnetic resonance imaging correlate with clinical outcome.** *Ann Neurol* 1997;42:164–170
33. Baird AE, Benfield A, Schlaug G, et al. **Enlargement of human cerebral ischemic lesion volumes measured by diffusion-weighted magnetic resonance imaging.** *Ann Neurol* 1997;41:581–589
34. Baron JC, von Kummer R, del Zoppo GJ. **Treatment of acute ischemic stroke: challenging the concept of a rigid and universal time window.** *Stroke* 1995;26:2219–2221
35. Jakob PM, Chen Q, Lövblad KO, Griswold M, Warach S, Edelman RR. **Single-shot diffusion weighted imaging of the brain with HASTE.** In: Oudkerk M, Edelman RR, eds. *Advances in MRI. II: High-Power Gradient MR-Imaging.* Berlin: Blackwell Science; 1997:177–181

Please see the Editorial on page 1003 in this issue.