



Get Clarity On Generics

Cost-Effective CT & MRI Contrast Agents



FRESENIUS
KABI

WATCH VIDEO

AJNR

Chemical analysis of an epidermoid cyst with unusual CT and MR characteristics.

F A Timmer, M Sluzewski, M Treskes, W J van Rooij, J L Teepen and D Wijnalda

AJNR Am J Neuroradiol 1998, 19 (6) 1111-1112

<http://www.ajnr.org/content/19/6/1111>

This information is current as
of August 8, 2025.

Chemical Analysis of an Epidermoid Cyst with Unusual CT and MR Characteristics

F. A. Timmer, M. Sluzewski, M. Treskes, W. J. J. van Rooij, J. L. J. M. Teepe, and D. Wijnalda

Summary: Chemical analysis of the contents of a so-called bright epidermoid of the posterior fossa with unusual CT and MR imaging characteristics suggested that a combination of high protein content and high viscosity were responsible for the atypical imaging findings.

Epidermoid tumors are rare congenital lesions of the brain that account for 0.2% to 1% of all intracranial neoplasms (1). We report a case of an epidermoid tumor with an unusually dense appearance on CT scans, high signal intensity on T1-weighted MR images, and low signal intensity on T2-weighted MR images. The results of pathologic examination and chemical analysis of the contents of the cyst are discussed.

Case Report

A 47-year-old woman had a 10-year history of bilateral facial nerve paresis, deafness, and tongue atrophy. More recently, the symptoms had worsened and she reported difficulty swallowing. CT scans showed a dense mass in the posterior fossa of the left cerebellar hemisphere (Fig 1A). At MR imaging, the lesion showed high signal intensity on T1-weighted sequences and low signal intensity on T2-weighted sequences (Fig 1B and C). A small nodule was present at the periphery of the lesion. No enhancement was seen after administration of gadopentetate dimeglumine. On both the CT and MR studies, an arachnoid cyst was seen on the right side of the posterior fossa. The epidermoid showed mass effect on the brain stem. There was no hydrocephalus.

At surgery, a dark brown cyst with highly viscous, toffee-like contents was found and removed. The arachnoid cyst was also evacuated. At pathologic examination, the cystic wall was composed of fibrous tissue lined with stratified squamous epithelium, consistent with the diagnosis of epidermoid. The cystic wall was partly disintegrated by chronic inflammation, with foreign-body reaction and reactive fibrous proliferation. This proliferation corresponded to the peripheral nodule seen at MR imaging.

Chemical analysis of the cystic fluid was performed after 10- and 100-fold dilution with purified water using chemical analyzers SMA-C and Axon (Technicon/Bayer, Tarrytown, NY). Protein electrophoresis was done, and calcium, iron, copper, nickel, and manganese were measured by atom absorption spectrophotometry. The results were as follows: total protein, 210 g/L; albumin, 140 g/L; cholesterol, 8.7 mmol/L; triglycer-

ides, 4.7 mmol/L; calcium, 150 mg/kg; iron, 26 mg/kg; copper, 3 mg/kg; nickel, < 0.5 mg/kg; and manganese, < 0.2 mg/kg. The protein electrophoresis showed a main band of albumin and diffuse staining in the α and β regions. Microscopic analysis showed debris with no cholesterol crystals.

Discussion

Epidermoids are benign, congenital, developmental tumors, usually located in the sellar and suprasellar regions, the middle fossa, and off the midline in the posterior fossa. The cysts are thin-walled and lined by stratified squamous epithelium. Cystic contents usually include debris, keratin, water, and cholesterol (2). On CT scans, most epidermoids are hypodense and do not enhance with contrast material. On short repetition time/echo time (TR/TE) MR sequences, epidermoid tumors typically show mild hypointensity, usually between that of CSF and brain parenchyma. On long TR/TE sequences, these tumors show hyperintensity, similar to or greater than that of CSF.

The uncommonly dense appearance of some epidermoids at CT together with unusual MR characteristics has been reported. In 1977, Braun et al (3) described an intracranial epidermoid that appeared dense on CT scans. Diffuse calcification and saponification of the debris were thought to explain the high attenuation values. Nagashima et al (4) found a high total protein concentration of the cystic fluid in a similar case. They attributed the dense aspect of the epidermoid to the combination of diffuse calcification and a high protein content. The moderately high signal intensity seen on T1-weighted images was thought to be explained by a high lipid content, calcification, fibrosis, and paramagnetic effects (5, 6).

In view of the chemical analysis of the fluid contained in the epidermoid cyst reported here, we strongly believe that both the CT and MR imaging appearance may be explained by the high total protein concentration and the large fraction (67%) of albumin. The concentrations of calcium and iron in the fluid were too low to account for the high density on CT scans, whereas a high protein content alone

Received July 1, 1997; accepted after revision September 15.

From the Departments of Radiology (F.A.T., M.S., W.J.J.v.R.), Pathology (J.L.J.M.T.), and Neurosurgery (D.W.), St Elisabeth Hospital, Tilburg; and the Department of Clinical Chemistry, OLVG (M.T.), Amsterdam, the Netherlands.

Address reprint requests to M. Sluzewski, MD, PhD, Department of Radiology, St Elisabeth Hospital, PO Box 90151, 5000 LC Tilburg, the Netherlands.

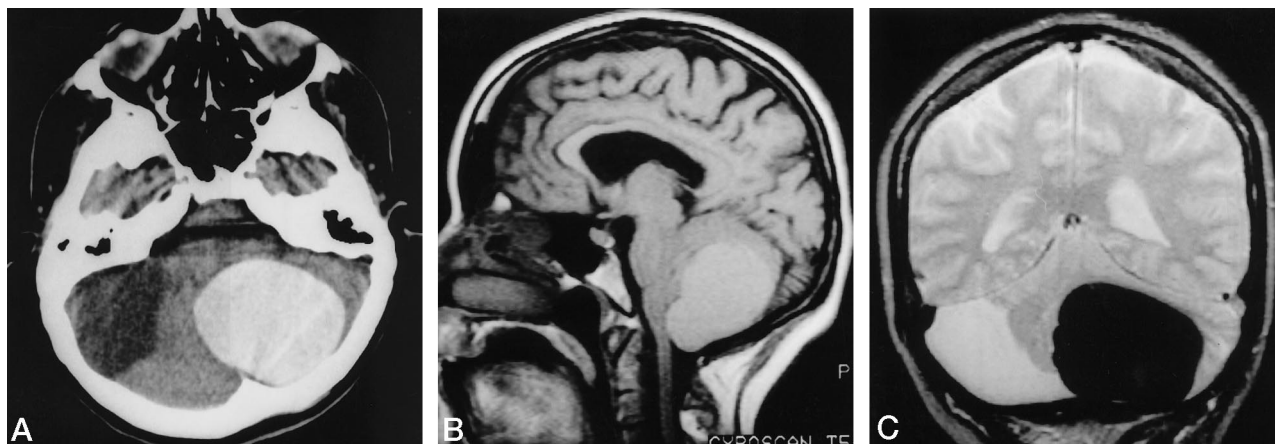


FIG 1. 47-year-old woman with epidermoid cyst.

A, Noncontrast CT scan shows a dense left-sided cerebellar mass.

B, Noncontrast sagittal T1-weighted MR image (392/11/2) shows the mass to be slightly hyperintense.

C, Coronal T2-weighted MR image (2200/90/1) shows the tumor on the left side of the posterior fossa to have very low signal intensity. The arachnoid cyst on the right side has a signal intensity similar to that of CSF.

may result in a high attenuation value (7). Also, the amount of cholesterol and triglycerides was too low to explain a significant increase in signal intensity on T1-weighted images. The amount of cholesterol and triglycerides was similar to the values found by Ahmadi et al (8) in their investigation of cystic fluid in patients with craniopharyngiomas. These authors found no relation between signal intensity on T1-weighted images and the concentration of cholesterol and triglycerides; however, high concentrations of protein (> 90 mg/L) seemed responsible for an increase in signal intensity. The low signal intensity on T2-weighted images may be explained by the high viscosity of the fluid, similar to that described in chronically inspissated sinonasal secretions (9).

Conclusion

The dense appearance on CT and the unusual MR characteristics of the so-called bright epidermoid cyst seen in our patient may be explained by a combination of very high protein concentration and high viscosity.

References

1. Davidson HD, Ouchi T, Steiner RE. **NMR imaging of congenital intracranial germinal layer neoplasms.** *Neuroradiology* 1985;27:301-303
2. Gualdi GF, Di Biasi C, Trasimeni G, Pingi A. **Unusual MR and CT appearance of an epidermoid tumor.** *AJNR Am J Neuroradiol* 1991;12:771-772
3. Braun IF, Naidich TP, Leeds NE, Koslow M, Zimmerman HM, Chase NE. **Dense intracranial epidermoid tumors.** *Radiology* 1977;122:717-719
4. Nagashima C, Takahama M, Sakaguchi A. **Dense cerebellopontine epidermoid cyst.** *Surg Neurol* 1982;17:172-177
5. Newton DR, Larson TC, Dillon WP, Newton TH. **Magnetic resonance characteristics of cranial epidermoids and teratomatous tumors (abstr).** *AJNR Am J Neuroradiol* 1987;8:945
6. Rooney MS, Poon PY, Vortzman G. **Magnetic resonance imaging of intracranial epidermoids: report of two cases.** *J Can Assoc Radiol* 1987;38:283-287
7. New P, Aronow S. **Attenuation measurements of whole blood and blood fractions in computed tomography.** *Radiology* 1976;121:635-640
8. Ahmadi J, Destian S, Apuzzo MLJ, Segall HD, Zee C. **Cystic fluid in craniopharyngiomas: MR imaging and quantitative analysis.** *Radiology* 1992;182:783-785
9. Dillon WP, Som PM, Fullerton GD. **Hypointense MR signal in chronically inspissated sinonasal secretions.** *Radiology* 1990;174:73-78