



**Benign fibrous histiocytoma of the nasal cavity in a newborn: MR and CT findings.**

D A Shrier, A R Wang, U Patel, A Monajati, P Chess and Y Numaguchi

*AJNR Am J Neuroradiol* 1998, 19 (6) 1166-1168  
<http://www.ajnr.org/content/19/6/1166>

This information is current as of July 3, 2025.

# Benign Fibrous Histiocytoma of the Nasal Cavity in a Newborn: MR and CT Findings

David A. Shrier, Alun R. Wang, Uresh Patel, Ahmad Monajati, Patricia Chess, and Yuji Numaguchi

**Summary:** Benign fibrous histiocytoma of the nasal cavity in a newborn is rare, and the MR imaging appearance of this entity has not been reported. We present the MR and CT findings in such a case and review the differential diagnosis for intranasal masses in the neonate.

Congenital intranasal mass lesions represent one subtype of several possible causes of respiratory distress in a newborn (1). These are most commonly due to nasoethmoidal encephaloceles, nasal gliomas, dermoid/epidermoid tumors, hemangiomas, and lymphangiomas (2–4). Benign fibrous histiocytoma of the nasal cavity is a rare cause of neonatal respiratory distress; only two cases have been reported in the literature (1, 2). To our knowledge, the MR imaging appearance of this entity has not been described. We report a case of benign fibrous histiocytoma presenting as neonatal respiratory distress in which the MR appearance of the lesion mimics nasal glioma.

## Case Report

After an uncomplicated pregnancy and a gestation period of almost 40 weeks, a 3560-g infant was born via normal, spontaneous vaginal delivery. Apgar scores were 7 and 9. In the delivery room, obstruction of the right nostril by a gray, translucent, mobile mass was noted. Grunting, nasal flaring, and tachypnea ensued but resolved within the first 10 hours of life.

A head MR study, obtained on the second day of life, showed a  $1.0 \times 1.5 \times 1.5$ -cm slightly heterogeneous mass in the right nasal cavity (Fig 1A and B). The mass was relatively isointense with brain white matter on T1-, proton density- and T2-weighted images. T2-weighted sagittal images showed a pedicle that seemed to be anchoring the mass to the skull base, but the dural margin in the inferior aspect of the frontal lobes did not appear violated (Fig 1B). No intravenous contrast material was administered.

On the third day of life the infant was transferred to our institution, where cranial and facial CT studies in axial and coronal planes were performed without intravenous contrast medium. The CT scans showed a soft-tissue-density mass expanding the right nasal cavity and deviating the nasal septum to the left (Fig 1C). An apparent defect was noted on the right side of the cribriform plate.

On the basis of the clinical and imaging findings, encephalocele was considered as a leading diagnosis for the mass. After

neurosurgical consultation, the patient was discharged in stable and satisfactory condition and the parents were instructed to bring the infant back in 1 month for elective surgical exploration and resection of the nasal mass.

Endoscopic surgery at 1 month of age revealed a polypoid heterogeneous mass within the right nostril affixed to an intact nasal septum and roof. A normal middle turbinate was present posterior to the mass and the choanal opening was also normal. The mass was fully resected.

Gross pathologic examination revealed a  $1.5 \times 0.5 \times 0.5$ -cm polypoid lesion with a yellow-tan lower portion and tan-pink upper portion (stalk). Microscopically, the tumor was covered with squamous epithelium and composed of round histiocytes and spindle-shaped fibroblasts (Fig 1D and E). Marked fibrosis and hyalinization and numerous eosinophilic droplets were seen. Inflamed granulation tissue, calcified debris, and foreign-body giant cells were present in the stalk. Immunohistochemical markers were positive for  $\alpha_1$ -antichymotrypsin, HAM-56, and vimentin, and focally positive for lysozyme, desmins, and CD-68. Final pathologic diagnosis was benign fibrous histiocytoma with reactive changes.

## Discussion

Fibrous histiocytoma is a soft-tissue neoplasm composed of a biphasic cell population of histiocytes and fibroblasts (5, 6). The histogenesis of this tumor is controversial, and various theories have been proposed (5, 7). On the basis of tissue culture evidence, it was initially thought that these tumors have a histiocytic origin in which the histiocytes act as potential or facultative fibroblasts (2, 5–8). Later, electron microscopic and ultrastructural studies showed cells that exhibit both fibroblastic and histiocytic differentiation in separate parts of the same cell as well as undifferentiated mesenchymal cells (8). These studies suggested that fibrous histiocytomas might arise from undifferentiated mesenchymal stem cells, which can differentiate into fibroblasts or histiocytes (5, 8). More recently, cell marker studies have supported a fibroblastic origin for these tumors (7, 10).

The diagnosis of fibrous histiocytoma is made primarily from histologic analysis. Conventional microscopy will show a mixed population of spindle-shaped fibroblasts and rounded histiocytes (6, 8). The proportion of fibroblasts and histiocytic elements may

Received April 16, 1997; accepted after revision August 12.

From the Departments of Radiology (D.A.S., U.P., A.M., Y.N.), Pathology (A.R.W.), and Pediatrics (P.C.), The University of Rochester Medical Center; and the Department of Radiology, Rochester General Hospital (A.M.), Rochester, NY.

Address reprint requests to David Shrier, MD, Department of Radiology, PO Box 648, The University of Rochester Medical Center, Rochester, NY 14642.

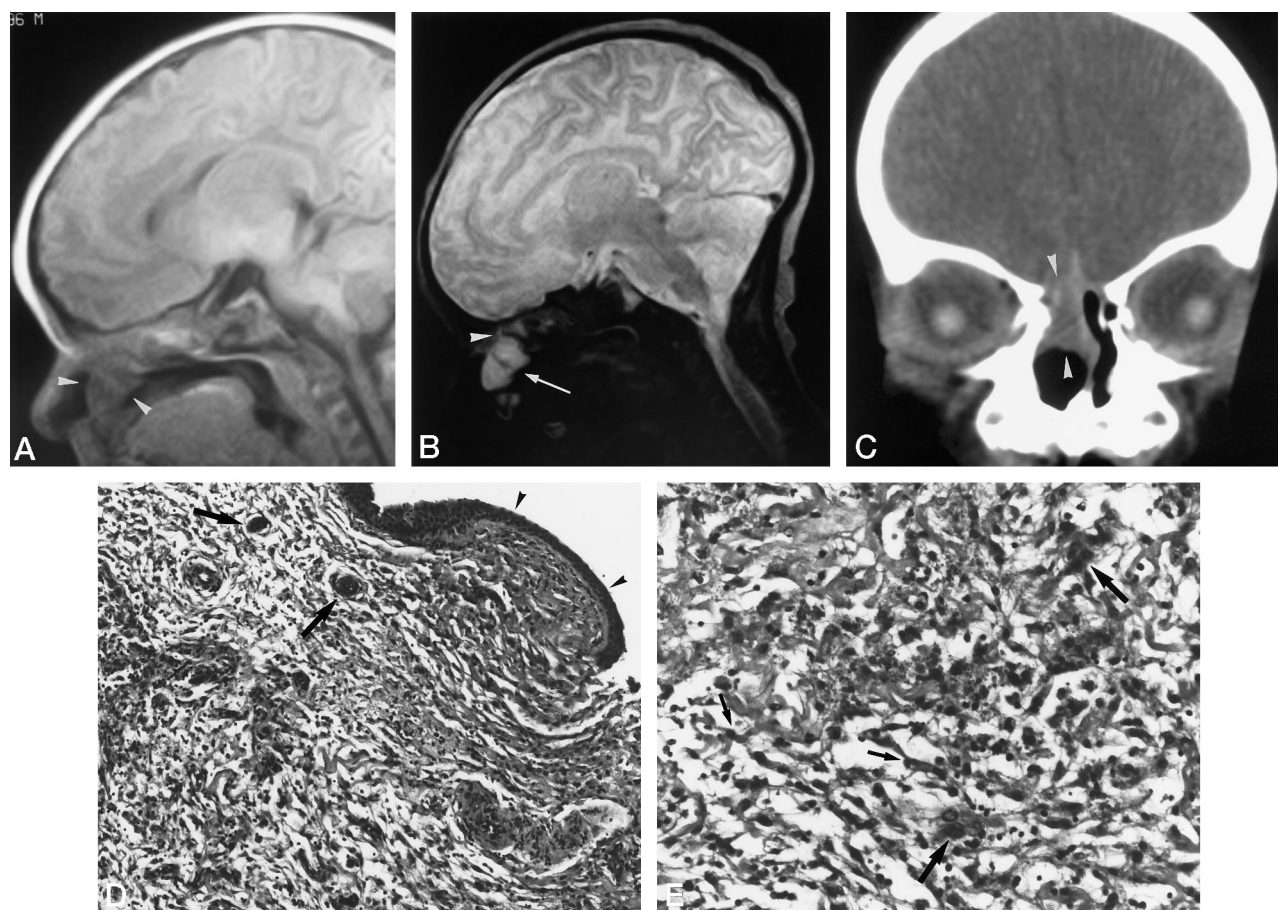


FIG 1. Newborn infant with history of transient respiratory distress resulting from a right-sided intranasal mass.

A, Sagittal T1-weighted MR image (650/25/3 [TR/TE/excitations]) shows a mildly heterogeneous mass in the right nasal cavity (arrowheads) that is relatively isointense with brain parenchyma.

B, Sagittal T2-weighted MR image (4600/117/2) shows increased signal intensity within the mass that remains isointense with brain parenchyma (arrow). A thin pedicle appears to be anchoring the mass to the skull base (arrowhead).

C, Coronal CT scan shows the nasal mass is isodense with brain parenchyma (arrowheads). The nasal septum is deviated to the left.

D, Photomicrograph shows low-power view of the benign fibrous histiocytoma. The tumor is covered by squamous epithelium (arrowheads) and consists of fibroblasts, histiocytes, and infiltrating lymphocytes with intermingled dense collagen and hyalinized vessels (arrows) (hematoxylin-eosin,  $\times 40$ ).

E, High-power photomicrograph shows tumor components of spindle-shaped fibroblasts (small arrows) and rounded histiocytes (large arrows) intermingled with lymphocytes, extensive hyalinization, and numerous eosinophilic intracellular/extracellular granules (hematoxylin-eosin,  $\times 200$ ).

vary greatly, and either the fibroblasts or histiocytes may predominate (6, 8). The cell population within these tumors may also vary greatly as far as cell differentiation and anaplasia are concerned. However, the pathologic criteria for the malignant potential of fibrous histiocytoma have been a matter of controversy (5, 8). Therefore, several classification schemes have been proposed for fibrous histiocytoma based on clinical and pathologic features (5). Histologically, benign fibrous histiocytomas may be confused with other benign lesions, such as neurofibromas, leiomyomas, granulomatous lesions, or nodular fasciitis; whereas malignant fibrous histiocytoma may be confused with other pleomorphic sarcomas, such as fibrous sarcomas, rhabdomyosarcomas, and liposarcomas (6, 7, 8, 10). Immunohistochemical and electron microscopic studies, although nonspecific, may provide confirmatory evidence of fibrous histiocytoma and help to exclude other diagnoses.

Malignant fibrous histiocytoma is the most common soft-tissue sarcoma found in adults; it occurs with greatest frequency in the seventh decade of life (9). This lesion typically arises in the deep soft tissues of the lower and upper extremities and retroperitoneum. Less frequently (1% to 3% of all cases), it is found in the head and neck (10). Benign fibrous histiocytoma is frequently found in sun-exposed skin of the extremities and of the head and neck, and is also often seen within the orbit (5, 6, 8). Affected persons are usually younger than 50 years old. Benign fibrous histiocytoma involving the deeper soft tissues of the head and neck is rare, and involvement of the nasal cavity and paranasal sinuses is very unusual (6).

A recent review of the literature performed by Bielamowicz et al (5) revealed only seven previously reported cases of benign fibrous histiocytoma of the paranasal sinuses or nasal cavity. Only two cases of benign fibrous histiocytoma of the nose or paranasal

sinuses occurring in the neonate have been reported in the literature (1, 2). In both cases, the infants had respiratory distress, and initial diagnosis in each case was encephalocele. Shearer et al (2) reported apparent loss of the cribriform plate on polytomography, whereas Koopman et al (1) reported that intracranial extension of the lesion could not be ruled out by CT. MR studies were not available in either case. Craniotomy was performed in both patients and disclosed no evidence of an intracranial mass, and each subsequently underwent complete surgical resection of the nasal mass.

The differential diagnosis for a nasal mass in a neonate includes nasoethmoidal encephalocele, nasal glioma, dermoid/epidermoid tumor, hemangioma, lymphangioma, inclusion cyst, and, rarely, rhabdomyosarcoma (2–4).

Nasal gliomas are composed of dysplastic brain tissue and are usually separate from the intracranial compartment. In 15% to 20% of cases the tumor is connected to the intracranial space by a fibrous stalk, and there may or may not be enlargement of the foramen cecum (3, 11). The mass may show heterogeneous soft tissue density on CT scans and may have the same signal characteristics as brain on MR images (3, 11). Embryologically, nasal gliomas are encephaloceles in which the connection to the brain has partially or completely sealed off (3). According to Barkovich et al (3), nasoethmoidal encephaloceles should have a mixed signal intensity of both soft tissue and water, and there should be associated enlargement of the foramen cecum and erosion of the anterior margin of the crista galli. In our patient, limited CT depiction of the fovea ethmoidalis and midportion of the cribriform plate due to normal lack of ossification made separation of the mass from the intracranial contents extremely difficult. However, no gross erosion of the crista galli was seen. MR imaging showed an apparent pedicle attaching the tumor to the skull base, but the lack of dural disruption should virtually exclude the diagnosis of an encephalocele. A nasal dermoid/epidermoid would be unlikely, owing to lack of a nasal dimple or sinus. Therefore, of the three most common congenital nasal masses, a nasal glioma should have been the leading preoperative diagnosis in this case. The rare nasal hemangioma, lymphangi-

oma, inclusion cyst, or rhabdomyosarcoma would most likely not have MR signal characteristics mimicking brain white matter.

It is unclear why the signal characteristics of this particular tumor mimicked brain white matter on MR images. The pathologic findings of histiocytosis, fibrosis, and inflammation should produce a relatively nonspecific tumorlike appearance on MR images. Since no previous reports of the MR findings in this entity are available, we do not know whether those in our case are typical.

## Conclusion

Benign fibrous histiocytoma is a rare cause of nasal obstruction in a neonate, but it should be considered in the differential diagnosis of congenital intranasal masses. The MR and CT appearance of this tumor is nonspecific and may closely mimic that of nasal glioma.

## References

1. Koopman CF Jr, Nagle RB, Crone R. Neonatal respiratory distress secondary to nasal fibrous histiocytoma. *Int J Pediatr Otorhinolaryngol* 1987;13:211–217
2. Shearer WT, Schreiber RLL, Ward SP, et al. Benign nasal tumor appearing as neonatal respiratory disease. *Am J Dis Child* 1973; 126:238–241
3. Barkovich AJ, Vandermark P, Edwards MSB, Cogen PH. Congenital nasal masses: CT and MR imaging features in 16 cases. *AJNR Am J Neuroradiol* 1991;12:105–116
4. Mafee MF. Nonepithelial tumors of the paranasal sinuses and nasal cavity. *Radiol Clin North Am* 1993;31:75–90
5. Bielamowicz S, Dauer MS, Chang B, Zimmerman MC. Noncutaneous benign fibrous histiocytoma of the head and neck. *Otolaryngol Head Neck Surg* 1995;113:140–146
6. Rice DH, Batsakis JG, Headington JT, Boles R. Fibrous histiocytomas of the nose and paranasal sinuses. *Arch Otolaryngol* 1974; 100:398–401
7. Enzinger FM, Weiss SW. Benign fibrohistiocytic tumors. In: *Soft Tissue Tumors*. St Louis: Mosby; 1995:293–303
8. Perzin KH, Fu Y-S. Non-epithelial tumors of the nasal cavity, paranasal sinuses and nasopharynx: a clinico-pathologic study XI: fibrous histiocytomas. *Cancer* 1980;45:2616–2626
9. Ko J-Y, Chen C-L, Lui LT, Hsu M-M. Radiation-induced malignant fibrous histiocytoma in patients with nasopharyngeal carcinoma. *Arch Otolaryngol Head Neck Surg* 1996;122:535–538
10. Singh B, Shaha A, Har-El G. Malignant fibrous histiocytoma of the head and neck. *J Craniomaxillofac Surg* 1993;21:262–265
11. Puppala B, Mangurten HH, McFadden J, Lyizos N, Taxy J, Pelletiere E. Nasal glioma presenting as neonatal respiratory distress: definition of the tumor mass by MRI. *Clin Pediatr* 1990;29:49–52