



Get Clarity On Generics

Cost-Effective CT & MRI Contrast Agents



FRESENIUS
KABI

WATCH VIDEO

AJNR

CSF spaces in idiopathic normal pressure hydrocephalus: morphology and volumetry.

H Kitagaki, E Mori, K Ishii, S Yamaji, N Hirono and T Imamura

AJNR Am J Neuroradiol 1998, 19 (7) 1277-1284

<http://www.ajnr.org/content/19/7/1277>

This information is current as
of August 25, 2025.

CSF Spaces in Idiopathic Normal Pressure Hydrocephalus: Morphology and Volumetry

Hajime Kitagaki, Etsuro Mori, Kazunari Ishii, Shigeru Yamaji,
Nobutsugu Hirono, and Toru Imamura

PURPOSE: Idiopathic normal pressure hydrocephalus (NPH) is an important cause of dementia in the elderly; however, idiopathic NPH is often difficult to differentiate from normal aging and vascular dementias in which brain atrophy with ventricular dilatation (hydrocephalus ex vacuo or central atrophy) is present. To elucidate the distinctive features of the distribution of CSF in idiopathic NPH, we used MR imaging to investigate the morphologic features and volume of the CSF space in patients with idiopathic NPH compared with those with other dementias.

METHODS: We assessed the size of four CSF compartments (the ventricle, basal cistern, sylvian space, and suprasylvian subarachnoid space) in 11 shunt-responsive patients with idiopathic NPH by semiquantitative and volumetric analyses of coronal T1-weighted MR images. The results were compared with those in 11 age- and sex-matched patients with Alzheimer disease and in 11 patients with vascular dementia.

RESULTS: In patients with idiopathic NPH, the CSF volume was significantly increased in the ventricles and decreased in the superior convexity and medial subarachnoid spaces as compared with patients with other dementias. The sylvian CSF volume in patients with idiopathic NPH was significantly greater than in patients with Alzheimer disease. The volume of the basal cistern was comparable among the three groups. In several patients with idiopathic NPH, focally dilated sulci were observed over the convexity or medial surface of the hemisphere.

CONCLUSION: Our results indicate that findings of enlarged basal cisterns and sylvian fissures and of focally dilated sulci support, rather than exclude, the diagnosis of shunt-responsive idiopathic NPH and suggest that this condition is caused by a suprasylvian subarachnoid block.

Normal pressure hydrocephalus (NPH) is a neurologic disorder occurring in patients who exhibit the clinical triad of gait disturbance, mental deterioration, and urinary incontinence, which are reversible with ventricular shunting (1, 2). NPH is divided into two subgroups, secondary NPH (3) and idiopathic NPH (2). Secondary NPH may develop as a result of abnormalities of the arachnoid, such as those that develop after subarachnoid hemorrhage, meningitis, cranial trauma, or intracranial surgery. One third of NPH cases are idiopathic (3–5).

Neuroimaging plays an important role in the diagnosis of NPH; CT is a useful tool (6–9), and MR imaging of the dynamics of CSF provides some additional help (10, 11). MR imaging—which can delineate changes in periventricular white matter (12, 13), reveal the CSF flow void through the aqueduct (14–17), and measure the volume of the CSF (18, 19)—is the most powerful tool for the evaluation of this disorder. The imaging signs of NPH include the distinctive morphologic changes of disproportionately dilated ventricles and a lack of cortical atrophy (6–9). MR imaging is more sensitive than CT in depicting CSF spaces (13); however, the morphologic features of idiopathic NPH remain undefined. In addition, idiopathic NPH may frequently affect the elderly (20–22), in whom these features may be associated with age-related brain atrophy (23, 24). NPH is often difficult to differentiate from degenerative and vascular dementias in older patients (25) because of the occurrence of brain atrophy with ventricular dilatation, also called hydrocephalus ex vacuo or central atrophy (26). To elucidate the distinctive features of

Received November 12, 1997; accepted after revision March 9, 1998.

From the Neuroimaging Research and Radiology Service (H.K., K.I., S.Y.), and the Clinical Neurosciences and Neurology and Neurorehabilitation Services Department of Neurosciences (E.M., N.H., T.I.), Hyogo Institute for Aging Brain and Cognitive Disorders, Himeji, Japan.

Address reprint requests to Hajime Kitagaki, MD, Division of Neuroimaging Research, Hyogo Institute for Aging Brain and Cognitive Disorders, 520, Saisho-Ko, Himeji 6700981 Japan.

TABLE 1: Clinical features of patients with idiopathic normal pressure hydrocephalus

Patient	Age, y/Sex	MMSE/ADAS	Gait Disturbance	Urinary Incontinence	Dementia	CSF Pressure, mm H ₂ O	Effect of CSF Tap Test
1	75/M	21/31	+	+	+	120	—
2	74/F	19/17	+	+	+	150	+
3	73/M	25/15	+	+	+	150	+
4	79/M	9/58	+	+	+	90	+
5	88/M	13/36	+	+	+	90	+
6	82/M	20/21	+	—	+	120	+
7	82/M	16/35	+	+	+	160	+
8	75/M	21/17	+	+	+	70	+
9	82/M	18/25	+	+	+	140	+
10	78/M	24/18	+	+	+	120	+
11	74/F	19/15	+	+	+	160	+

Note.—MMSE indicates Mini-Mental State Examination; ADAS, Alzheimer Disease Assessment Scale.

CSF distribution in idiopathic NPH, we investigated the morphologic features and volume of the CSF spaces in patients with idiopathic NPH and compared these findings with the results found in patients with other dementias by using MR imaging.

Methods

Subjects

Eleven patients with shunt-responsive idiopathic NPH and over 65 years of age were selected from those who were admitted to our hospital from October 1, 1993, to March 31, 1997, for the investigation of dementia. The diagnosis of idiopathic NPH was made when gait disturbance of an ataxic or apraxic nature was a predominant symptom; when either dementia or urinary incontinence, or both, were present; when the ventricular system appeared to be dilated on preoperative MR images; when diseases or conditions that might explain the patient's clinical symptoms were absent; when no history or evidence of conditions that might cause secondary NPH was indicated; and when clinical symptoms improved after shunt surgery. The clinical characteristics of each patient are summarized in Table 1. The mean age of the 11 patients (two women and nine men) was 78.4 ± 4.7 (SD) years. The mean Mini-Mental State Examination (MMSE) score (27, 28) was 18.6 ± 4.6 , and the mean Alzheimer Disease Assessment Scale (ADAS) score (29, 30) was 26.2 ± 13.1 . All patients had mild to severe dementia, and 10 patients experienced urinary incontinence. Lumbar punctures with CSF removal produced temporary improvement, at least for gait disturbance, in 10 patients. All patients underwent ventriculoperitoneal shunt surgery. After shunt surgery, improvement in locomotion was noted in 10 patients and in cognitive function in six. In one patient, although an intracerebral hematoma and left-sided hemiparesis developed after shunt surgery, urinary incontinence subsided.

For comparison, 11 patients with Alzheimer disease and 11 with vascular dementia were randomly sampled from the same cohort as those with idiopathic NPH and matched for sex, age, and MMSE score. The inclusion criteria for Alzheimer disease were as follows: fulfillment of the criteria established by the National Institute of Neurological and Communicative Disorders and by the Stroke-Alzheimer's Disease and Related Disorders Association for probable Alzheimer disease (31), no complications from other neurologic diseases, and no evidence of focal brain lesions on MR images. The inclusion criteria for vascular dementia comprised fulfillment of the *Diagnostic and Statistical Manual of Mental Disorders-IV* criteria for vascular dementia (32), presence of one or more ischemic lesions in each cerebral hemisphere on T1-weighted MR images, and

presence of focal neurologic signs. In the group with Alzheimer disease (two women and nine men), the mean age was 78.6 ± 4.5 years, the mean MMSE score was 18.3 ± 3.4 , and the mean ADAS score was 23.2 ± 12.0 . In the group with vascular dementia (two women and nine men), the mean age was 78.2 ± 3.4 years, the mean MMSE score was 17.3 ± 3.8 , and the mean ADAS score was 31.6 ± 10.3 . No significant difference was evident among the groups with idiopathic NPH, Alzheimer disease, and vascular dementia in sex, age, MMSE score, and ADAS score ($P > .25$, one-way analysis of variance).

MR Imaging and Analysis

MR was performed with a 1.5-T superconducting magnet. Coronal and axial spin-echo T1-weighted images with parameters of 550/15/4 (TR/TE/excitations) covering the whole brain perpendicular or parallel to the anteroposterior commissure plane were obtained with a section thickness of 5 mm and an intersection gap of 2.5 mm. In all acquisitions, the field of view was 200×200 mm and the matrix size was 256×256 .

We assessed the morphologic changes of the CSF by categorizing the intracranial CSF spaces into several compartments: the ventricles, including the lateral ventricle, the third ventricle, the aqueduct, and the fourth ventricle; the sylvian fissure; the superior convexity and the medial subarachnoid spaces, including the sulci and the longitudinal fissure; and the basal cistern. The intracranial CSF spaces were categorized on the following four-point scale according to the modified MR imaging rating protocol of the Consortium to Establish a Registry for Alzheimer's Disease (33): decreased, normal, mildly or moderately dilated, and severely dilated.

Three neuroradiologists blinded to the clinical data were independently employed in this assessment. To determine the interrater reliability of the rating, an intraclass correlation coefficient for each compartment was calculated. When disagreement among reviewers occurred, a consensus rating was used for further analysis.

In addition to the visual rating, a quantitative analysis was conducted by using a volumetric technique. We divided supratentorial CSF reserves into the following four compartments: the lateral and third ventricles, the superior convexity and the medial subarachnoid spaces above the level of the sylvian fissure (suprasylvian CSF), the sylvian fissure, and the basal cistern (Fig 1). The sylvian fissure was defined as the CSF space surrounded by the frontoparietotemporal operculum. The medial border of the sylvian fissure was the insular or the tangent plane to the most medial part of the temporal lobe. The basal cistern was defined as the CSF space including the cistern of the lamina terminalis, the chiasmatic cistern, the interpeduncular cistern, the ambient cistern, the pontine cistern, and the orbitofrontal subarachnoid space. The lateral border of the basal cistern was the medial temporal lobe, the tangent plane to

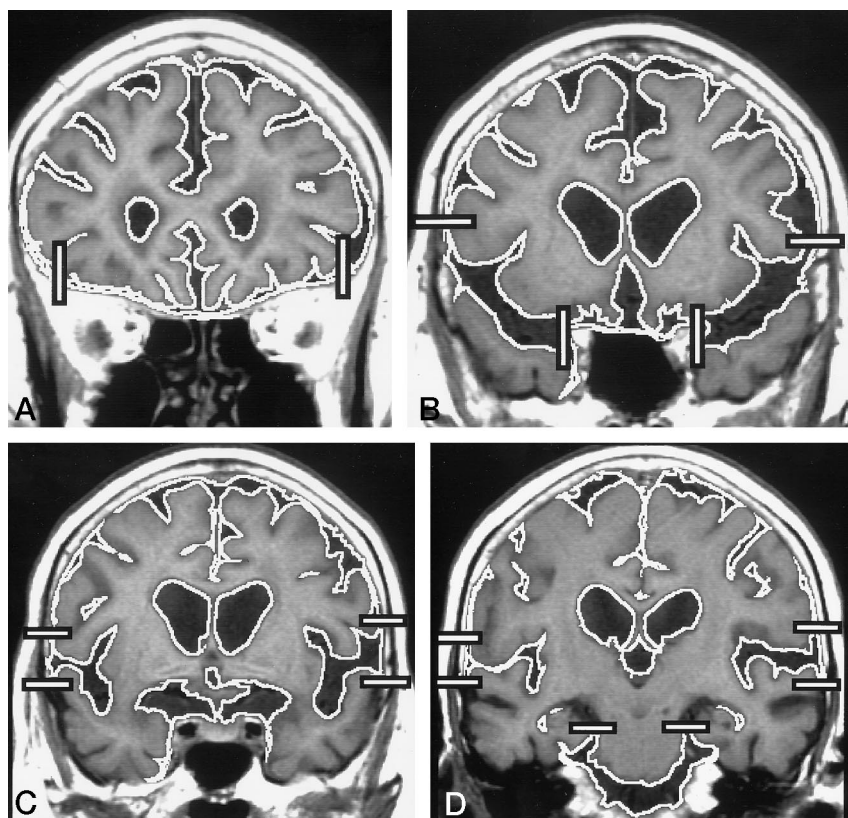


FIG 1. A-D, Illustrative sections of coronal T1-weighted images (550/15/4) selected from a patient with Alzheimer disease show the horizontal and vertical lines that partition the CSF into the basal cistern, sylvian fissure, and suprasylvian subarachnoid space. The boundary of the CSF is determined by density thresholding.

the medial aspect of the temporal lobe, or the most lateral bank of the orbital gyrus. The CSF volume in each compartment was compared between the preoperative and postoperative MR images of five patients whose postoperative images were obtained at our hospital.

The MR data sets of coronal images were transmitted directly to a personal computer from the MR unit and analyzed by using the public domain NIH Image version 1.60 program (written by Wayne Rasband at the NIH and available from the Internet by anonymous ftp from zippy.Nimh.Nih.Gov or on floppy disk [No. PB93-504868] from NTIS, 5285 Port Royal Rd, Springfield, VA 22161), with residential macro programs developed at our institute (26, 34). The CSF was extracted by using a density threshold in a range between minimum and maximum pixel values, where the maximum value was a half value of the mean pixel value of gray matter (represented by the caudate head) and the mean value of CSF (represented by the lateral ventricle), and the minimum value was the minimum value of CSF (26). The section volume of each compartment was obtained by automatically counting the number of pixels within the segmented regions and then multiplying the number by the voxel size, including the intersection gap ($200/256^2 \times 7.5 = 4.58 \text{ mm}^3$). For the total intracranial volume measurement, the cranial cavity was semiautomatically segmented and extracted by using a density threshold set above the minimum value of the CSF (the lateral ventricle). When needed, outlining was supplemented with a manually driven mouse cursor along the inner table of the skull and along the margins of the cerebral hemispheres basally (35). The CSF volume in each compartment was normalized for intracranial volume and was expressed as the percentage of volume (to intracranial volume). All measurements were conducted by one neuroradiologist blinded to clinical information.

Differences among the groups was analyzed by using the Kruskal-Wallis one-way analysis of variance test followed by the post-hoc Tukey test with Dunn's joint ranking (36) for ordinal data obtained by visual inspection, and by using one-way analysis of variance and Tukey post hoc analysis for the

TABLE 2: Interrater reliability of visual rating of CSF spaces

	Intraclass Correlation
Lateral ventricle	.929
Third ventricle	.900
Aqueduct	.608
Fourth ventricle	.684
Sylvian fissure	.696
Superior medial space	.689
Superior convexity space	.571
Basal cistern	.418

volumetric data. The Pearson correlation coefficients were used for the correlational analysis, and paired *t*-test statistics were used for pre- and postoperative comparison. All statistical analyses were performed on the statistical software package STATISTICA, version 4.1 (StatSoft Inc, Evanston, IL). The statistically significant level was set at $P < .05$.

Results

Visual Rating

The interrater reliability of the rating as expressed by intraclass correlation coefficients was significant for the lateral and third ventricles and reasonable for the sylvian fissure, the superior medial space, the fourth ventricle, and the aqueduct, whereas the ratings of the superior convexity space and the basal cistern were insufficient (Table 2).

The results of the visual inspection are summarized in Table 3. Although the lateral and third ventricles were dilated in most of the patients in the three groups, dilatation of the ventricular system was most

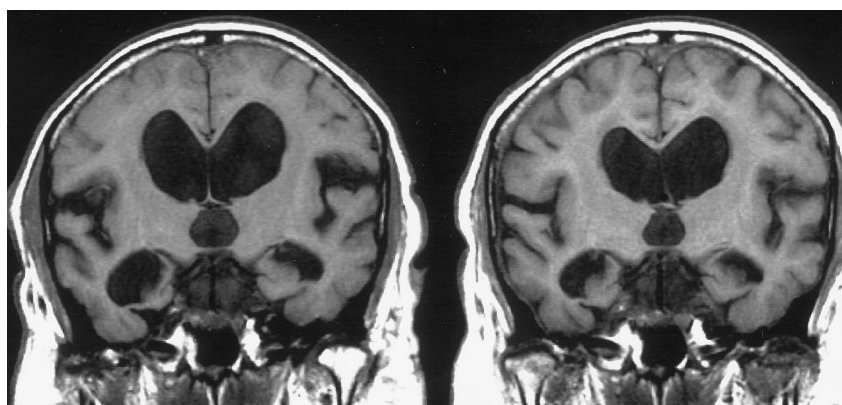
TABLE 3: Results of visual rating of CSF spaces

	NPH*	AD*	VD*	Among Groups	NPH vs AD	NPH vs VD	AD vs VD
Lateral ventricle	9/2/0/0	0/6/5/0	1/7/3/0	<.001	<.001	.004	NS
Third ventricle	7/4/0/0	0/7/4/0	2/6/3/0	.002	.002	.04	NS
Aqueduct	4/6/1/0	0/1/10/0	0/2/9/0	<.001	<.001	.001	NS
Fourth ventricle	2/6/3/0	0/1/10/0	0/3/8/0	.005	.004	NS	NS
Sylvian fissure	4/5/2/0	0/4/7/0	0/8/3/0	.02	.014	NS	NS
Superior medial space	0/0/4/7	0/7/4/0	1/5/5/0	<.001	<.001	<.001	NS
Superior convexity space	0/0/5/6	0/7/4/0	2/5/4/0	<.001	.002	<.001	NS
Basal cistern	1/4/6/0	0/5/6/0	0/8/3/0	NS	NA	NA	NA

Note.—NPH indicates idiopathic normal pressure hydrocephalus; AD, Alzheimer disease; VD, vascular dementia; NS, not significant; NA, not applicable.

* Number of patients shown with severe dilatation, mild or moderate dilatation, normal, or decreased.

FIG 2. Coronal T1-weighted MR images (550/15/4) in a patient with idiopathic NPH before (*left*) and after (*right*) ventriculoperitoneal shunt surgery. The CSF volume is diminished both in the ventricles (by 28%) and in the sylvian fissure (by 22%) after surgery.



severe in the group with idiopathic NPH, as expected. Dilatation of the aqueduct and the fourth ventricle was present in most of the patients in the group with idiopathic NPH, but was uncommon in the other two groups. All parts of the ventricular system were significantly larger in the group with idiopathic NPH than in the groups with Alzheimer disease or vascular dementia. On the contrary, both the convexity and the medial subarachnoid spaces were not enlarged in most of the patients with idiopathic NPH, whereas they were dilated in most of the patients with Alzheimer disease or vascular dementia. Their sizes were significantly smaller in the group with idiopathic NPH than in the other two groups. The sylvian fissure and the basal cistern were dilated in most of the patients in the three groups; the sylvian fissure was larger in the group with idiopathic NPH than in the group with Alzheimer disease, whereas the basal cistern did not differ among the three groups. The size of the sylvian fissure decreased together with ventricular size after ventriculoperitoneal shunt surgery (Fig 2). A feature observed exclusively in idiopathic NPH is that one or more sulci are dilated in isolation (Fig 3). This isolated sulcal dilatation was present over the medial surface and convexity in three patients with idiopathic NPH (patients 2, 6, and 7). On the surface reconstructions of automatically segmented brain sections from three-dimensional spoiled gradient-echo MR images (37, 38), the isolated sulcal dilatation appeared semiovoid in shape and was connected with the basal

cistern or the sylvian fissure by narrow channels of sulci (Fig 4).

CSF Volume Measurement

The results of volume measurement are summarized in Table 4. No significant difference was observed in intracranial volume among the three groups. The mean volumes (either measured or normalized) of suprasylvian CSF and of ventricular CSF were greater in the group with idiopathic NPH than in the groups with Alzheimer disease or vascular dementia. On the contrary, the suprasylvian CSF volume, either measured or normalized, was smaller in the group with idiopathic NPH than in the other two groups. The association of a large ventricular volume and a small suprasylvian CSF volume was a discriminative finding in idiopathic NPH (Fig 5). The mean sylvian CSF volume in the group with idiopathic NPH, either measured or normalized, was significantly larger than in the group with Alzheimer disease and was somewhat larger than in the group with vascular dementia, and the mean basal cisternal CSF volume did not differ among the groups. In the group with idiopathic NPH, the normalized suprasylvian CSF volume was negatively correlated with the normalized sylvian CSF volume ($r = -.730$, $P = .011$) and with the normalized basal cisternal CSF volume ($r = -.750$, $P = .008$) (Fig 6). A marginal negative correlation was evident between the normalized su-

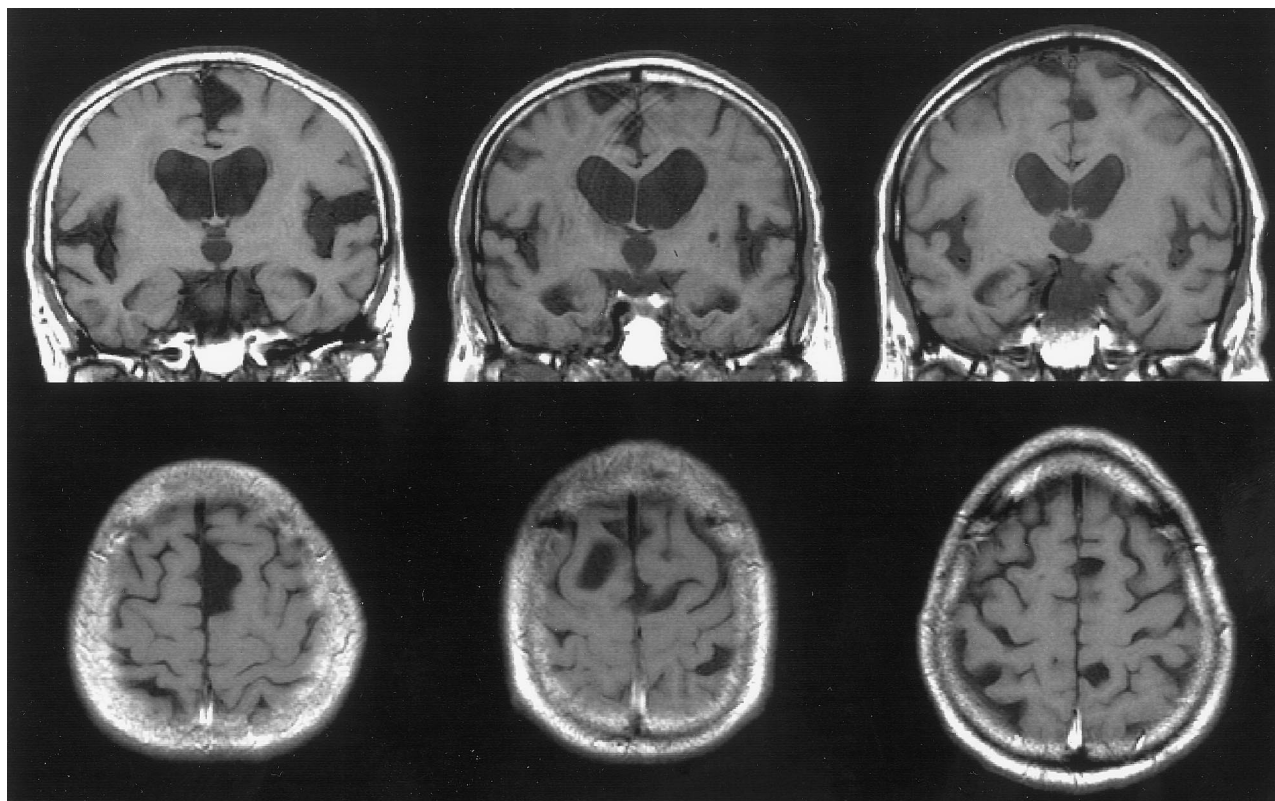


FIG 3. Focally dilated sulci in patients with idiopathic NPH (patients 2, 6, and 7, respectively). Coronal and axial T1-weighted MR images (550/15/4) show focally dilated sulci over the frontal convexity and medial surface, as well as enlarged ventricles, expanded sylvian fissure and basal cistern, and constricted convexity and medial surface sulci.

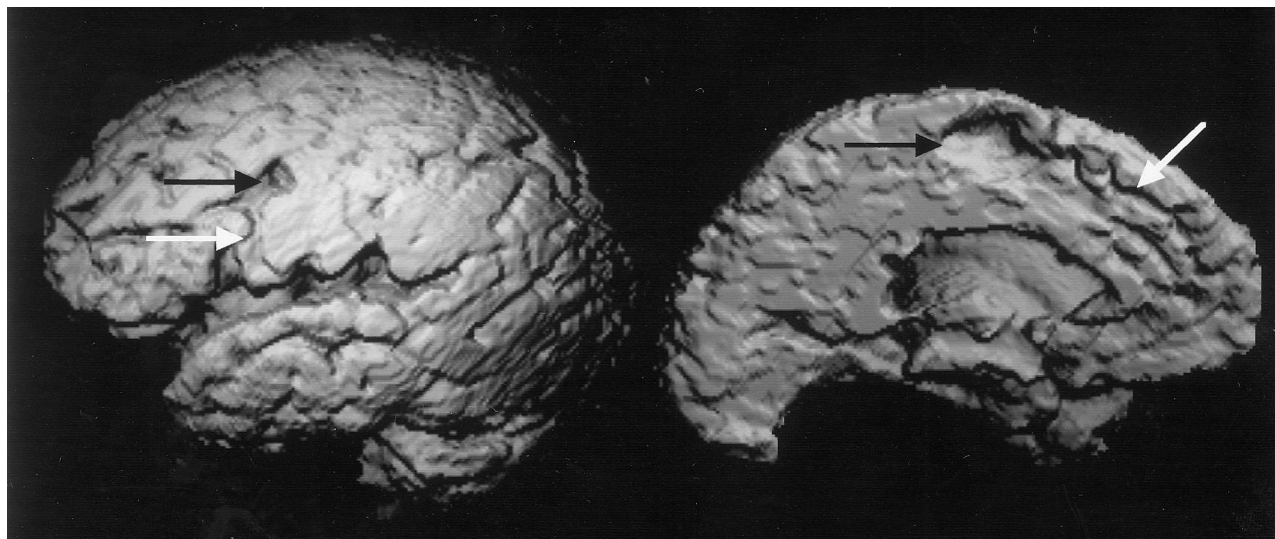


FIG 4. Patient 2: Lateral and medial surface reconstructions of automatically segmented brain sections from three-dimensional spoiled gradient-echo MR images (14/3/2/20° flip angle) of a patient with idiopathic NPH. Note the focally dilated, semiovoid-shaped sulci over the frontal convexity and medial surface (black arrows) and the narrow channels connecting dilated sulci with the sylvian fissure or basal cistern (white arrows), as well as the expanded sylvian fissure, the otherwise constricted convexity, and the medial surface sulci.

prasyllian CSF volume and the normalized ventricular CSF volume ($r = -.521$, $P = .100$).

As compared with the preoperative state, the mean postoperative CSF volume of five patients with idiopathic NPH was significantly decreased in the sylvian space (preoperative = 56.5 ± 7.0 mL, postoperative = 40.8 ± 1.8 mL, $P = .023$) and in the ventricle

(144.5 ± 29.8 mL, 95.4 ± 27.3 mL, $P = .015$) and was marginally decreased in the basal cistern (39.5 ± 7.5 mL, 34.5 ± 11.7 mL, $P = .057$). However, the mean postoperative CSF volume was significantly increased in the suprasylvian space (61.5 ± 34.0 mL, 89.1 ± 34.5 mL, $P = .024$). The analysis based on the normalized CSF volume yielded similar results.

TABLE 4: Results of measurement of CSF volume

	NPH	AD	VD	Among Groups	NPH vs AD	NPH vs VD	AD vs VD
Intracranial volume (mL)	1537 ± 105	1497 ± 161	1534 ± 145	NS	NA	NA	NA
Sylvian CSF (mL)	59.4 ± 11.4	44.9 ± 11.8	52.7 ± 10.7	.019	.015	NS	NS
Suprasylvian CSF (mL)	51.7 ± 27.9	133.0 ± 38.2	108.6 ± 40.9	<.001	<.001	.003	NS
Ventricular CSF (mL)	142.9 ± 34.4	57.7 ± 26.1	65.3 ± 20.9	<.001	<.001	<.001	NS
Basal CSF (mL)	40.0 ± 6.2	38.6 ± 6.6	43.2 ± 8.0	NS	NA	NA	NA
Percentage of sylvian CSF	3.9 ± 0.9	3.0 ± 0.7	3.4 ± 0.6	.026	.02	NS	NS
Percentage of suprasylvian CSF	3.4 ± 1.8	8.9 ± 2.5	7.0 ± 2.2	<.001	<.001	.002	NS
Percentage of ventricular CSF	9.3 ± 2.1	3.8 ± 1.5	4.3 ± 1.4	<.001	<.001	<.001	NS
Percentage of basal CSF	2.6 ± 0.5	2.6 ± 0.5	2.8 ± 0.6	NS	NA	NA	NA

Note.—NPH indicates idiopathic normal pressure hydrocephalus; AD, Alzheimer disease; VD, vascular dementia; NS, not significant; NA, not applicable.

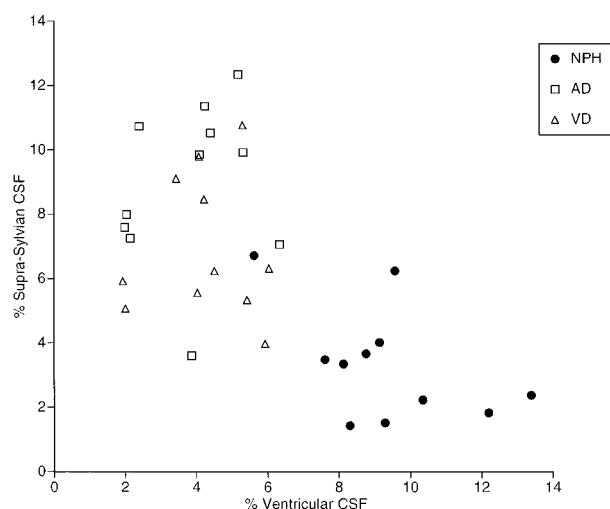


FIG 5. Relationship between normalized ventricular CSF volume and normalized suprasylvian CSF volume (percentage of volume to intracranial volume) (AD, Alzheimer disease; NPH, normal pressure hydrocephalus; VD, vascular dementia).

Discussion

In our reliability analysis of the visual rating of the CSF spaces, assessment of the ventricles and sylvian and superior medial fissures was sufficiently reliable, whereas the reliability of rating of the superior convexity space and basal cistern was less so, indicating an advantage for volumetry in assessing some of the CSF spaces. Nevertheless, the results of both the visual rating and volumetry were consistent. In patients with shunt-responsive idiopathic NPH, the CSF volume was significantly increased in all parts of the ventricular system as compared with those with Alzheimer disease or vascular dementia, whereas the superior convexity and medial subarachnoid CSF spaces were reduced. The CSF in the sylvian fissure was significantly greater in those patients with idiopathic NPH than in those with Alzheimer disease. The CSF in the basal cisterns was comparable among the three groups, suggesting that the CSF volume was increased in these structures as compared with normal structures. In the patients with idiopathic NPH, the CSF volumes in the sylvian fissure and in the basal cistern were negatively correlated with the suprasylvian CSF volume. All abnormalities of CSF distribu-

tion detected in idiopathic NPH were corrected with shunt surgery, indicating that these changes are related to NPH. Although an enlarged ventricular system and decreased sulci are characteristic of communicating hydrocephalus, including NPH (6–9), the finding of an enlargement of the sylvian fissure and the basal cistern is a previously undescribed feature of shunt-responsive idiopathic NPH.

Another hitherto unrecognized feature observed in patients with idiopathic NPH is that a few sulci over the convexity or medial surface of the hemisphere were dilated in isolation. This isolated semiovoid sulcal dilatation appeared to be caused by the accumulation of CSF in the subarachnoid space in a specific sulcus. In other types of hydrocephalus, the pressure from the ventricular system does not occur uniformly over the brain surface, resulting in uneven dilatation of the sulci. Although atrophy may predominate in the parietotemporal association cortices in Alzheimer disease, and focal cortical destruction or atrophy may be present in vascular dementia, the combination of focal enlargement of sulci with an otherwise constricted subarachnoid space is unlikely under those conditions. Moreover, this semiovoid sulcal dilatation is morphologically distinctive from dilated sulci surrounded by atrophic gyri in Alzheimer disease and vascular dementia.

These findings are valuable when assessing MR images of elderly patients. The findings of enlarged basal cisterns and sylvian fissures and of focally dilated sulci do not exclude, but rather support, the diagnosis of shunt-responsive idiopathic NPH when accompanied by large ventricles and tight suprasylvian subarachnoid spaces. Evaluation of the ventricular system and the suprasylvian (but not the whole) subarachnoid space by visual inspection or MR imaging volumetry can differentiate shunt-responsive idiopathic NPH from Alzheimer disease and vascular dementia, which are the most common causes of dementia in the elderly. Although a few studies have pointed out that an enlarged sylvian fissure is a sign that the patient would not respond to a shunt (6, 8, 39), our results indicate that it is a common and inconsequential sign in the elderly.

These findings may also explain the underlying mechanisms of idiopathic NPH in the elderly. The

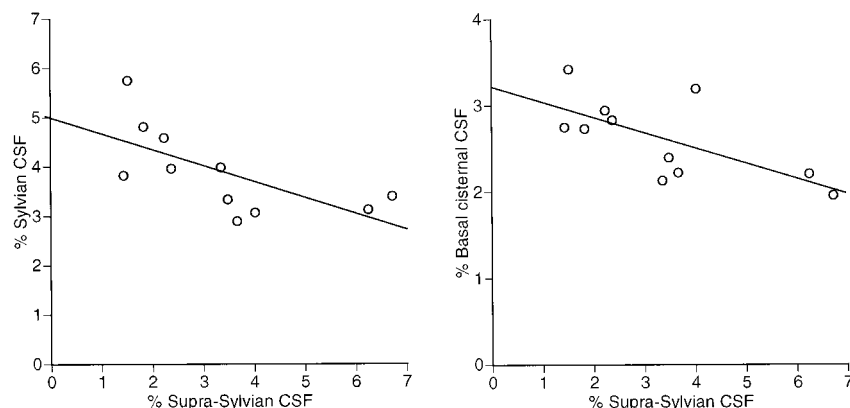


FIG 6. Correlations of normalized suprasylvian CSF volume with normalized sylvian CSF volume and with normalized basal cisternal CSF volume in patients with idiopathic NPH. The normalized suprasylvian CSF volume is negatively correlated with the normalized sylvian CSF volume ($r = -.730$, $P = .011$) and with normalized basal cisternal CSF volume ($r = -.750$, $P = .008$).

site of impaired CSF flow in hydrocephalus may be situated within the ventricles or in the subarachnoid space. In communicating hydrocephalus, impairment of CSF flow is distal to the fourth ventricle, most often at the level of the basal cisterns (20). A cisternal block may be present in NPH because of subarachnoid hemorrhage, meningitis, cranial trauma, or intracranial surgery, and, as such, would be present with the dilated basal cisterns and sylvian fissures as observed in this study. Defective CSF absorption at the arachnoid villi is generally believed to be a possible mechanism of idiopathic NPH (40). This mechanism, which causes CSF stagnation in the flow up to the villi, does not produce a pressure gradient between the ventricles and the subarachnoid space over the convexity (41). A high pressure in the ventricles and a low pressure in the subarachnoid space are prerequisites for ventricular enlargement and a constricted subarachnoid space. The finding that the size of the sylvian fissure diminished together with ventricular size after shunt surgery suggests a balanced pressure between the two compartments. The most likely explanation for this pattern of CSF hydrodynamics is that the site of impaired CSF flow is situated within the subarachnoid space over the convexity and medial hemispheric surface. Isolated CSF retention in the sulci over the convexity or medial hemispheric surface further supports this "suprasylvian subarachnoid block" hypothesis. Adams et al (5) and Adams (42) suggested that a low-grade asymptomatic meningeal disease, possibly fibrosing meningitis of undetermined origin, was present in idiopathic NPH (5, 42). Meningeal fibrosis, especially involving the arachnoid coverings of the convexities, has been detected in several autopsy studies of idiopathic NPH (43, 44). The sulci surrounded by blocked subarachnoid space but connected by channels to the basal cisterns or sylvian fissures should be enlarged in parallel with expansion of the basal cisterns and sylvian fissures. This hypothesis is in agreement with the suggestion by Wikkelsö et al (8) that in patients in whom enlargement of the superior convexity sulci and the sylvian fissure is corrected by shunt surgery, the enlarged sulci and fissures function as transport sulci.

Conclusion

Morphologically distinctive features of the CSF spaces are found in shunt-responsive idiopathic NPH in the elderly. The basal cistern and the sylvian fissure are enlarged in elderly patients with shunt-responsive idiopathic NPH, and a few sulci over the convexity or medial hemispheric surface may be dilated in isolation. Our results indicate that findings of enlarged basal cisterns and sylvian fissures and of focally dilated sulci do not exclude, but support, the diagnosis of shunt-responsive idiopathic NPH and suggest that this condition is caused by a suprasylvian subarachnoid block.

Acknowledgments

We thank Tatsuo Shimomura, Yoshitaka Ikejiri, Mamoru Hashimoto, Mutsumi Sato, Taiki Nakaoka, Masamichi Nakai, and Hikari Yamashita (Clinical Neurosciences, Hyogo Institute for Aging Brain and Cognitive Disorders) for providing the patients' clinical data.

References

1. Hakim S, Adams RD. The special clinical problem of symptomatic hydrocephalus with normal cerebrospinal fluid pressure: observations on cerebrospinal fluid hydrodynamics. *J Neurol Sci* 1965;2:307-327
2. Adams RD, Fisher CM, Hakim S, Ojemann RG, Sweet WH. Symptomatic occult hydrocephalus with "normal" cerebrospinal fluid pressure: a treatable syndrome. *N Engl J Med* 1965;273:117-126
3. Katzman R. Normal pressure hydrocephalus. In: Wells CE, ed. *Dementia*. 2nd ed. Philadelphia: F.A. Davis; 1977:69-92
4. Vanneste JA, Augstijn P, Dirven C, Tan WF, Goedhart ZD. Shunting normal-pressure hydrocephalus: do the benefits outweigh the risks? A multicenter study and literature review. *Neurology* 1992;42:54-59
5. Adams RD, Victor M, Ropper AH. Disturbances of cerebrospinal fluid and its circulation, including hydrocephalus and meningeal reactions. In: *Principles of Neurology*. 6th ed. New York: McGraw-Hill; 1997:623-641
6. Gunasekera L, Richardson AE. Computerized axial tomography in idiopathic hydrocephalus. *Brain* 1977;100:749-754
7. Tans JT. Differentiation of normal pressure hydrocephalus and cerebral atrophy by computed tomography and spinal infusion test. *J Neurol* 1979;222:109-118
8. Wikkelsö C, Andersson H, Blomstrand C, Matousek M, Svendsen P. Computed tomography of the brain in the diagnosis of and prognosis in normal pressure hydrocephalus. *Neuroradiology* 1989;31:160-165
9. Jacobs L, Kinkel W. Computerized axial transverse tomography in

- normal pressure hydrocephalus. *Neurology* 1976;26:501-507
10. Bannister R, Gilford E, Kocen R. Isotope encephalography in the diagnosis of dementia due to communicating hydrocephalus. *Lancet* 1967;2:1014-1017
 11. Enzmann DR, Norman D, Price DC, Newton TH. Metrizamide and radionuclide cisternography in communicating hydrocephalus. *Radiology* 1979;130:681-686
 12. George AE. Chronic communicating hydrocephalus and periventricular white matter disease: a debate with regard to cause and effect. *AJNR Am J Neuroradiol* 1991;12:42-44
 13. Brant-Zawadzki M, Kelly W, Kjos B, et al. Magnetic resonance imaging and characterization of normal and abnormal intracranial cerebrospinal fluid (CSF) spaces. *Neuroradiology* 1985;27:3-8
 14. Bradley WG Jr, Kortman KE, Burgoyne B. Flowing cerebrospinal fluid in normal and hydrocephalic states: appearance on MR images. *Radiology* 1986;159:611-616
 15. Bradley WG Jr, Whittmore AR, Kortman KE, et al. Marked cerebrospinal fluid void: indicator of successful shunt in patients with suspected normal-pressure hydrocephalus. *Radiology* 1991;178:459-466
 16. Bradley WG Jr. Magnetic resonance imaging in the evaluation of cerebrospinal fluid flow abnormalities. *Magn Reson Q* 1992;8:169-196
 17. Gideon P, Stahlberg F, Thomsen C, Gjerris F, Sorensen PS, Henriksen O. Cerebrospinal fluid flow and production in patients with normal pressure hydrocephalus studied by MRI. *Neuroradiology* 1994;36:210-215
 18. Condon B, Patterson J, Wyper D, et al. Use of magnetic resonance imaging to measure intracranial cerebrospinal fluid volume. *Lancet* 1986;1:1355-1357
 19. Matsumae M, Kikinis R, Morocz I, et al. Intracranial compartment volumes in patients with enlarged ventricles assessed by magnetic resonance-based image processing. *J Neurosurg* 1996;84:972-981
 20. Vanneste JA. Three decades of normal pressure hydrocephalus: are we wiser now? *J Neurol Neurosurg Psychiatry* 1994;57:1021-1025
 21. Hughes CP, Sigel BA, Cox WS, et al. Adult idiopathic communicating hydrocephalus with and without shunting. *J Neurol Neurosurg Psychiatry* 1978;41:961-971
 22. Fisher CM. Hydrocephalus as a cause of disturbances of gait in the elderly. *Neurology* 1982;32:1358-1363
 23. Matsumae M, Kikinis R, Morocz IA, et al. Age-related changes in intracranial compartment volumes in normal adults assessed by magnetic resonance imaging. *J Neurosurg* 1996;84:982-991
 24. Murphy DG, DeCarli C, Schapiro MB, Rapoport SI, Horwitz B. Age-related differences in volumes of subcortical nuclei, brain matter, and cerebrospinal fluid in healthy men as measured with magnetic resonance imaging. *Arch Neurol* 1992;49:839-845
 25. El Gammal T, Allen MB, Brooks BS, Mark EK. MR evaluation of hydrocephalus. *AJNR Am J Neuroradiol* 1987;8:591-597
 26. Mori E, Hirono N, Yamashita H, et al. Premorbid brain size as a determinant of reserve capacity against intellectual decline in Alzheimer's disease. *Am J Psychiatry* 1997;154:18-24
 27. Folstein MF, Folstein SE, McHugh PR. "Mini-Mental State": a practical method for grading the cognitive state of patients for the clinician. *J Psychiatr Res* 1975;12:189-198
 28. Mori E, Mitani Y, Yamadori A. Usefulness of Japanese version of the Mini-Mental State test in neurological patients. *Jpn J Neuropsychiatry* 1985;1:82-90
 29. Mohs RC, Rosen WG, Davis KL. The Alzheimer's disease assessment scale: an instrument for assessing treatment efficacy. *Psychopharmacol Bull* 1983;19:448-450
 30. Honma A, Fukuzawa K, Tsukada Y, Ishii T, Hasegawa K, Mohs RC. Development of a Japanese version of Alzheimer's Disease Assessment Scale (ADAS). *Jpn J Geriatr Psychiatry* 1992;3:647-655
 31. McKhann G, Drachman D, Folstein M, Katzman R, Price D, Stadlan EM. Clinical diagnosis of Alzheimer's disease: report of the NINCDS-ADRDA Work Group under the auspices of Department of Health and Human Services Task Force on Alzheimer's Disease. *Neurology* 1984;34:939-944
 32. Tucker GJ, Popkin M, Douglas EC, et al. Delirium, dementia, and amnesic and other cognitive disorders. In: Widiger TA, Frances AJ, Pincus HA, First MB, Ross R, Davis W, eds. *Diagnostic and Statistical Manual of Mental Disorders*. 4th ed. Washington, DC: American Psychiatric Association; 1994:133-146
 33. Davis PC, Gray L, Albert M, et al. The Consortium to Establish a Registry for Alzheimer's Disease (CERAD), III: reliability of a standardized MRI evaluation of Alzheimer's disease. *Neurology* 1992;42:1676-1680
 34. Kitagaki H, Mori E, Hirono N, et al. Alteration of white matter MRI signal intensity in frontotemporal dementia. *AJNR Am J Neuroradiol* 1997;18:367-378
 35. Mori E, Hirono N, Yamashita H, et al. Premorbid brain size as a determinant of reserve capacity against intellectual decline in Alzheimer's disease. *Am J Psychiatry* 1997;154:18-24
 36. Dunn OJ. Multiple comparisons using rank sums. *Technometrics* 1964;6:241-252
 37. Kobashi S, Kamiura N, Hata Y, Yamato K. 3D automatic extraction method of the brain regions aided by fuzzy matching techniques. In: Chen YY, Hirota K, Yen JY, eds. *Soft Computing*. Piscataway, NJ: Institute of Electrical and Electronics Engineers; 1996:164-169
 38. Kitagaki H, Mori E. MRI in dementias. *Jpn J Clin Psychiatry* 1997;26:709-719
 39. Benzel EC, Pelletier AI, Levy PG. Communicating hydrocephalus in adults: prediction of outcome after ventricular shunting procedures. *Neurosurgery* 1990;26:655-660
 40. Miller JD, Adams JH. The pathophysiology of raised intracranial pressure. In: Adams JH, DuChen LW, eds. *Greenfield's Neuropathology*. 5th ed. London: Edward Arnold; 1992:69-105
 41. Ekstedt J, Fridén H. CSF hydrodynamics for the study of the adult hydrocephalus syndrome. In: Shapiro K, Marmarou A, Portnoy H, eds. *Hydrocephalus*. New York: Raven Press; 1984:363-382
 42. Adams RD. Recent observations on normal pressure hydrocephalus. *Schweiz Arch Neurol Neurochir Psychiatry* 1975;116:7-15
 43. DeLand FH, James AE Jr, Ladd DJ, Konigsmark BW. Normal pressure hydrocephalus: a histologic study. *Am J Clin Pathol* 1972;58:58-63
 44. Vessal K, Sperber EE, James AE Jr. Chronic communicating hydrocephalus with normal CSF pressures: a cisternographic-pathologic correlation. *Ann Radiol (Paris)* 1974;17:785-793

Please see the Commentary on page 1285 in this issue.