



## Discover Generics

Cost-Effective CT & MRI Contrast Agents



FRESENIUS  
KABI

WATCH VIDEO

# AJNR

### **Abnormal origin of the vertebral artery from the common carotid artery.**

C J Chen, L J Wang and Y C Wong

*AJNR Am J Neuroradiol* 1998, 19 (8) 1414-1416

<http://www.ajnr.org/content/19/8/1414>

This information is current as  
of June 19, 2025.

# Abnormal Origin of the Vertebral Artery from the Common Carotid Artery

Chi-Jen Chen, Li-Jen Wang, and Yon-Cheong Wong

**Summary:** An abnormal origin of the vertebral artery from the common carotid artery (VA-CC) may occur on the right or left side with different embryonic mechanisms. We describe a patient with a double developmental anomaly, a right VA-CC and a right aortic arch. The rotation of the aortic arch caused a “twist” of the embryonic mechanisms of VA-CC and misdirected the differential diagnosis of the embryonic mechanisms at first glance. We discuss the pivotal points in differentiating the embryonic mechanisms of VA-CC.

An abnormal origin of the vertebral artery from the common carotid artery (VA-CC) is rare (1–9). It occurs on the right or left side with different embryonic mechanisms (1, 2). When it occurs on the right side, it is invariably associated with an ipsilateral aberrant right subclavian artery (right ASA) (3–8). We report a case of a right VA-CC with a contralateral aberrant left subclavian artery (left ASA) and a right aortic arch. The angiographic findings are presented and the embryonic mechanism of the anomaly is discussed.

## Case Report

A 50-year-old woman suffered sudden onset of left-sided weakness and numbness. A cranial CT scan revealed an infarct in the territory of the right middle cerebral artery. Her medical history included hypertension and cardiac arrhythmia under treatment.

A chest radiograph showed a right aortic arch. Sonographic examination of the neck vessels showed a possible right vertebral artery arising from the right common carotid artery. Aortograms and selective carotid studies showed a right aortic arch and a right vertebral artery arising from the right common carotid artery at the C6 level (Fig 1). Other findings included nonopacification of the left vertebral artery, a right subclavian artery originating from the aortic arch instead of from the innominate artery, and an origin of the left subclavian artery from the descending aorta distal to the origin of the right subclavian artery (ie, a left ASA) (Fig 1). Cerebral angiograms showed atherosclerotic changes at the intracranial vessels, possibly corresponding to the middle cerebral artery infarct.

## Discussion

The earliest development of the vertebral artery is apparent when the embryo is at the 7-mm stage; it is usually complete by the 14- to 17-mm stage (10). At the 7-mm stage, seven cervical intersegmental arteries (CIAs), which originate from each of the paired dorsal aortae, appear (10). At the 10- to 12-mm stage, a longitudinal anastomosis develops between the CIAs (10). At the 14- to 17-mm stage, the horizontal parts of the first six CIAs disappear and the remaining seventh CIA becomes part of the subclavian artery. The longitudinal anastomosis persists as the vertebral artery (10). These developmental processes result in a normal origin of the vertebral artery from the subclavian artery. Failure of involution in one of the first six CIAs (ie, a persistent CIA) causes a variety of abnormal origins of the vertebral artery (1, 2). If the persistent CIA occurs in the upper (first or second) intersegmental arteries, the result is an abnormal origin of the vertebral artery from the internal or external carotid artery (1, 2, 11); if it occurs in the lower (third through sixth) CIAs, the result is an abnormal origin of the vertebral artery from the aortic arch or the common carotid artery (1, 2, 11).

Two different embryonic mechanisms for VA-CC have been described (1–9). The first (type I) includes a persistent lower CIA and an involution of the ipsilateral middle dorsal aorta between the persistent CIA and the seventh CIA (2). The second (type II) also has a persistent lower CIA, but instead of an involution of the ipsilateral middle dorsal aorta, the persistent CIA migrates upward to the level of the common carotid artery (1, 2). In the type I anomaly, because of the persistent lower CIA, the vertebral artery comes in contact with the proximal dorsal aorta and fourth aortic arch, which in turn connects to the common carotid artery; and because of the involution of the ipsilateral middle dorsal aorta, the remaining ipsilateral seventh CIA connects to the contralateral dorsal aorta, which results in an ipsilateral ASA. The reported cases of right VA-CC belong to the type I anomaly, because they are all associated with an ipsilateral ASA (3–8). Why the type I anomaly does not occur on the left side can be explained as follows: in

Received March 20, 1997; accepted after revision September 8.

From the Department of Diagnostic Radiology, 2nd Division, Chang Gung Memorial Hospital, 199 Tung Hwa North Rd, Taipei, Taiwan. Address reprint requests to Chi-Jen Chen, MD.

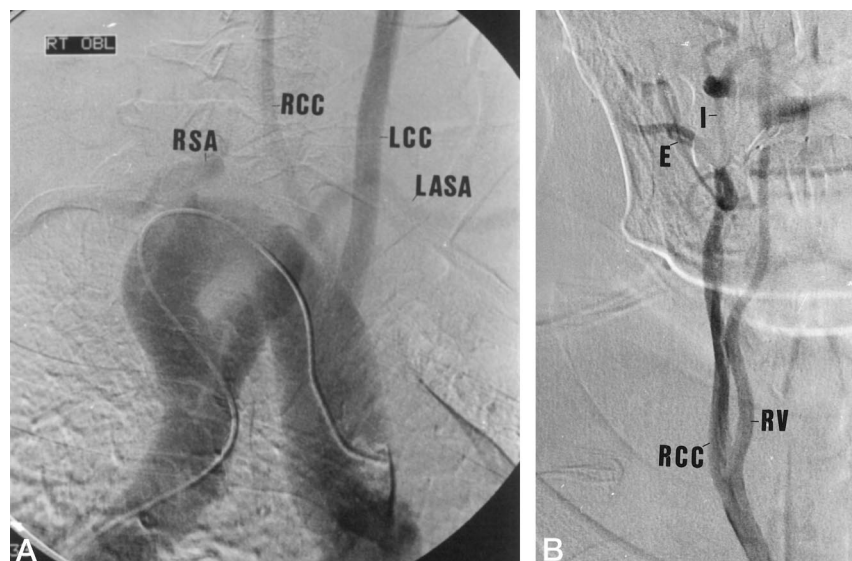


FIG 1. 50-year-old woman with sudden onset of left-sided weakness and numbness.

A and B, Aortogram in right anterior oblique position (A) and selective right common carotid arteriogram in anteroposterior position (B) show a right aortic arch and an aberrant left subclavian artery (LASA). The right subclavian artery (RSA) originates from the aortic arch instead of from the innominate artery. An abnormal origin of the right vertebral artery (RV) from the right common carotid artery (RCC) at the C6 level is noted. The left vertebral artery is not opacified. LCC = left common carotid artery; I = internal carotid artery; E = external carotid artery.

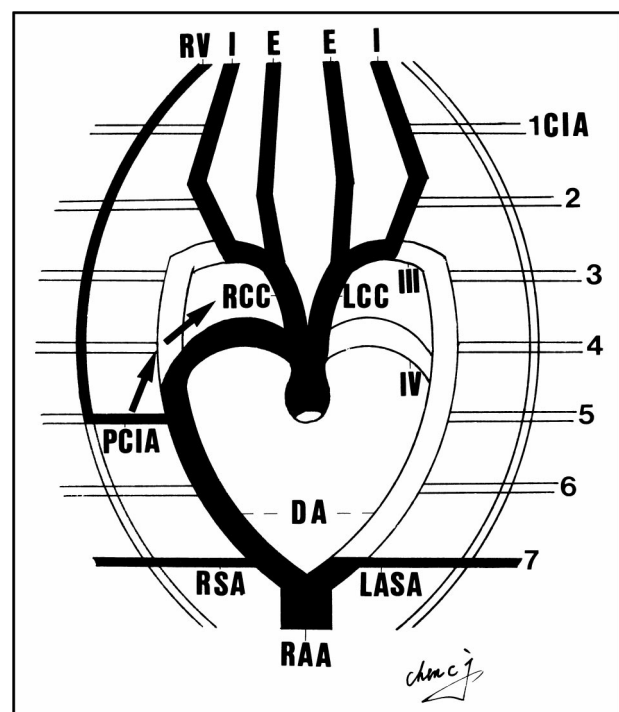


FIG 2. Schematic diagram shows the right vertebral artery (RV) arising from the right common carotid artery (RCC). This resulted from a persistent right lower cervical intersegmental artery (PCIA) with upward migration (arrows) to the level of the common carotid artery (type II anomaly). The aberrant left subclavian artery (LASA) is associated with the right-sided aortic arch (RAA), owing to an involution of the left dorsal aorta proximal to the seventh cervical intersegmental artery (CIA). I = internal carotid artery; E = external carotid artery; III = third aortic arch; IV = fourth aortic arch; DA = dorsal aortae; LCC = left common carotid artery; RSA = right subclavian artery (modified from [2]).

the development of a normal (ie, a left) aortic arch, there is involution of the right dorsal aorta distal to the seventh CIA. If the type I anomaly occurs on the left side with an involution of the left middle dorsal aorta and the usual involution of the right side, both sides of the dorsal aortae are interrupted. This con-

dition is incompatible with life. In the type II anomaly, because of the upward migration of the persistent CIA, the vertebral artery, which at first connects to the proximal dorsal aorta, is now in contact with the common carotid artery; and because of failure of involution of the ipsilateral middle dorsal aorta, no ipsilateral ASA is formed. The reported cases of left VA-CC (3, 9) belong to the type II anomaly, because no ipsilateral ASA was noted. However, we still do not know why it occurs only on the left side.

Our patient had double developmental anomalies, a right VA-CC and a right aortic arch. The embryonic mechanism of the right VA-CC belonged to the type II anomaly, because no ipsilateral (ie, a right) ASA was noted (Fig 2). The contralateral left ASA was unrelated to the type I or II anomaly, but it was related to the right aortic arch. With a right aortic arch, there is a segmental involution of the left dorsal aorta. If this segmental involution occurs proximal to the left seventh CIA, a left ASA will develop (Fig 2). Therefore, our case, although it looked like a type I anomaly at first glance, was actually a type II anomaly with a "twist" (ie, it occurred at the right side) because of a rotation of the aortic arch.

## Conclusion

From our case we learn that VA-CC anomalies can still be differentiated by the existence of an ipsilateral ASA and explained on the basis of the simple type I and type II schemata used in the past. However, we should be aware of the possibility of a superimposed anomaly of the involuted dorsal aorta in type II anatomy, which could result in a contralateral ASA.

## References

1. Lie TA. Congenital malformations of the carotid and vertebral arterial systems, including persistent anastomoses. In: Vinken PJ, Bruyn GW, eds. *Handbook of Clinical Neurology, 12: Vascular Diseases of the Nervous System, Part II*. Amsterdam: North-Holland; 1972: 289-339

2. Houghton VM, Rosenbaum AE. **The normal and anomalous aortic arch and brachiocephalic arteries.** In: Newton TH, Potts DG, eds. *Radiology of the Skull and Brain, Book 2.* St Louis: Mosby; 1974;2: 1145–1163
3. Quain R. *The Anatomy of the Arteries of the Human Body.* London: Taylor & Walton; 1844
4. Kemmetmüller H. **Ueber eine seltene Varietät der Art. vertebralis.** *Anat Heft Wiesb* 1911;44:305–363
5. Poynter CWM. **Arterial anomalies pertaining to the aortic arches and the branches arising from them.** *Nebr Univ Studies* 1916;16: 229–345
6. Goldbloom AA. **The anomalous right subclavian and its possible clinical significance.** *Surg Gynecol Obstet* 1922;34:378–384
7. Iyer AA. **Some anomalies of the origin of the vertebral artery.** *J Anat* 1927;62:121–122
8. Windle WF, Zeiss FR, Adamski MS. **Note on a case of anomalous right vertebral and subclavian arteries.** *J Anat* 1928;62:512–514
9. Hyrtl J. **Einige in chirurgischer Hinsicht wichtige Gefäßvarietäten.** *Med. Jb-r Öst. Staates* 1841;24:17–38
10. Newton TH, Mani RL. **The vertebral artery.** In: Newton TH, Potts DG. *Radiology of the Skull and Brain, Book 2.* St Louis: Mosby; 1974;2:1659–1709
11. Keller HM, Imhof HG, Valavanis A. **Persistent cervical intersegmental artery as a cause of recurrence of a traumatic carotid-cavernous fistula: case report, with emphasis on Doppler ultrasound diagnosis.** *Neurosurgery* 1982;10:492–498