

## Get Clarity On Generics

Cost-Effective CT & MRI Contrast Agents



FRESENIUS  
KABI

WATCH VIDEO

# AJNR

## Osseous anatomy of the pterygopalatine fossa.

D L Daniels, L P Mark, J L Ulmer, M F Mafee, J McDaniel,  
N C Shah, S Erickson, L A Sether and S S Jaradeh

*AJNR Am J Neuroradiol* 1998, 19 (8) 1423-1432

<http://www.ajnr.org/content/19/8/1423.citation>

This information is current as  
of August 13, 2025.

## Osseous Anatomy of the Pterygopalatine Fossa

David L. Daniels, Leighton P. Mark, John L. Ulmer, Mahmood F. Mafee, Jim McDaniel,  
Nirav C. Shah, Scott Erickson, Lowell A. Sether, and Safwan S. Jaradeh

The pterygopalatine fossa (PPF) represents a major pathway of spread of malignancy and infection from the head and neck into the skull base. The ability to precisely locate tumor and infection on CT and MR imaging studies is crucial for performing biopsies and planning treatment.

Determining the exact margins of the PPF is problematic, because they are not strictly defined even in the anatomic literature. The obliquely oriented upper part of the perpendicular plate of the palatine bone and the pterygoid process form a small pyramidal-shaped fossa that probably was called the PPF because it contains the pterygopalatine ganglion (1) (Fig 1B and C). However, axial CT studies define a larger fossa, which incorporates the pyramidal-shaped fossa and has its posterolateral margin at the lateral edges of the base of the pterygoid process and the fused pterygoid plates (Fig 1C and D). By conventional usage and in this article, this larger fossa is designated the PPF (2).

The PPF is bounded posteriorly by the fused pterygoid plates and the base (root) of the sphenoid bone, medially and more superiorly anteromedially by the palatine bone, and anteriorly by the maxillary bone (2–10) (Figs 2–5). When viewed laterally, the PPF appears as a narrow and inferiorly tapering space contiguous with the more anteriorly positioned inferior orbital fissure and formed by the gap between the curving margins of the maxillary and sphenoid bones (Fig 2A and C). This gap is bridged inferiorly and medially by the palatine bone.

The palatine bone has a unique configuration made up of different parts that enable it to fuse anteriorly with the maxillary bone and posteriorly and superiorly with the sphenoid bone. The palatine bone has a shape like a right angle when viewed frontally, owing to its horizontal and perpendicular plates (Fig 4B). The horizontal plates of each palatine bone unite in the midline to form the posterior third of the hard palate, which fuses with the palatine processes of the maxillary bones to form the complete hard palate (Fig 6C). The perpendicular plate fuses anteriorly with the rough posterior surface of the medial wall of the maxillary bone, thus covering part of the maxillary hiatus of the maxillary sinus. Posteriorly, the perpen-

dicular plate is variably contoured and fuses with the medial surface of the medial pterygoid plate (Fig 3). At the upper part of the perpendicular plate, processes are present that fuse with the maxillary and sphenoid bones. The orbital process extends superolaterally to attach to the posterior margin of the orbital surface of the maxillary bone and partly to the inferior surface of the body of the sphenoid bone (Figs 3A and B, and 5B and C). The sphenoidal process extends superomedially to attach to the base of the medial pterygoid plate (Figs 3A and B, and 4B and E). At the junction of the perpendicular and horizontal plates, the pyramidal process attaches to the maxillary bone and extends posterolaterally to attach to the angled inferior margins of the pterygoid plates (Figs 2A; 4B, C, and E; and 5B and C).

The sphenoid bone also has a unique configuration. The pterygoid process of the sphenoid bone, positioned inferior to the body and greater wing, consists of the base and the medial and lateral pterygoid plates (Fig 4B). The anterior surface of the base forms a shallow recess whose medial margin follows the curve of the medial pterygoid plate (Fig 4C). This recess forms most of the posterior wall of the PPF and contains the anterior openings of the foramen rotundum superiorly and the vidian (pterygoid) canal medially (Fig 4C). More inferiorly, the separated pterygoid plates attach to the pyramidal process of the palatine bone (Fig 4C and E).

Tumor and infection can extend through the PPF via the orbital apex, the inferior orbital fissure, the foramen rotundum (which allows access to the cavernous sinus), the vidian canal (leading to the foramen lacerum), the pterygomaxillary fissure (which communicates with the masticator space), the greater and lesser palatine canals and foramina, and the sphenopalatine foramen (providing access to the posterosuperior part of the nasal fossa). The pterygomaxillary fissure, the lateral opening of the PPF, has a well-defined posterior margin formed superiorly by the lateral margin of the anterior surface of the base of the pterygoid process and inferiorly by the fused pterygoid plates, and a not as well-defined anterior margin, owing to the curving contour of the posterior wall of the maxillary sinus (Fig 2C). The greater

---

From the Departments of Radiology (D.L.D., L.P.M., J.L.U., J.M., N.C.S., S.E.), Cellular Biology and Anatomy (L.A.S.), and Neurology (S.S.J.), Medical College of Wisconsin, Milwaukee; and the MRI Center, University of Illinois at Chicago (M.F.M.).

Address reprint requests to David L. Daniels, MD, Department of Radiology, Medical College of Wisconsin, Froedtert Memorial Lutheran Hospital, 9200 W Wisconsin Ave, Milwaukee, WI 53226.

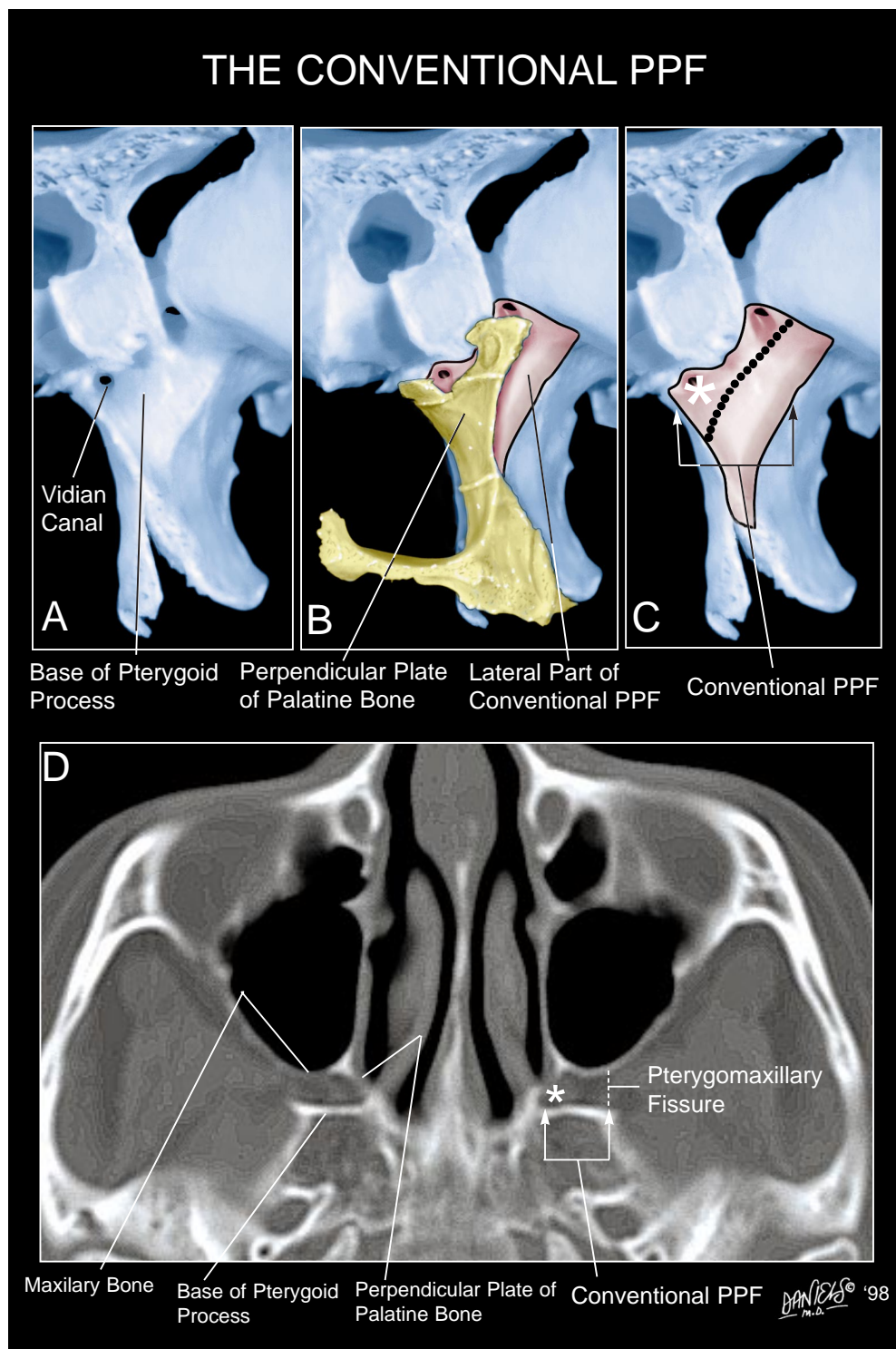


FIG 1. Frontal views (A–C) and axial CT scan (D) through the pterygoid process.

*B*, The palatine bone is in position and with the pterygoid process forms a small fossa that is hidden in this view.

*C*, The palatine bone has been removed to show this small fossa (*asterisk*) that was probably called the PPF because it contains the pterygopalatine ganglion (*not shown*), which overlies the vidian canal, shown in *A*. However, by conventional usage, a larger fossa incorporating the small fossa and extending to the lateral edge of the base of the pterygoid process (as shown in *B*, *C*, and *D*) is designated the PPF.

*D*, At this level, the margins of the PPF (consisting of the maxillary bone, angled upper part of the perpendicular plate of the palatine bone, and base of the pterygoid process) are shown with the latter two forming the small fossa. Also evident and by conventional usage is the lateral opening of the PPF, the pterygomaxillary fissure (*dotted line*).

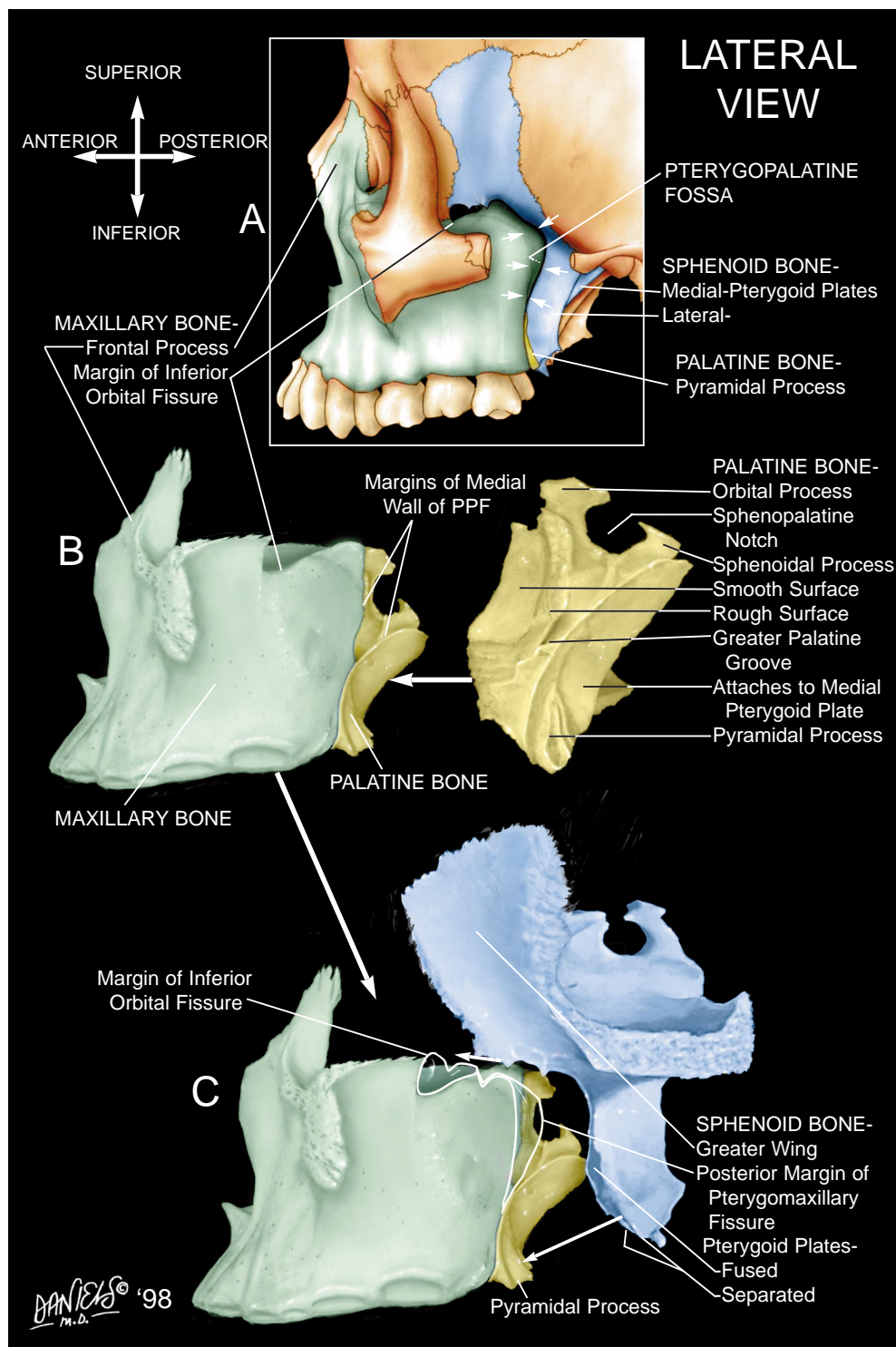


FIG 2. Lateral views of the sphenoid, palatine, and maxillary bones.

A, Shown in the intact skull is the curving gap between the sphenoid and maxillary bones, consisting of the PPF and its lateral opening, the pterygomaxillary fissure (arrows) and the more anteriorly positioned inferior orbital fissure.

B, To form the anterior margin of the medial wall of the PPF, the rough surface of the palatine bone is shown attaching to the posteromedial surface of the maxillary bone. More inferiorly, the anterior surface of the pyramidal process of the palatine bone attaches to the maxillary bone. The medial wall of the PPF tapers inferiorly.

C, Completing the PPF, the medial surface of the medial pterygoid plate attaches to the most posterior part of the perpendicular plate of the palatine bone. More inferiorly, the pyramidal process fuses with the angled inferior margins of the pterygoid plates. The pterygomaxillary fissure is formed anteriorly by the maxillary bone, posteriorly by the lateral edge of the base of the pterygoid process, and inferiorly by the fused pterygoid plates. The margins of the pterygomaxillary and inferior orbital fissures are shown in white.



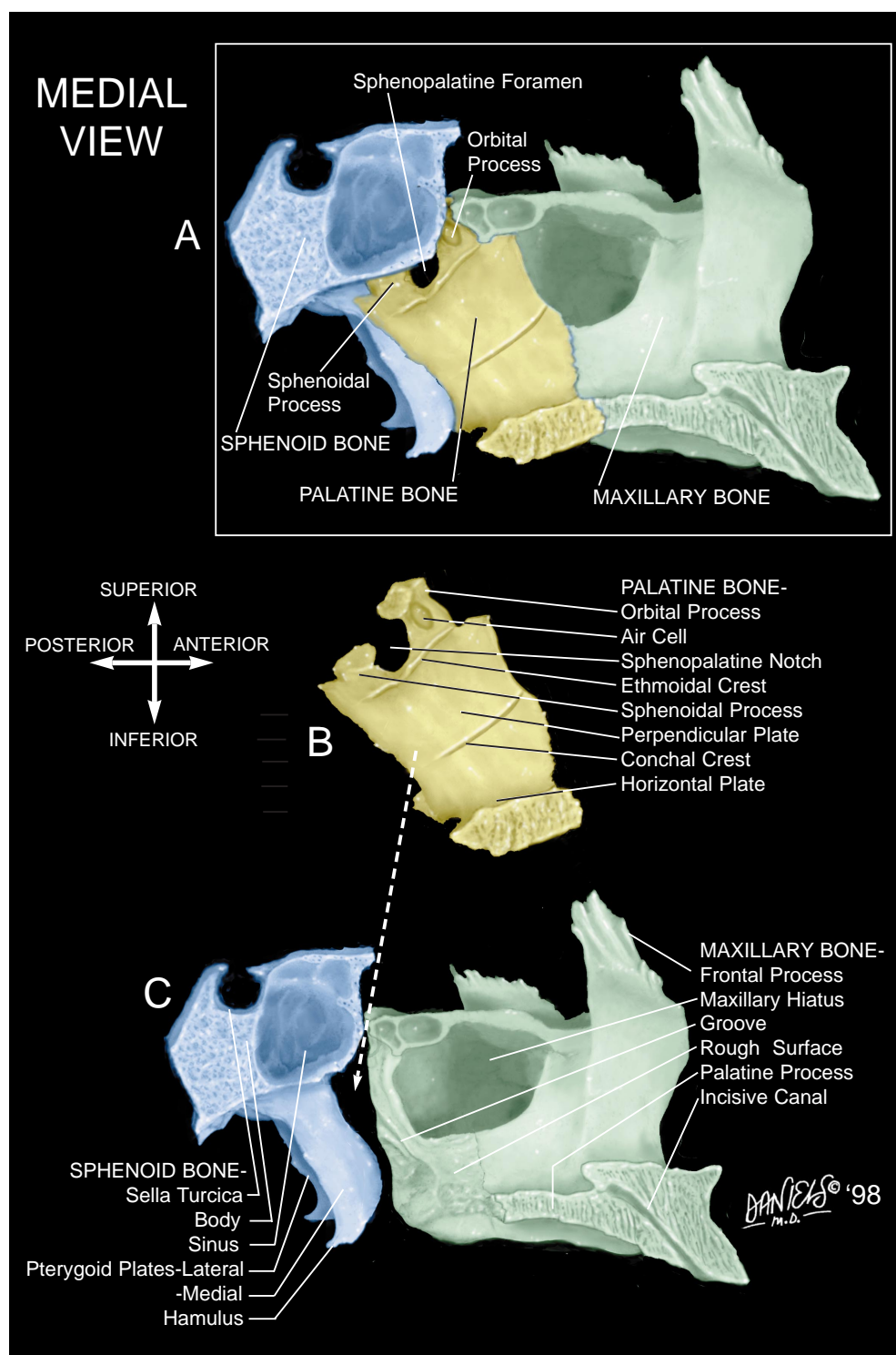


FIG 3. Medial views of the sphenoid (*shown in part*), palatine, and maxillary bones.

A, Overview of the lateral wall of the nasal fossa.

B, The conchal crest on the medial surface of the palatine bone is contiguous with the inferior turbinate (*not shown*) and may be identified on coronal CT scans to locate the palatine bone (see Fig 7D). Also shown is the sphenopalatine notch margined by the orbital and sphenoidal processes. It forms the sphenopalatine foramen when closed by the sphenoid bone (see Fig 7D).

C, To bridge the gap between the sphenoid and palatine bones, the perpendicular plate of the palatine bone attaches to the anterior part of the medial surface of the medial pterygoid plate and the posterior rough surface of the medial wall of the maxillary bone covering the posterior part of the maxillary hiatus. Shown is the groove at the posteroinferior aspect of the medial wall of the maxillary bone that forms part of the wall of the greater palatine canal.

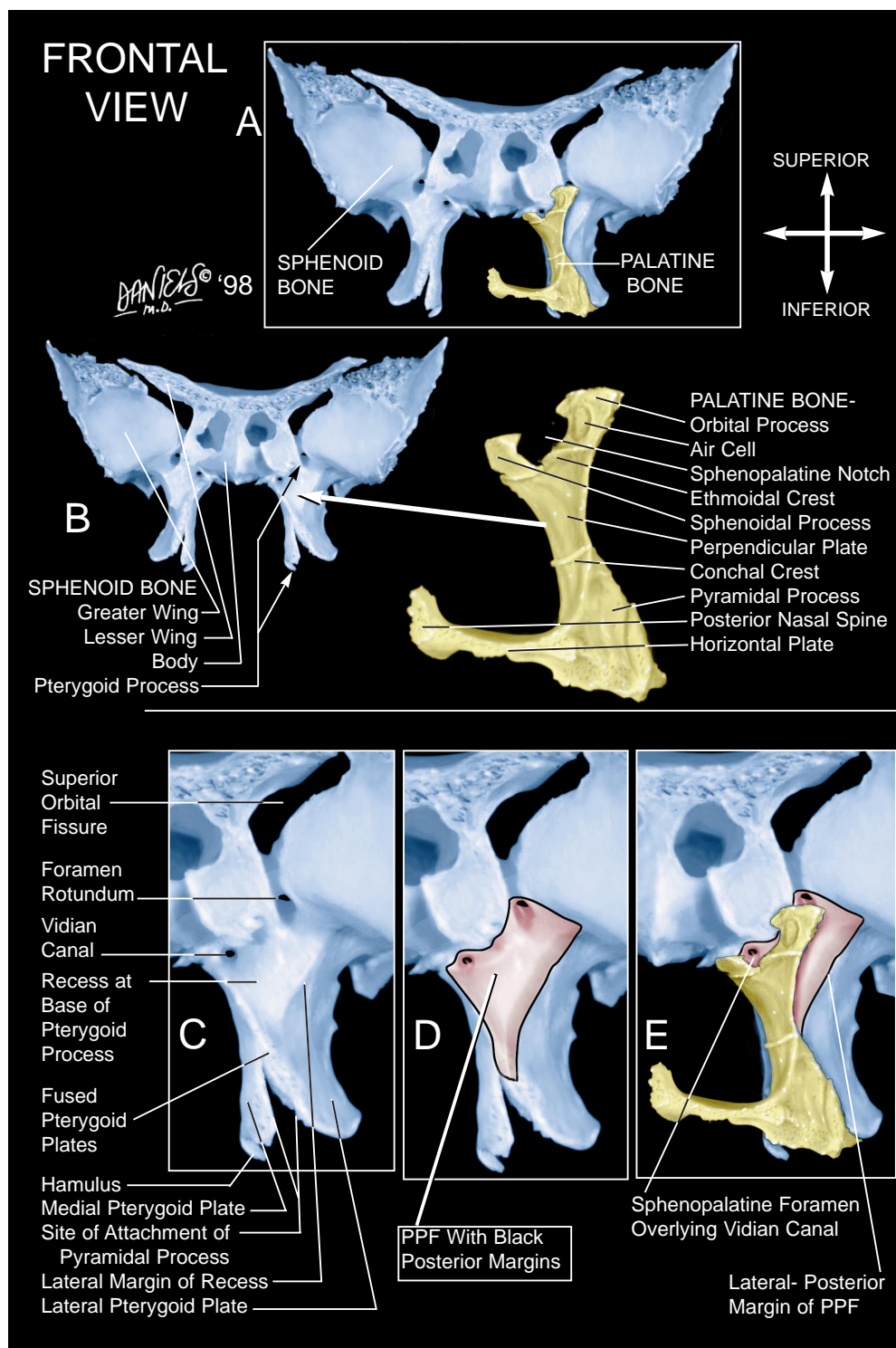


FIG 4. Frontal views of the sphenoid and palatine bones.

A, Overview of the palatine bone attached to the pterygoid process and inferior aspect of the body of the sphenoid bone.

B, The palatine bone is shaped like a right angle, owing to its horizontal and perpendicular plates (see also Fig 7E). The pyramidal process arises at the junction of these plates and extends posterolaterally between the inferior margins of the pterygoid plates.

C, Magnified view of the pterygoid process shows the shallow recess at the base of the sphenoid bone. It is deeper medially, forms most of the posterior wall of the PPF, and contains the openings of the foramen rotundum and the more inferomedially positioned vidian canal.

D, The posterior margins of the PPF correspond to the margins of the recess at the base of the sphenoid bone and taper inferiorly.

E, With the palatine bone in place, note the angled configuration of the upper part of the perpendicular plate, the orbital and sphenoidal processes, and the sphenopalatine foramen. The sphenopalatine foramen is shown overlying the vidian canal, a relationship that can be seen on axial CT scans (see Fig 8B and B'). The PPF extends lateral to the upper part of the perpendicular plate of the palatine bone.

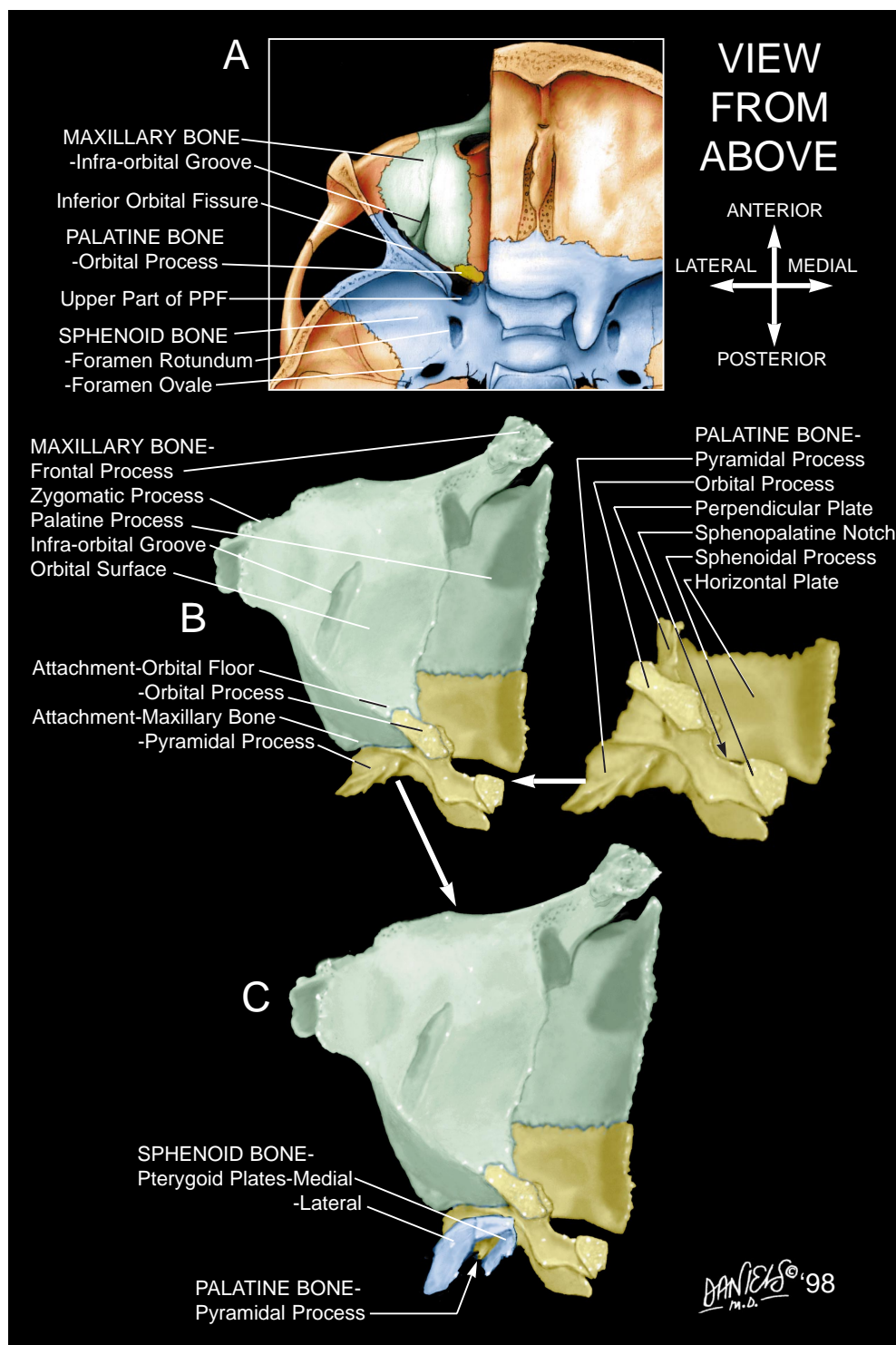


FIG 5. Views from above the maxillary, palatine, and sphenoid bones.

A, Overview of the orbital floor, which is formed primarily by the maxillary bone.

B, The horizontal plate and pyramidal process of the palatine bone are shown attaching to the maxillary bone. The orbital process of the palatine bone attaches to the posterior margin of the orbital surface of the maxillary bone. The upper part of the perpendicular plate and sphenopalatine foramen have angled contours that can be identified on axial CT scans (see Fig 8B' and C).

C, The pterygoid plates of the sphenoid bone attach to the pyramidal process of the palatine bone.

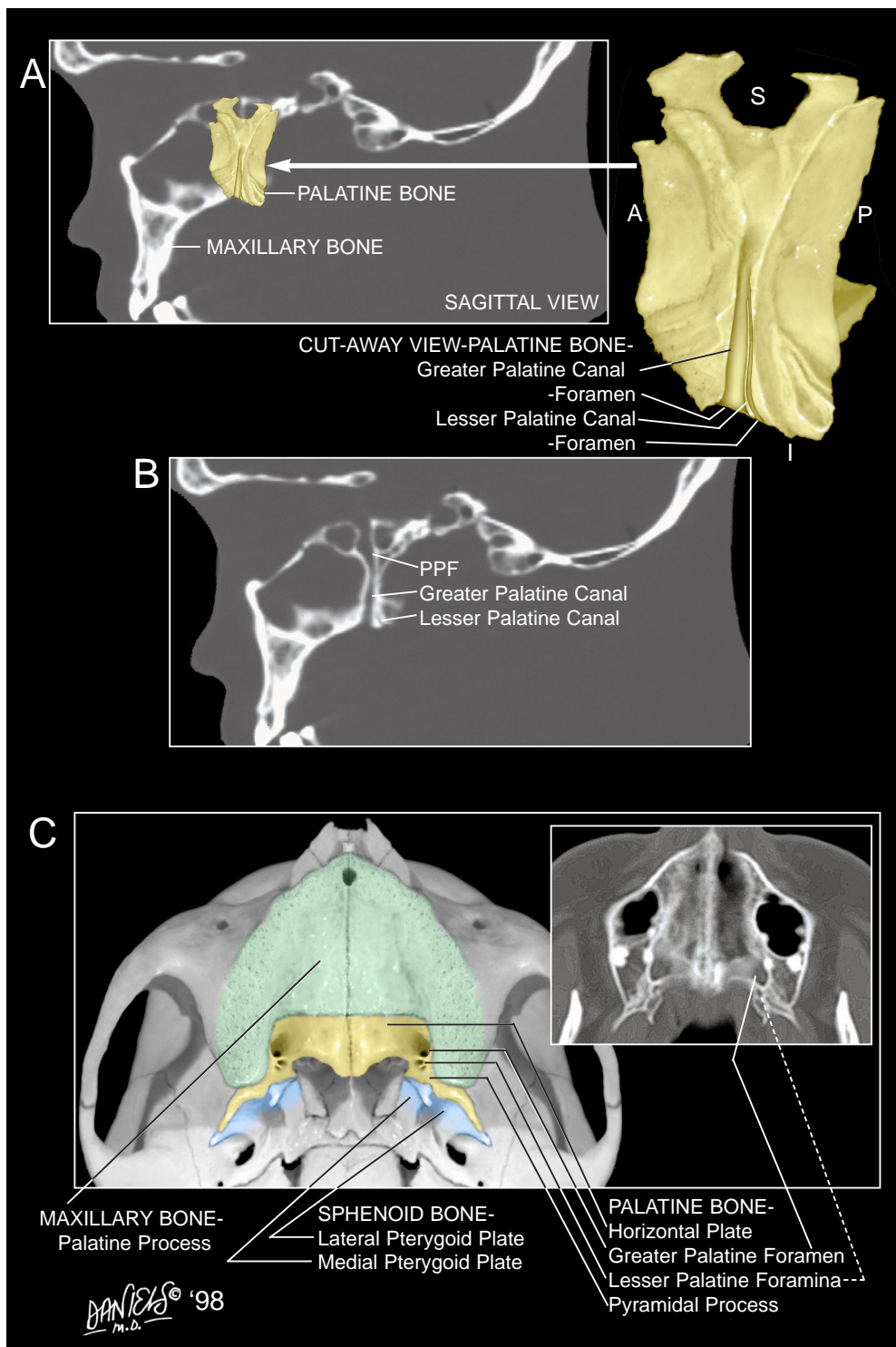


FIG 6. Views of the palatine canals and foramina.

A, The greater and lesser palatine canals and foramina are shown in a cutaway view of the palatine bone, which is positioned on a sagittally reformatted CT scan of the skull base.

B, On sagittal reformatted CT scan, the PPF and greater palatine canal have nearly straight posterior margins. The lesser palatine canal is slightly posterior, has a slightly curving configuration, and extends through the pyramidal process of the palatine bone.

C, View of the hard palate from below and a corresponding axial CT scan show the greater palatine foramen at the lateral margin of the horizontal plate of the palatine bone and, slightly more posteriorly, the lesser palatine foramina in the pyramidal process. More than one lesser palatine canal may be present. These foramina permit spread of malignancy from the palate into the cavernous sinus.



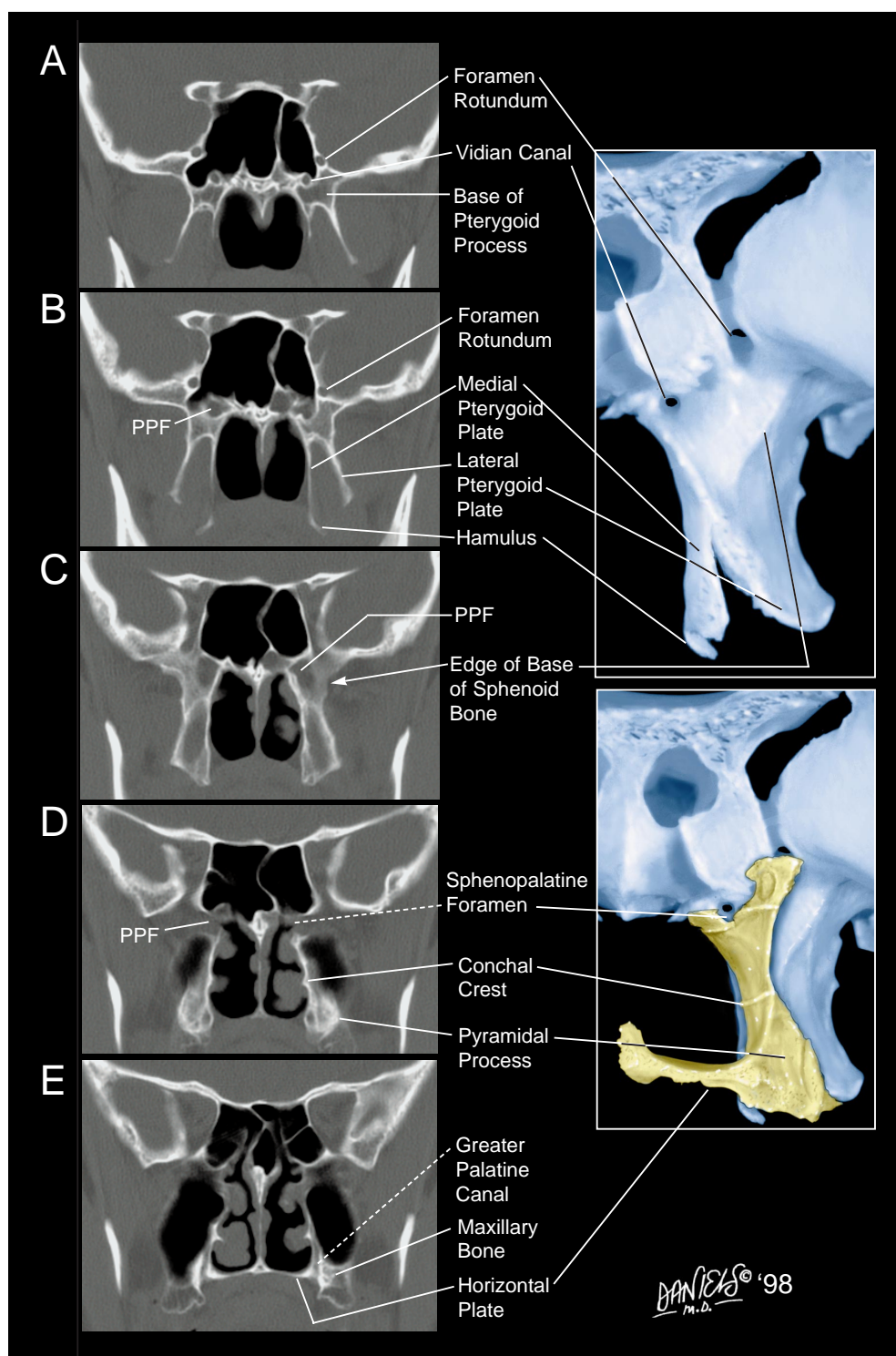


FIG 7. Coronal CT scans show osseous anatomy of the structures marginating the PPF posteriorly to anteriorly and referenced to inserts in Figure 4.

A, The foramen rotundum and, more inferomedially, the vidian (pterygoid) canal are identified in the sphenoid bone.

B, The superomedial part of the PPF.

C, The PPF is identified with partial volume averaging of the edge of the base of the sphenoid bone. The angular shape of the PPF can vary slightly depending on the coronal plane of section.

D, The conchal crest is a landmark that identifies the perpendicular plate of the palatine bone. Also shown is the pyramidal process, which can have a somewhat globular or sometimes triangular configuration between the inferior margins of the pterygoid plates. More superiorly, the sphenopalatine foramen appears as a small opening between the inferior surface of the sphenoid body and the upper part of the perpendicular plate, through which the PPF communicates with the nasal fossa.

E, The greater palatine canal is formed by the junction of grooves in the maxillary and palatine bones.

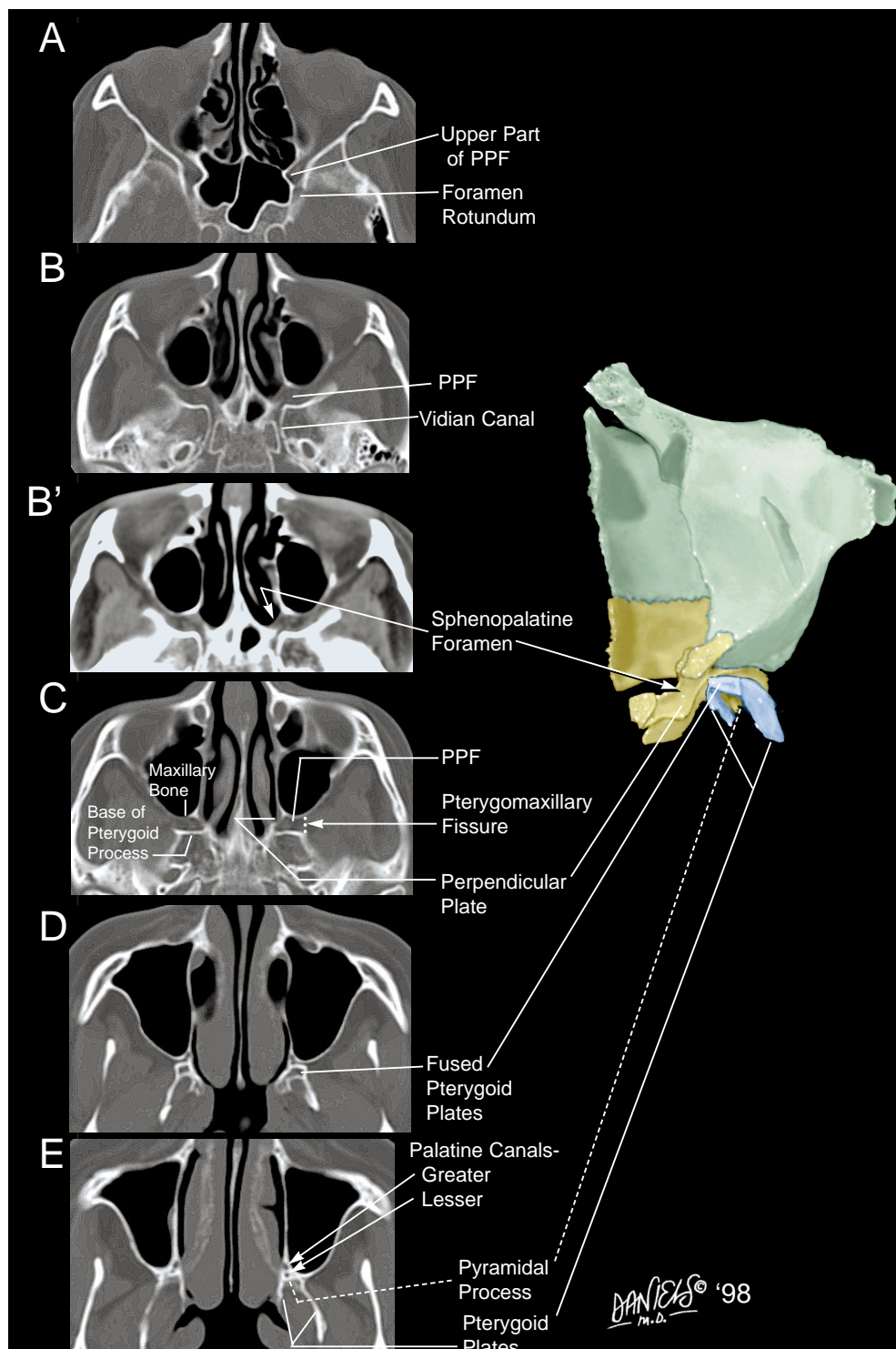


FIG 8. Axial CT scans show osseous anatomy of the structures marginating the PPF, obtained superiorly to inferiorly, referenced to Figure 5C.

A, The foramen rotundum is shown communicating with the upper part of the PPF.

B and B', The same CT scan through the upper part of the PPF shown at bone (B) and soft-tissue (B') windows. Evident is the angled opening of the sphenopalatine foramen, located just anterior to the vidian canal opening.

C, The PPF, the angled upper part of the perpendicular plate of the palatine bone, and the pterygomaxillary fissure (dotted line).

D, The fused pterygoid plates at the level of the inferior part of the PPF.

E, The greater and lesser palatine canals. The exact margins between the pyramidal process and pterygoid plates are difficult to identify.

palatine canal is formed by the apposition of an obliquely descending groove at the posteroinferior aspect of the medial wall of the maxillary bone and the greater palatine groove deep to the lateral surface of the perpendicular plate of the palatine bone (Figs 3C and 6A). This canal opens inferiorly at the greater palatine foramen located at the lateral margin of the horizontal plate (Fig 6C). The lesser palatine canal(s) extend through the pyramidal process of the palatine bone to open at the lesser palatine foramina at the anterior aspect of the inferior surface of the pyramidal process (Fig 6C). The sphenopalatine foramen forms when the sphenopalatine notch between the orbital and sphenoidal processes is closed by the anteroinferior margin of the body of the sphenoid bone (Figs 3A and B, and 4E). The sphenopalatine foramen, the orbital and sphenoidal processes, and the upper part of the perpendicular plate form an acute angle with the anterior surface of the sphenoid bone such that the sphenopalatine foramen can be recognized on CT scans by its angled contour and location just anterior to the vidian canal (Figs 4E, 5B and 5C, 7D, and 8B and B').

The osseous structures that form the PPF provide recognizable anatomic landmarks by which to identify the margins of the PPF and its openings on CT scans (Figs 7 and 8).

A subsequent Anatomic Moment will highlight the nerves and blood vessels related to the PPF.

### Acknowledgments

We thank Hugh D. Curtin, Leo F. Czervionke, Anton N. Hasso, and Wendy R. K. Smoker for their help in preparing this article.

### References

1. Waddington MM. *Atlas of the Human Skull*. Rutland, VT: Sharp Offset Printing; 1981:98, 99, 106
2. Osborn AG. **The pterygopalatine (sphenomaxillary) fossa**. In: Bergeron RT, Osborn AG, Som PM, eds. *Head and Neck Imaging*. St Louis: Mosby; 1984:172-185
3. Daniels DL, Mark LP, Mafee MF, et al. **Osseous anatomy of the orbital apex**. *AJNR Am J Neuroradiol* 1995;16:1929-1935
4. Anderson JE. *Grant's Atlas of Anatomy*. Baltimore: Williams & Wilkins; 1978
5. Daniels DL, Pech P, Kay MC, et al. **Orbital apex: correlative anatomic and CT study**. *AJNR Am J Neuroradiol* 1985;6:705-710
6. Daniels DL, Rauschnig W, Lovas J, et al. **Pterygopalatine fossa: computed tomographic studies**. *Radiology* 1983;149:511-516
7. Daniels DL, Yu S, Pech P, Haughton VM. **Computed tomography and magnetic resonance imaging of the orbital apex**. *Radiol Clin North Am* 1987;25:803-817
8. Williams PL, Warwick R, Dyson M, Bannister LH, eds. *Gray's Anatomy*. 35th ed. London: Churchill Livingstone; 1989
9. Zide BM, Jelks GW. *Surgical Anatomy of the Orbit*. New York: Raven Press; 1985
10. Rouviere H. In: Delmas A, ed. *Anatomie Humaine*. Paris: Masson; 1970