



Discover Generics

Cost-Effective CT & MRI Contrast Agents



WATCH VIDEO

AJNR

Superior blowout fracture of the orbit: the blowup fracture.

M I Rothman, E M Simon, G H Zoarski and M T Zagardo

AJNR Am J Neuroradiol 1998, 19 (8) 1448-1449

<http://www.ajnr.org/content/19/8/1448>

This information is current as
of June 18, 2025.

Superior Blowout Fracture of the Orbit: The Blowup Fracture

Michael I. Rothman, Erin M. Simon, Gregg H. Zoarski, and Michael T. Zagardo

Summary: We describe a patient who sustained a blowout fracture of the superior orbital roof without an orbital rim fracture. The initial CT study (obtained with 10-mm-thick sections) did not show herniation of the intraorbital fat into the anterior cranial fossa; however, thin (3-mm-thick) direct orbital sections showed a fracture of the midportion of the superomedial orbital roof with displacement of the fracture fragment into the anterior cranial fossa.

Blowout fractures occur when direct blunt force is applied to the globe and orbit. Disruption of the bony orbital wall allows for decompression, typically sparing the orbital rim (pure blowout fracture) (1). Isolated blowin fractures of the superior orbital roof, inferior orbital floor, medial orbital wall, and lateral orbital wall have also been described, but are much less common (2–5). Curtin et al (6) described two cases of superior orbital blowout fractures on conventional tomography, but did not employ CT in the diagnosis. We present the CT findings associated with a rare fracture of the superior orbital roof without orbital rim fracture: the superior blowout, or blowup, fracture.

Case Report

A 44-year-old man who was a street pugilist was admitted to the emergency department with multiple facial contusions after losing an altercation. The patient reported no visual disturbance or double vision. Soft-tissue swelling, ecchymosis, and tenderness was present over the face and orbits, but no bony defects were palpated over the orbital rim. On ophthalmologic examination, the globe position was normal and symmetric, visual fields were intact, and extraocular motion was full. Facial sensation was also intact. A CT scan of the brain obtained at contiguous 10-mm increments showed circumscribed low density in the anterior cranial fossa interpreted as pneumocephalus (Fig 1A), without other observed bony or intracranial injury. Further imaging was performed to locate the source of the intracranial air.

Coronal CT of the orbit performed at 3-mm increments revealed a fracture of the midportion of the superomedial orbital roof with displacement of the fracture fragment superiorly into the anterior cranial fossa (Fig 1B and C). The superior orbital rim, superior orbital fissure, optic canal, and frontal sinus were intact. Herniation of intraorbital, extraconal fat (density measurement showed –95 HU) through the defect

was noted. Also seen was a concurrent medial blowout fracture with medial tenting of the medial rectus muscle. No clinical evidence of entrapment or CSF leak was noted on examination.

The patient was taken to the operating room, where an anterior cranial fossa extradural approach was used to explore the bony defect and remove the herniated extraorbital fat and bone fragments. Pericranium was then placed over the defect to assure successful fixation and stabilization of the orbital roof.

Discussion

Blowout fractures occur when an object striking the orbit is slightly larger than the orbit itself, resulting in diffuse transmission of increased pressure through the globe and orbital structures that is relieved by a fracture of one of the orbital walls, typically sparing the orbital rim (1). Fractures of the floor are more common than fractures of the medial wall and lamina papyracea. Isolated fractures of the orbital roof are uncommonly seen in the absence of a fracture of the superior orbital rim (7). Isolated roof fractures are more common in the presence of a well-pneumatized orbital roof, and have a better prognosis when the orbital rim is spared (8).

Our patient experienced the typical mechanism for a blowout fracture. He was struck with fists to the orbit and face and incurred significant soft-tissue swelling and diffuse ecchymosis. The insult resulted in an unusual blowout fracture of the orbital roof in addition to the much more common medial fracture. It is not clear why the superior orbital wall was vulnerable to injury in our patient, especially since the orbital roof was not pneumatized. Prior reports of blowin fractures have suggested that the direction of the force vector may be responsible for these fracture patterns (2–5). We speculate that the force vector experienced by our patient may have been directed superiorly and medially; alternatively, it may be that the superior and medial orbital walls are the areas of thinnest bone, and thus greatest relative weakness, in our patient.

We believe that the herniation of intraorbital fat into the anterior cranial fossa was not appreciated on the initial CT scan of the brain owing to the relatively thick (10-mm) sections and resultant partial volume

Received September 2, 1997; accepted after revision December 12.

From the Department of Diagnostic Radiology, University of Maryland Medical Systems, 22 S Greene St, Baltimore, MD 21201. Address reprint requests to Michael Rothman, MD.

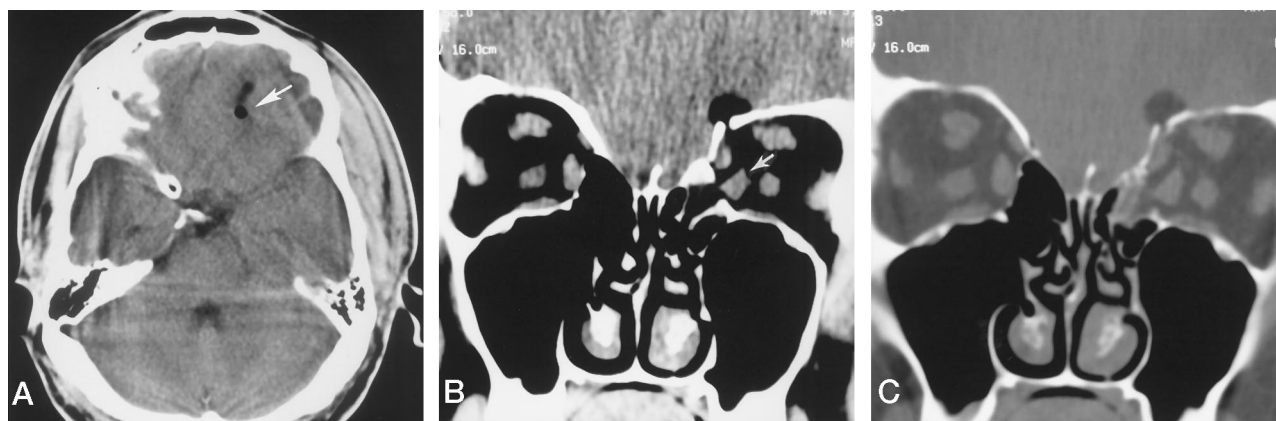


FIG 1. 44-year-old man with multiple facial contusions.

A, Axial CT scan of the brain at a level just superior to the orbit shows mixed low-density and very low-density material (arrow) in the anterior cranial fossa.

B and C, Coronal CT scans of the orbit at soft-tissue (B) and bone (C) windows show a superiorly displaced fracture fragment of the left orbital roof with herniation of intraorbital fat into the anterior cranial fossa, as well as a medial blowout fracture. Note altered shape of the medial rectus muscle (arrow).

averaging of the herniated fat, superjacent brain, and subjacent bony orbital roof. The use of thin-section direct coronal CT to examine the orbits prior to planned surgical intervention allowed for separation and correct identification of the herniated fat and better delineation of the site, location, and size of the displaced fracture fragment as well as of the concurrent medial orbital blowout fracture.

Conclusion

Although unusual, superior blowout fractures of the orbit do occur, and may be associated with herniation of intraorbital contents into the cranial vault and/or sinuses. The relatively thick CT sections used to examine the brain in trauma patients are often insufficient to detect orbital fractures or to distinguish intracranial fat from air; thus, thin-section imaging in the coronal plane may be appropriate in certain cases to identify fracture sites and their associated complications.

Acknowledgments

We gratefully acknowledge the assistance of Dave Crandall for his excellent photographic technique, Sue Mosteller for her

invaluable reference assistance, and Amiel Bethel for his neurosurgical knowledge and expertise.

References

1. Smith B, Regan WF. **Blowout fracture of the orbit: mechanism and correction of internal orbital fracture.** *Am J Ophthalmol* 1957;44:733-739
2. Sato O, Kamitani H, Kokunai T. **Blow-in fracture of both orbital roofs caused by shear strain to the skull.** *J Neurosurg* 1978;49:734-738
3. Chirico PA, Mirvis SE, Kelman SE, Karesh JW. **Orbital "blow-in" fractures: clinical and CT features.** *J Comput Assist Tomogr* 1989;13:1017-1022
4. Zizmor J, Noyek AM. **Orbital trauma.** In: Newton TH, Potts DG, eds. *Radiology of the Skull and Brain.* Book 2. St Louis: Mosby; 1971;1:541-558
5. Linz AM. **Blow-in fracture of the lateral wall of the orbit.** *Trans Int Conf Oral Surg* 1973;4:306-307
6. Curtin HD, Wolfe P, Schramm V. **Orbital roof blow-out fractures.** *AJNR Am J Neuroradiol* 1982;3:531-534
7. Converse JM, Smith B, Obear MF, Wood-Smith D. **Orbital blowout fractures: a ten year survey.** *Plast Reconstr Surg* 1967;39:20-36
8. Mancuso AA, Hanafey WN. **Facial trauma.** In: *Computed Tomography and Magnetic Resonance Imaging of the Head and Neck.* 2nd ed. Baltimore: Williams & Wilkins; 1985:chap 3