



Get Clarity On Generics

Cost-Effective CT & MRI Contrast Agents



FRESENIUS
KABI

WATCH VIDEO

AJNR

An unusual cause of otalgia.

S Coley, A Clifton and J Britton

AJNR Am J Neuroradiol 1998, 19 (8) 1452-1453

<http://www.ajnr.org/content/19/8/1452.citation>

This information is current as
of August 11, 2025.

LETTER

An Unusual Cause of Otagia

We read Dr. Weissman's special report, *A Pain in the Ear: the Radiology of Otagia*, in the October, 1997 issue of the *AJNR* with considerable interest (1). Giant aneurysm of the petrous internal carotid artery was omitted from this excellent article, presumably for the sake of brevity. We do, however, believe it is worthy of mention, despite its rarity, due to the significance of missing the diagnosis prior to operation.

We recently encountered a 15-year-old boy who complained of progressive "ear ache" and deafness over a 3-month period (2). Clinical examination revealed almost complete unilateral hearing loss, an ipsilateral ptosis and a middle ear effusion. CT of the petrous bone demonstrated an avidly enhancing mass centered on the left petrous carotid canal (Figure 1A). The canal was markedly expanded and the lesion extended into the petrous apex, middle ear cavity and middle cranial fossa. The anatomic location of the lesion, with its complex MR signal characteristics that were predominantly high T1- and mixed amorphous T2-signal, suggested the presence of flowing blood and thrombus within an enlarged internal carotid artery (ICA) (Figure 1B). The mastoid air cells and middle ear cavity were fluid-filled as a result of the eustachian tube obstruction (Figure 1B). MR angiography and percutaneous arteriography (Figure 1C) confirmed the presence of a giant fusiform aneurysm of the entire petrous segment of the left ICA. The lesion was treated the following day by deploying two detachable silicone balloons at the proximal end of the aneurysm. Within 48 hours the patient's pain had dramatically improved, but the Horner's persisted.

Giant fusiform petrous aneurysms are a rare but well-recognized cause of unilateral headache/otalgia, nerve palsy (VIII, VI, VII and V cranial nerves) and hemorrhage (3). The lesion may remain undetected for several years, and the headache is often misdiagnosed as migraine. Whether branches of the glossopharyngeal nerve (Jacobson's nerve) or fibers of the sympathetic plexus surrounding the internal carotid artery are responsible for the pain is debatable (1). This patient presented with a Horner's syndrome, and since sympathetic fibers are known to join Jacobson's nerve in the tympanic plexus of the middle ear (4), stimulation of these autonomic fibers may have been the cause of, or at least contributed to, this patient's otalgia. Interestingly, and rather surprisingly, only one previous case of Horner's syndrome has been reported with a giant petrous aneurysm (5).

Although a rare cause, an aneurysm of the petrous carotid should be considered in the differential diagnosis of otalgia, particularly as they may have complex MR appearances that may be misinterpreted with potentially fatal consequences. In our case, neuroradiologic intervention resulted in symptomatic relief.

STUART COLEY, MRCP FRCR
ANDREW CLIFTON, MRCP FRCR
JULIET BRITTON, MRCP FRCR
Department of Neuroradiology
Atkinson Morley's Hospital
London, U.K.

References

1. Weissman JL. A pain in the ear: the radiology of otalgia. *AJNR* 1997;18:1641-1651
2. Coley SC, Clifton A, Britton J. Diagnosis and endovascular treatment of an unusual cause of otalgia and Horner's syndrome: Giant aneurysm of the petrous internal carotid artery. *J Laryngol Otol*
3. Halbach VV, Higashida RRT, Hieshima GB, Dowd CF, Barnwell

SL, Edwards MSB, Melicharck M. Aneurysms of the petrous portion of the internal carotid artery: results of treatment with endovascular or surgical occlusion. *AJNR* 1990;11:253-257

4. Wazen JJ. Referred otalgia. *Otolaryngol Clin North Am* 1989;22:1205-1215
5. Wemple JB, Smith GW. Extracranial carotid aneurysm. *J Neurosurg* 1966;24:667-671

Reply

Dr. Coley and colleagues are quite generous. I am flattered to think that they believe I omitted mention of a giant petrous carotid artery aneurysm (or any other entity) from my article on otalgia (1) for the sake of brevity. In fact, I am firmly convinced that "brevity" and "the radiology of otalgia" are mutually exclusive concepts. It would be more appropriate to omit giant aneurysms from the list of causes of otalgia for the sake of frequency (or lack thereof).

A giant aneurysm of the petrous carotid artery may be a pain in the neck to the clinicians caring for these patients, but it is unlikely to be a cause of pain in the ear for the vast majority of the patients. Dr. Coley and colleagues consider a giant aneurysm of the petrous carotid artery to be a "rare but well-recognized" cause of otalgia (and of other symptoms). I completely agree with "rare," but question "well-recognized." Of the approximately two dozen reports of this entity I have either read (2-6) or found referenced (2), the vast majority are case reports. Most of these case reports use the word "rare" or "uncommon" (2-6), many in the first paragraph. All the authors and all the readers of these case reports do not add up to enough cognoscenti to qualify giant petrous carotid aneurysms for the status of a "well-recognized" cause of otalgia—and with good reason.

Very few reports implicate petrous carotid aneurysms as a cause of otalgia. Headache, tic douloureux, and pain (location unspecified) are described, but I believe that it is not justifiable to assume that any of these are otalgia. This may be a problem of how authors define otalgia, compounded by patient vagueness. Some patients with giant aneurysms are children (2), from whom an accurate description of the pain may be difficult to elicit. The reference Dr. Coley and colleagues cite in their letter, substantiating their description of giant aneurysms as a "well-recognized cause of unilateral headache/otalgia . . ." (2), does not mention otalgia.

Dr. Coley and colleagues believe that giant aneurysm should be included in the differential diagnosis of otalgia. Do they mean the clinical or radiographic diagnosis? In my opinion, a giant aneurysm belongs on a list of clinical differential diagnoses of otalgia (at the bottom of the list) only if having it there spurs a clinician to scan the patient. Giant aneurysm is a radiologic, not a clinical, diagnosis.

Why do giant aneurysms cause ear pain? To Dr. Coley's list of potential mechanisms, I would add pressure on the bone surrounding the aneurysm, and obstruction of the eustachian tube leading to a middle ear effusion (3). Dr. Coley's patient had a mastoid and middle ear effusion, nicely shown on the T2-weighted MR image. It would be interesting to investigate the correlation between ear pain and the presence of a middle ear effusion in patients with giant aneurysms of the petrous carotid artery.

In summary, a giant aneurysm of the petrous carotid artery is a rare abnormality, and ear pain is a rare symptom of this rare abnormality. Together, these two facts make giant petrous carotid aneurysms a vanishingly rare cause of otalgia. While I thoroughly agree that "missing the diagnosis prior to operation" could have dreadful consequences, I also believe that this

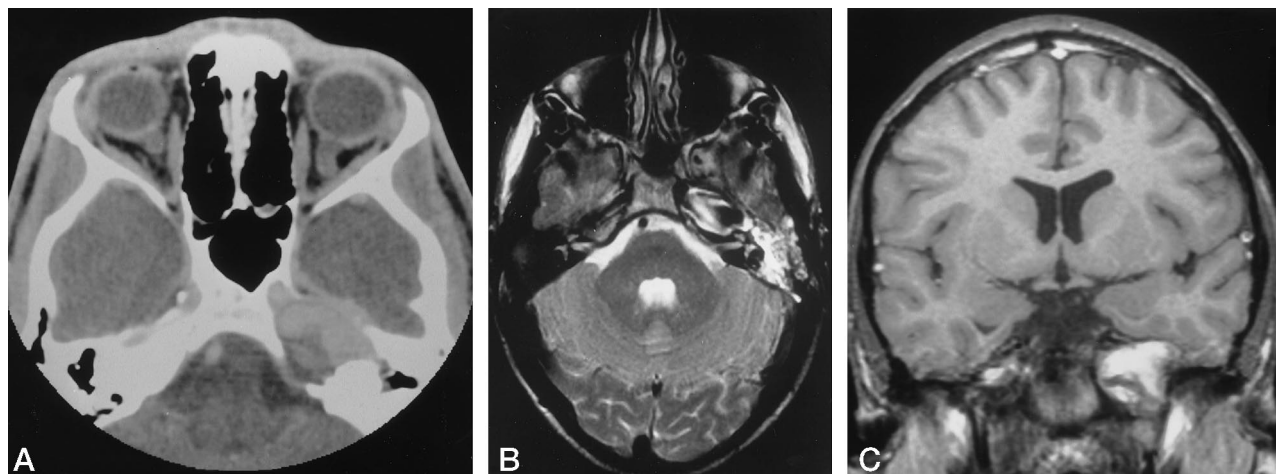


FIG 1. Giant fusiform aneurysm of the petrous segment of the internal carotid artery.

A, CT of the petrous bone demonstrates expansion of the entire length of the (L) petrous carotid canal by an avidly enhancing mass, which has eroded into the middle cranial fossa.

B, Axial T-2 weighted MR (TR2413ms, TE 120ms) at the level of the internal auditory canals depicts the petrous carotid aneurysm as an expansile fusiform structure of mixed signal which is predominately hypointense with areas of amorphous peripheral high signal. The mastoid air cells and middle ear cavity are fluid-filled due to obstruction of the Eustachian tube.

C, Percutaneous transcatheter arteriogram confirms the presence of a giant fusiform aneurysm of the petrous segment of the left ICA.

scenario is highly unlikely in the evaluation of a patient with otalgia. I do, however, thank the authors for bringing again to our attention this unusual and important entity. It is good to be reminded of other causes of petrous apex masses.

JANE L. WEISSMAN, M.D.
Associate Professor of Radiology and Otolaryngology
Director of Head and Neck Imaging
University of Pittsburgh Medical Center
Pittsburgh, PA

References

1. Weissman JL. A pain in the ear: The radiology of otalgia. *AJNR Am J Neuroradiol* 1997;18:1641-1651
2. Halbach VV, Higashida RT, Hieshima GB, Dowd CF, Barnwell SL, Edwards MSB, Melcharek M. Aneurysms of the petrous portion of the internal carotid artery: Results of treatment with endovascular or surgical occlusion. *AJNR Am J Neuroradiol* 1990;11:253-257
3. Willinsky R, Lasjaunias P, Pruvost P, Boucherat M. Petrous internal carotid aneurysm causing epistaxis: Balloon embolization with preservation of the parent vessel. *Neuroradiol* 1987;29:570-572
4. Goodman TR, Renowden S, Byrne JV. Case report: Petrous internal carotid artery aneurysm: An unusual cause of eustachian tube dysfunction. *Clin Radiol* 1996;51:658-660
5. Frank E, Brown BM, Wilson DF. Asymptomatic fusiform aneurysm of the petrous carotid artery in a patient with von Recklinghausen's neurofibromatosis. *Surg Neurol* 1989;32:75-78
6. Umez H, Seki Y, Aiba T, Kumakawa K. Aneurysm arising from the petrous portion of the internal carotid artery: Case report. *Radiation Med* 1993;11:251-255