



Get Clarity On Generics

Cost-Effective CT & MRI Contrast Agents



FRESENIUS
KABI

WATCH VIDEO

AJNR

Follow-up study after intracranial percutaneous transluminal cerebral balloon angioplasty.

T Mori, M Fukuoka, K Kazita and K Mori

AJNR Am J Neuroradiol 1998, 19 (8) 1525-1533

<http://www.ajnr.org/content/19/8/1525>

This information is current as
of August 18, 2025.

Follow-up Study after Intracranial Percutaneous Transluminal Cerebral Balloon Angioplasty

Takahisa Mori, Masaaki Fukuoka, Ken Kazita, and Koreaki Mori

BACKGROUND AND PURPOSE: Our objective was to find the specific angiographic characteristics of atherosclerotic lesions that indicate suitability for intracranial percutaneous transluminal cerebral balloon angioplasty (PTCBA).

METHODS: Forty-two clinically symptomatic patients with 42 hemodynamically significant intracranial lesions (>70% stenosis) were treated by PTCBA between January 1992 and May 1996. Before treatment, the patients were assigned to three groups according to the angiographic characteristics of the lesions, as follows: type A, short (5 mm or less in length) concentric or moderately eccentric lesions less than totally occlusive; type B, tubular (5 to 10 mm in length), extremely eccentric or totally occluded lesions, less than 3 months old; and type C, diffuse (more than 10 mm in length), extremely angulated (>90°) lesions with excessive tortuosity of the proximal segment, or totally occluded lesions, and 3 months old or older. The patients were followed up for a period of 1 month to 6 years to compare the results of PTCBA treatment among the three groups. Primary end points were death, stroke, or bypass surgery.

RESULTS: The clinical success rates for the type A, B, and C groups were 92%, 86%, and 33%, respectively. Cumulative risks of fatal or nonfatal ischemic stroke or ipsilateral bypass surgery in type A, B, and C groups were 8%, 26%, and 87%, respectively. The cumulative risk of 8% among patients in the type A group appeared to be smaller than in studies reported in the literature.

CONCLUSION: PTCBA for intracranial simple (type A) lesions yields a favorable clinical outcome for symptomatic patients.

The Ministry of Health and Welfare in Japan has reported that the incidence of mortality following ischemic strokes, intracerebral hemorrhage, and subarachnoid hemorrhage in Kochi prefecture during 1995 was 115.2, 38.6, and 12.0, respectively, per 100,000 population. The main cause of cerebrovascular death was ischemic stroke, and its mortality rate remains high in Kochi prefecture. Pharmacologic treatment of ischemic stroke is underway (1); however, such treatment is sometimes ineffective in patients suffering recurrent or crescendo neurologic symptoms caused by high-grade stenosis or occlusion of the intracranial arteries, and it has not been proved that medical therapy can effectively prevent future strokes in patients who have experienced a transient neurologic deficit or minor stroke arising from an intracranial lesion. This is of major concern, as arterial stenotic lesions seem to occur more frequently, intracranially, in Japanese people (2). Revasculariza-

tion to the coronary artery by bypass surgery has been shown to be effective in reducing symptoms and in improving clinical outcome of patients with stable angina pectoris (3). In contrast, extracranial/intracranial (EC/IC) arterial bypass surgery has not yet been proved effective (4), and a high complication rate can be anticipated, particularly for the posterior cerebral circulation (5). During the past 30 years, percutaneous transluminal angioplasty (PTA) has been shown to be of value in decreasing ischemic symptoms and in improving perfusion to the coronary artery and other peripheral vessels. However, it has not been until the last few years that results of treatment by percutaneous transluminal cerebral balloon angioplasty (PTCBA) of the intracranial artery have been reported (6–8). In general, transluminal dilatation of small and fragile intracranial arteries appears to be more dangerous than that of the extracranial, coronary, or other peripheral arteries. A previous investigation revealed that a short, concentric or mildly eccentric, and nonangulated intracranial arterial stenosis may be suitable for initial or repeated treatment by PTCBA (9). In the present study, therefore, our goal was to assess the safety and efficacy of initial and elective PTCBA for atherosclerotic lesions, to inves-

Received February 17, 1998; accepted after revision May 22.

From the Department of Neurosurgery, Kochi Medical School Hospital, Kohasu, Okou-tyo, Nankoku City, Kochi 783–8505, Japan. Address reprint requests to Takahisa Mori, MD, PhD.

tigate the clinical outcome in patients treated by this technique, and, finally, to determine the subgroup of lesions most amenable to PTCBA treatment from among the three groups classified according to their angiographic characteristics prior to PTCBA therapy.

Methods

Clinically symptomatic patients with atherosclerotic lesions underwent PTCBA, and their clinical course was followed for a period of 1 month to 6 years. All patients gave informed written consent for PTCBA treatment and follow-up examinations. Inclusion criteria for the study were 1) hemodynamically significant stenosis ($>70\%$) of one of the following major intracranial vessels: the distal internal carotid artery (ICA), the middle cerebral artery (MCA), the distal vertebral artery (VA), the basilar artery (BA), and the posterior cerebral artery (PCA); 2) recurrent or crescendo transient ischemic attacks (TIAs) unresponsive to maximal medical therapy, or a minor stroke with persistence of signs or symptoms in the distribution of the stenotic artery; and 3) presence of symptoms within 6 months of treatment. Exclusion criteria were as follows: 1) patients who had had prior intracranial PTCBA; 2) patients in the acute stage of stroke; 3) patients with a severe neurologic deficit from a major stroke; 4) patients with total occlusion of more than 6 months' duration; 5) patients with chronic total occlusion of a segment greater than 10 mm in length, and 6) patients with chronic total occlusion without a visible distal segment on angiograms.

A total of 61 consecutive PTCBA procedures involving the intracranial artery were performed in 61 patients between January 1992 and May 1996 in our institution. PTCBA was not attempted in patients with exclusion criteria 3) through 6) above. Twelve patients who had had prior intracranial PTCBA and seven patients who had had PTCBA in the acute stage of stroke were excluded from further analysis, because restenosis or total occlusion in the acute stage of stroke does not always arise from atherosclerotic lesions, and this can lead to different clinical and angiographic outcomes. In all, 42 patients, 33 men and nine women, 4 to 76 years old (mean age, 59 ± 13 years) were included in the study. Lesions involved the distal ICA in eight patients, the MCA in 21 patients, the distal VA in six patients, the BA in five patients, and the PCA in two patients. Twelve patients (among them, seven MCAs, one distal VA, and four BAs) had recurrent or crescendo TIAs, the other 30 patients had a nondisabling stroke with persistence of signs or symptoms. Before PTCBA, the patients underwent a complete neurologic examination, routine laboratory testing, and head CT or MR imaging to examine the cerebral lesions. Although two patients, a 4-year-old boy and a 26-year-old man, had stenosis resulting from an unknown origin (10), the other 40 patients, all older than 40 years, had atherosclerotic stenosis. Among 29 patients with lesions in the anterior cerebral circulation, 22 patients without crescendo TIAs underwent brain single-photon emission CT (SPECT) before and after acetazolamide challenge (11–14), which demonstrated low perfusion or impaired vasodilatory capacity in the affected territory prior to PTCBA. Because emergency SPECT has not been performed in our institution, patients with impending stroke did not undergo SPECT, owing to time limitations.

Traditional arteriosclerotic risk factors were assessed on admission (Table 1) and treated with medication when considered clinically appropriate. All patients, except the 4-year-old boy, received 81 to 162 mg of aspirin per day for approximately 1 week before and after PTCBA.

The degree of stenosis was calculated by neurosurgeons, as is customary in Japan, on angiograms before and immediately after PTCBA and at follow-up examinations by using the North American Symptomatic Carotid Endarterectomy Trial (NASCET) criteria (15), which compares the diameter at the site of greatest narrowing with the diameter of a normal artery

distal to the lesion. Angiographic success of PTCBA was defined as a reduction in the diameter of the stenosis to less than 50% after dilatation, and clinical success was defined as angiographic success with no major complications, such as in-hospital mortality, stroke, or emergency EC/IC bypass surgery. Neurologic symptoms during balloon inflation were not regarded as complications.

Anticipation of the likelihood of a successful outcome is required before performing PTCBA. The cerebral angiographic classification, formulated on the basis of the one devised for coronary arteries prior to coronary angioplasty (16) and described elsewhere (9), delineates the length and geometry of lesions as follows: type A, short (5 mm or less in length) concentric or moderately eccentric lesions less than totally occlusive; type B, tubular (5 to 10 mm in length) extremely eccentric or totally occluded lesions, less than 3 months old; and type C, diffuse lesions (more than 10 mm in length), extremely angulated ($>90^\circ$) lesions with excessive tortuosity of the proximal segment or totally occluded lesions, 3 months old or older.

Every patient, except the 4-year-old boy, underwent PTCBA under local anaesthesia via a femoral arterial route. Low-molecular-weight dextran (1000 to 2000 mL/day) was started 1 hour before PTCBA and continued until the next day. Heparin (10,000 U) was injected intravenously to avoid thrombus formation during the procedure, and isosorbide dinitrate (2.5 to 5.0 mg) was injected into a target vessel through a guiding catheter to prevent balloon catheter-induced vasospasm. The endovascular surgeon, who was trained in the technique of microballoon angioplasty at an interventional cardiology center, performed every procedure with the neurosurgeons. A guidewire was navigated across the stenosis and advanced into the distal segment. The balloon catheter was guided over the wire and then inflated twice to the nominal pressure for 60 seconds.

Before PTCBA, patients were assessed neurologically. Afterward, they were monitored every month at an outpatient clinic, where neurologic status was examined by the neurosurgeon. Patients in whom dilatation was clinically successful underwent arteriographic follow-up 3 and 12 months later (9, 17, 18). The 3-month follow-up studies were defined as those performed between 8 and 16 weeks after PTCBA, and the 1-year follow-up studies as those performed between 42 and 62 weeks. Angiographic restenosis was defined as 50% or greater diameter stenosis at the follow-up examination. When symptoms caused by restenosis or new lesions occurred, or when SPECT scans showed impairment of vascular reserve, EC/IC bypass surgery or PTCBA was performed. When patients with restenosis underwent repeat PTCBA, follow-up angiography was performed after 3 months and again at 1 year.

The primary end point was determined by the occurrence of death, ipsilateral stroke, or ipsilateral bypass surgery. Because repeatability is one of the benefits of PTCBA, a repeat procedure was not included as one of the primary end points. The end point of death during the follow-up period included death from any cause. Stroke was defined as any neurologic deficit, including transient symptoms resolving completely within 24 hours. Ipsilateral bypass surgery was defined as EC/IC arterial bypass for the lesion previously treated by PTCBA. Repeat PTCBA was defined as a repeat percutaneous intervention involving the previously treated lesion after the initial procedure. The primary angiographic end point was the minimal luminal diameter at follow-up. Secondary end points included the angiographic success rate, the clinical success rate, and the rate of restenosis.

The main clinical analysis consisted of a comparison of the three groups classified according to the angiographic characteristics of the lesions with respect to the primary clinical end point. Continuous variables, expressed as mean ± 1 SD, were compared by analysis of variance (ANOVA). Categorical data were compared by using the Fisher exact test, and ordinal

TABLE 1: Baseline angiographic characteristics of the three groups of lesions

	Group			P Value
	Type A (n = 12)	Type B (n = 21)	Type C (n = 9)	
Patients				
Age (y)	59 ± 10	60 ± 11	57 ± 22	.88
Sex				
Male	10	16	7	.89
Female	2	5	2	
Lesions				
DICA	2	5	1	.86
MCA	5	9	7	
DVA	2	3	1	
BA	1	4	0	
PCA	2	0	0	
Stenosis	12	15	4	.01
Total occlusion	0	6	5	
SBP (mm Hg)	147 ± 14	151 ± 19	132 ± 22	.04
DBP (mm Hg)	84 ± 8	84 ± 9	73 ± 13	.02
FBS (mg/dL)	92 ± 16	99 ± 35	93 ± 13	.71
T-CHO (mg/dL)	169 ± 38	162 ± 37	182 ± 25	.36
TG (mg/dL)	142 ± 70	130 ± 81	131 ± 65	.91
HDL (mg/dL)	40 ± 10	40 ± 10	42 ± 12	.90
UA (mg/dL)	6.4 ± 1.8	5.4 ± 2.1	5.8 ± 1.7	.45
History				
Hypertension	9	15	3	.09
Diabetes mellitus	3	4	3	.70
Hyper-CHO (>220 mg/dL)	6	3	2	.08
Hyper-TG (>150 mg/dL)	4	4	2	.65
Hypo-HDL (<35 mg/dL)	5	4	3	.37
Angina pectoris	2	4	0	.39
Old myocardial infarction	2	2	0	.45
Cigarette smoking	8	14	6	.95
Prior STA-MCA bypass surgery	1	2	0	
Prior CEA	0	1	0	
History tumor treatment				
Malignant	0	2	1	
Benign	0	1	0	

Note.—Plus-minus values are mean ± SD; SBP indicates systolic blood pressure; DBP, diastolic blood pressure; FBS, fast blood sugar; T-CHO, total cholesterol; TG, triglyceride; HDL, high-density lipoprotein; UA, uric acid; STA-MCA, superficial temporal artery–middle cerebral artery; CEA, carotid endarterectomy; DIC, distal internal carotid artery; MCA, middle cerebral artery; DVA, distal vertebral artery; BA, basilar artery; PCA, posterior cerebral artery.

scales by the Kruskal-Wallis H test. Survival (hazard) probability was calculated by the life table method of Kaplan and Meier, and survival curves were compared by using the log-rank test. After the ANOVA comparisons, between-group comparisons were made using the Bonferroni-Dunn method. A probability of less than $P = .05$ was considered statistically significant. The SPSS advanced statistics 6.1 program was used for survival (hazard) probability and the log-rank test, and StatView 4.5 statistics software was used for the ANOVA and nonparametric tests.

Results

Before angioplasty, the endovascular surgeon and the neurosurgeon classified patients into three groups on the basis of the angiographic characteristics of the lesions; that is, into the type A group ($n = 12$), the type B group ($n = 21$), and the type C group ($n = 9$), as described above. There were no differences in baseline characteristics, except blood pressure, among the three groups (Table 1), although, by def-

inition, there were many instances of total occlusion in the type B and C groups ($P = .017$).

The clinical success rates for type A, B, and C lesions were 92% (11/12), 86% (18/21), and 33% (3/9), respectively ($P = .0032$, Kruskal-Wallis H test) and there were significant differences between the type A and C groups ($P = .0021$, Bonferroni-Dunn) and between the type B and C groups ($P = .0023$, Bonferroni-Dunn). Therefore, successful procedures were related to the angiographic characteristics of the lesions before PTCBA. Overall angiographic and clinical success rates were 79% (33/42) and 76% (32/42), respectively. In 10 patients, treatment was not clinically successful owing to two major complications (one in the type A group and one in the type C group), three lesions (two in type B and one in type C) that were difficult to access, failure to achieve patency in vessels with chronic total occlusions (four in the type C group) (16), and a lesion (in the type B

FIG 1. 76-year-old man with transient right-sided hemiparesis.

A, Carotid angiogram shows a 75% stenosis (type A) of the right MCA (arrow).

B, Carotid angiogram immediately after PTCBA shows sufficient dilatation and reduction to a 32% stenosis.

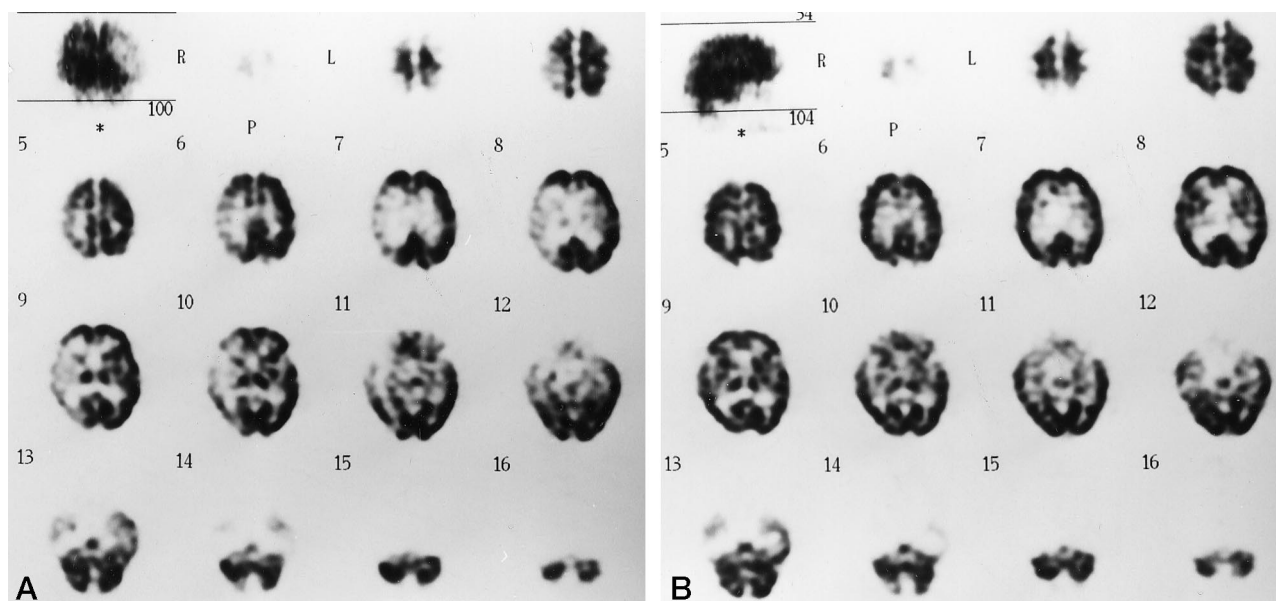
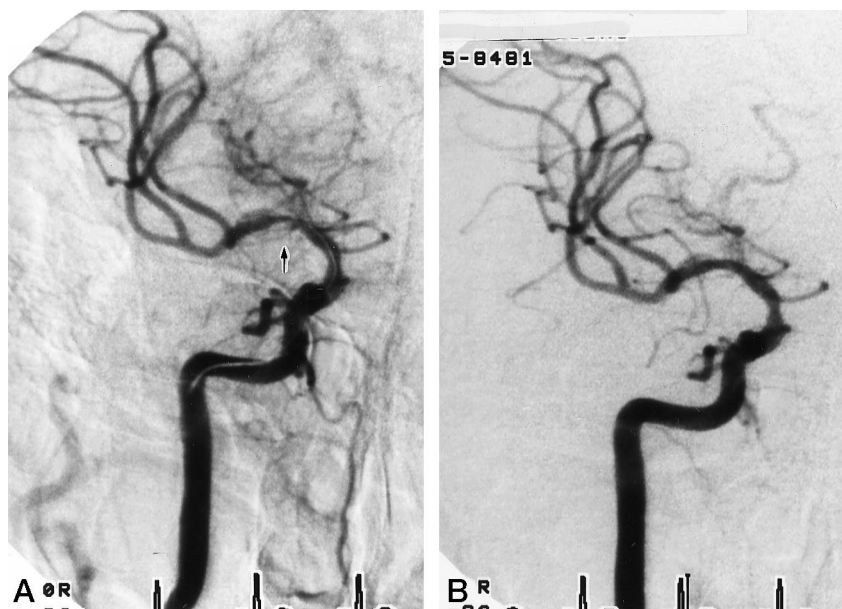


FIG 2. Same patient as in Figure 1.

A, Before PTCBA, SPECT scans with acetazolamide (1 g) challenge show impairment of vasodilatory capacity in the right MCA territory.

B, After PTCBA, SPECT scans show remarkable improvement of vasodilatory capacity.

group) that was resistant to dilatation. Two strokes occurred as major complications as a result of dissection by a guidewire in one patient with a petrous carotid stenosis (type A group) and because of abrupt closure of an MCA stenosis in another patient (type C group). The baseline angiogram showed a pre-PTCBA stenosis of $81 \pm 8\%$ in 42 patients. In 32 patients in whom dilatation was clinically successful, a pre-PTCBA stenosis of $82 \pm 10\%$ was reduced to $30 \pm 10\%$ on the immediate post-PTCBA angiogram. Consequently, 32 lesions in 32 patients were eligible for angiographic follow-up.

Among the 12 patients with recurrent or crescendo

TIAs prior to PTCBA (four, five, and three patients in type A, B, and C groups, respectively), 10 experienced clinically successful dilatation and their symptoms disappeared immediately and completely (Fig 1). However, the other two patients underwent superficial temporal artery–middle cerebral artery (STA-MCA) bypass surgery after unsuccessful PTCBA. Of the 22 patients who had brain SPECT prior to PTCBA, angioplasty was not clinically successful in six, whereas the 16 patients who were treated successfully underwent the SPECT examination within 7 days after PTCBA, and it showed remarkable improvement of vascular reserve in the affected territory

(Fig 2). PTCBA therefore showed good efficacy in improving perfusion to the affected territory, although every SPECT scan was only evaluated qualitatively, since cerebral blood flow was not measured quantitatively before and after PTCBA.

Clinical and angiographic follow-up data were available for 39 of the 42 patients, because two patients in the type B group and one in the type C group were excluded from the study immediately after unsuccessful PTCBA and followed up medically at the patients' request. Among the 39 remaining patients, 13 reached a primary end point within 1 year. In addition, a contralateral ischemic stroke occurred in one patient and a contralateral small putaminal hemorrhage occurred in another patient with a history of hypertension. In the type A group ($n = 12$), ipsilateral ischemic stroke as a major complication occurred in one patient but otherwise there were no bypass surgeries or in-hospital mortalities during the initial hospitalization. Moreover, no ischemic strokes occurred, no bypass surgery was performed, and no patient died during the follow-up period. In the type B group ($n = 21$), there were no in-hospital mortalities or ischemic strokes, but one patient underwent STA-MCA bypass surgery after unsuccessful PTCBA during the initial hospitalization, and two patients were excluded from follow-up after unsuccessful dilatation. During follow-up, no major stroke occurred, but one patient had a TIA due to restenosis, two patients underwent STA-MCA bypass surgery, and two patients died (one of subarachnoid hemorrhage as a complication of a third PTCBA and the other by a mudslide 4 years after successful PTCBA). Bypass surgery during the follow-up period was performed either for revascularization of restenosis or for a new ipsilateral lesion. In the type C group ($n = 9$), an ipsilateral ischemic stroke occurred as a major complication in one patient, and four patients underwent STA-MCA bypass surgery after unsuccessful revascularization; however, there was no in-hospital mortality during the initial hospitalization. A TIA referable to restenosis occurred in one patient after exclusion from follow-up, and two patients underwent STA-MCA bypass surgery for restenosis; however, no patient died during the follow-up period.

The rate of angiographic restenosis in type A, B, and C groups was 0% (0/11), 33% (6/18), and 100% (3/3), respectively, at 1 year ($P = .0027$, Kruskal-Wallis H test), with a significant difference between type A and C groups ($P = .0008$, Bonferroni-Dunn). The rate of angiographic restenosis in patients suffering from crescendo TIAs before PTCBA was only 10% (1/10) at 1 year, and the rate in patients with a minor stroke prior to PTCBA was 36% (8/22) at 1 year ($P = .21$, Fisher exact test). The overall rate of angiographic restenosis was 28% (9/32) at 1 year. Among nine patients with restenosis at 3 months in the type B and C groups, one patient who experienced transient hemiparesis due to restenosis underwent repeat PTCBA at once, while the other eight patients had repeat PTCBA up to 6 months later, as SPECT scans showed restenosis to impair vascular reserve

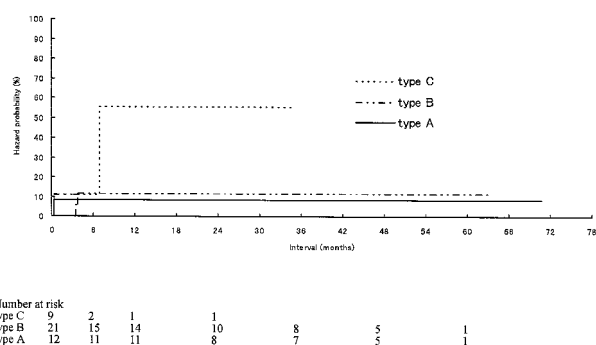


FIG 3. Cumulative hazard curves of fatal or nonfatal ipsilateral ischemic stroke ($P = .1647$, log-rank test).

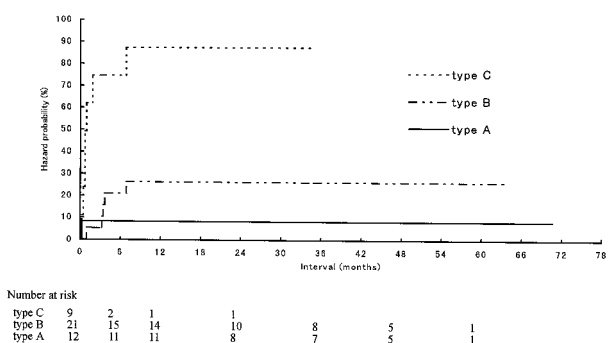


FIG 4. Cumulative hazard curves of fatal or nonfatal ipsilateral ischemic stroke and ipsilateral bypass surgery. Log-rank test reveals a significant difference between the three groups ($P < .0001$, log-rank test).

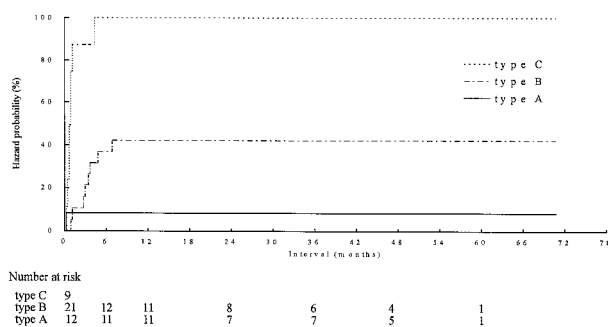


FIG 5. Cumulative hazard curves of fatal or nonfatal ipsilateral ischemic stroke, ipsilateral bypass surgery, and repeat PTCBA. The three groups are significantly different ($P < .0001$, log-rank test).

despite no symptomatic recurrence. Consequently, seven patients had two PTCBA procedures, one patient in the type B group had three procedures, and one in the type C group had four procedures. One patient in the type C group, who had undergone a second PTCBA for asymptomatic restenosis at 3 months, experienced a TIA 3 months later and underwent a third procedure.

The cumulative risk of fatal or nonfatal ipsilateral ischemic stroke in type A, B, and C groups was 8%, 12%, and 56%, respectively at 1 and 2 years ($P = .1647$, log-rank test) (Fig 3). The cumulative risk of fatal or nonfatal ipsilateral stroke and bypass surgery

TABLE 2: Summary of results reported in the literature

Study	Location of Lesion	Stenosis (%)	No. of Patients	Medication	Percentage (%) of Stroke Risk at		
					1 Year	2 Years	3 Years
Hinton et al (21) [†]	MCA	40–85	16	ASA or C	13	13	30
Caplan et al (23)	MCA	Stenosis or occlusion	18 (20)		22 for average 11.5 mo*		
Corston et al (22) [†]	MCA	33–66	21	ASA or C	15	22	
Wechsler et al (24)	DICA	≥50	15	ASA or C	21		
Marzeuski et al (25)	DICA	≥50	66		7	8	11
Craig et al (26)	DICA	>30	58	Antiplatelet	19 for average 30 mo		
Pessin et al (27) [†]	DVA-BA	40–90	9		78	78	
Moufarrij et al (28)	DVA-BA	≥50	44	ASA	14	17	20
Caplan et al (29)	DVA	Bilateral total occlusion	9	Heparin	100	100	
Chimowitz et al (20)	ACA, MCA, DICA, PCA, DVA-BA	50–99	63	ASA (325 mg daily; most common)	24 for overall stroke risk and 14 for ipsilateral stroke risk, for a median duration of 19.3 mo		
EC/IC (medical) study (4)	MCA, DICA, ICA	Stenosis, occlusion	714	ASA (1300 mg daily)	10	14	18

Note.—ACA indicates anterior cerebral artery; MCA, middle cerebral artery; PCA, posterior cerebral artery; DICA, distal internal carotid artery; DVA, distal vertebral artery; BA, basilar artery; ASA, aspirin; C, coumadin.

* One stroke death and three TIAs among 18 patients except two who had undergone bypass surgery.

† Stroke was defined as any neurologic deficit, including TIAs after admission.

in type A, B, and C groups was 8%, 26%, and 87%, respectively, at 1 and 2 years ($P < .0001$, log-rank test) (Fig 4), with significant differences between type A and C groups ($P = .0005$) and between type B and C groups ($P = .0001$). The cumulative risk of fatal or nonfatal ipsilateral stroke, bypass surgery, and repeat PTCBA in type A, B, and C groups was 8%, 42%, and 100%, respectively, at 1 and 2 years ($P < .0001$, log-rank test) (Fig 5), with significant differences between type A and C groups ($P = .0001$) and between type B and C groups ($P < .0001$), although the difference between type A and B groups was not significant ($P = .0657$).

Ipsilateral strokes during follow-up included only two TIAs due to restenosis and one subarachnoid hemorrhage as a complication of a third PTCBA, which was included as ischemic stroke in one patient in the type B group. No patient had a major ischemic stroke after successful PTCBA treatment. The overall cumulative risk of fatal or nonfatal ipsilateral stroke and of fatal or nonfatal ipsilateral ischemic stroke and bypass surgery was 14% and 33%, respectively, at 1 and 2 years.

Among 54 consecutive elective PTCBAs performed during the study period, a total of three major complications occurred, with an overall morbidity and mortality rate of 5.6%.

Discussion

Although a previous study (19) reported that the survival rate of patients with arterial stenosis of 25% or more is significantly lower than the expected survival rate in a general population, there are few reports concerning the natural history of patients with a high-grade stenosis (>70%) of the intracranial artery

documented by cerebral arteriography. Some previous studies (20–29), which included patients with various grades of stenosis (low-grade to high-grade), have reported the clinical outcome of patients with intracranial arterial stenosis who were treated medically, in contrast to the clinical outcome in patients with only high-grade stenosis (>70%) in the present study. Although we are not unmindful of the great difference in angiographic characteristics of lesions between historical control studies and the present study, the clinical outcome must be compared. We defined stroke as any neurologic deficit, including a TIA, and recalculated the cumulative stroke risk by using the Kaplan-Meier method based on data described in some previous studies (21, 22, 27). In the historical studies, cumulative stroke risk ranged from 8% to 100% at 2 years, and many studies reported a 13% to 22% ischemic stroke risk at 2 years (Table 2). For instance, ipsilateral stroke risks at 1, 2, and 3 years were approximately 10%, 14%, and 18%, respectively, in patients in the EC/IC (medical) study (4), in which grade of stenosis was not defined. However, Caplan et al (29) reported that 100% of patients suffering from symptoms referable to bilateral intracranial vertebral artery occlusion died during hospitalization.

Cumulative risk of fatal or nonfatal ipsilateral stroke and of ipsilateral stroke and bypass surgery was only 8% at 2 years in the type A group, which included four patients exhibiting crescendo TIAs, and this seemed to be smaller than in the historical studies. Although there was no statistical difference in fatal or nonfatal ipsilateral stroke risk between the three groups (types A, B, and C), this could be attributed to a type II statistical error caused by the small population in the present study. There were signifi-

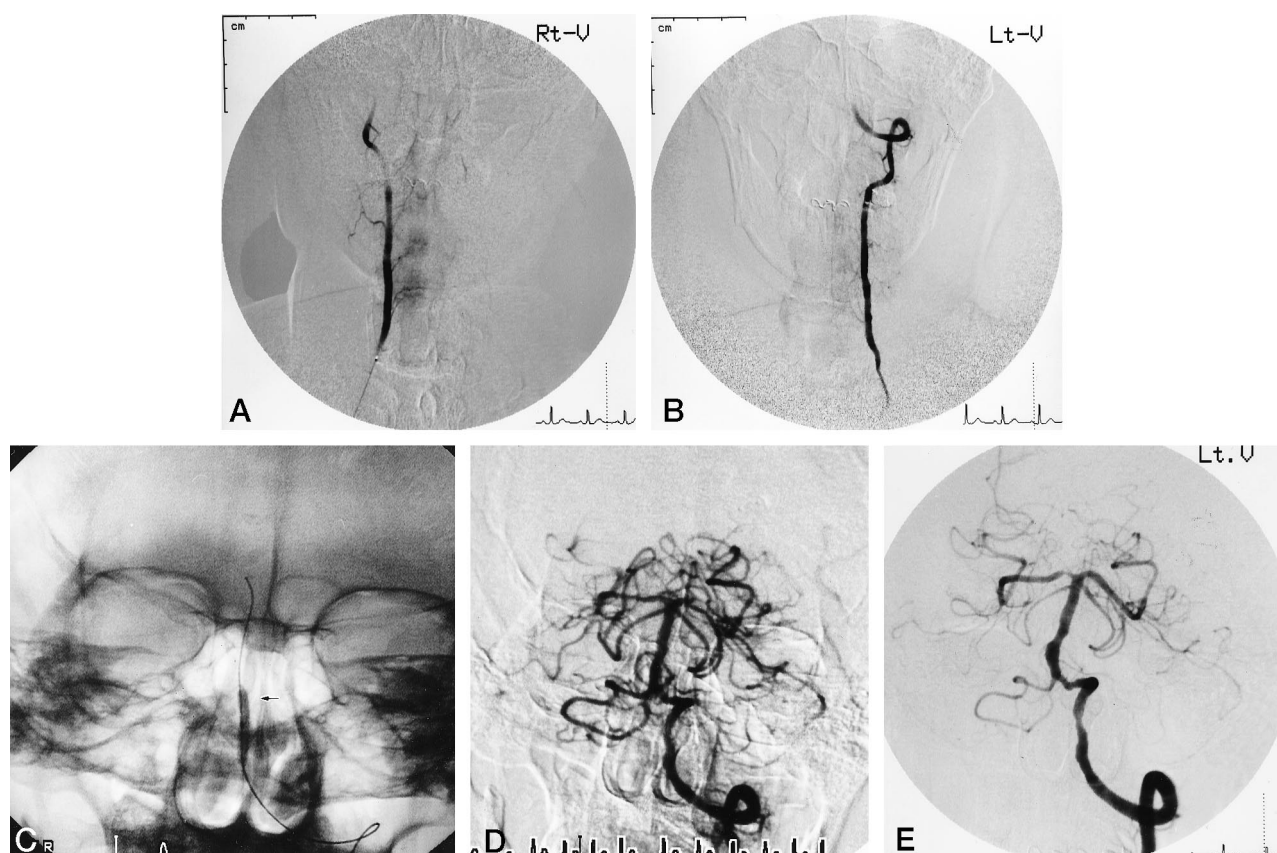


FIG 6. 60-year-old man with persistence of dysarthria, dysphasia, trunk ataxia, and vertigo for 40 days.

A and B, Right (A) and left (B) vertebral angiograms show total occlusions (type B) of both vertebral arteries to the basilar artery.

C, Inflation of the balloon catheter (arrow) at the left vertebrobasilar junction.

D, Successful revascularization at least 40 days after total occlusion.

E, Left vertebral angiogram 1 year after PTCBA shows good patency and no restenosis.

cant differences in cumulative risks of ipsilateral stroke and bypass surgery and of ipsilateral stroke, bypass surgery, and repeat PTCBA between the three groups, with the risk of cerebral events the smallest in the type A group, although the difference between type A and B groups was not significant and could be attributed to a type II error. Type A lesions are associated with high success rate and a low cerebral event risk, and are therefore the most responsive to cerebral balloon angioplasty; thus, PTCBA seems to be an appropriate treatment for type A lesions. In contrast, the high prevalence of fatal or nonfatal ipsilateral stroke and bypass surgery associated with type C lesions after PTCBA suggests that PTCBA should not be attempted in patients with type C lesions. The outcome of PTCBA for type B lesions remains controversial. However, if patients suffer from crescendo TIAs referable to intracranial type B lesions in the posterior cerebral circulation, in which a high complication rate of bypass surgery can be anticipated, then PTCBA seems to be a relatively successful alternative to vascular reconstruction. When maximal medical therapy has no efficacy in improving crescendo TIAs or impending stroke due to an intracranial arterial stenosis or occlusion, there is no alternative but bypass surgery. Indeed, Caplan et al (23) reported that two of 20 patients with severe

MCA occlusive disease were treated by STA-MCA bypass surgery because of progression despite adequate anticoagulation therapy; unfortunately, though, it is not certain whether bypass surgery is really effective in the treatment of patients suffering from such recurrent TIAs. In the present study, 10 of 12 patients with crescendo TIAs before PTCBA were successfully treated and had complete cessation of symptoms after successful dilatation, although two patients in the type C group underwent bypass surgery after unsuccessful PTCBA. This suggests that antegrade revascularization by PTCBA has great efficacy in improving perfusion to the affected territory, and thus we expect that PTCBA can be effective in treating patients who suffer from crescendo TIAs or impending stroke.

Restenosis rates of 30% to 50% after standard coronary angioplasty have been reported (18, 30), and, overall, the angiographic restenosis rate of 28% after PTCBA appears to be less than after standard coronary angioplasty, although the exact rate of restenosis after PTCBA is unknown (31). In the type A group, moreover, the angiographic restenosis rate after PTCBA was 0% at 1 year. Considering that coronary angioplasty is common worldwide despite a restenosis rate ranging from 30% to 50%, the overall

restenosis rate of 28% after PTCBA seems to be acceptable.

The success rate and clinical outcome for the type A group are encouraging and warrant further investigation, including a randomized trial of PTCBA for intracranial atherosclerotic type A lesions. However, the present study has several important limitations. The investigation was conducted in a single neurosurgical department, and the number of patients was very small. In making comparisons across the three groups, a basic assumption was that the groups were comparable in all ways except for the basic risk factor; however, because of the small sample size, there is little power to rule out other important differences, making it hard to ascertain the effect of treatment. This limitation also applies to comparisons of clinical outcome. In addition, technical skill has improved with experience. Not only stenosis but also chronic total occlusion was treated by PTCBA (32) in the present study (Fig 6). In fact, five of six total occlusions in the type B group and one of five in the type C group were successfully repaired in the chronic stage. The study included patients with crescendo TIAs before PTCBA as well as those with minor stroke, and their restenosis rates appear to be slightly different from one another, although this difference was not statistically significant. The two neurosurgeons who participated in the PTCBA procedures calculated the angiographic stenosis rate before and after PTCBA, and the investigator who assessed the patients' clinical status before and after PTCBA was not blind to the angiographic results, since only patients whose PTCBA treatment was successful were included in the follow-up, although the assessor was not involved in the PTCBA procedures. The fact that those performing PTCBA also did the evaluation could easily lead to some degree of bias. Moreover, this study includes no valid comparison group of patients who received medication only. This makes it hard to make strong inferences about the effects of treatment. Like the carotid and vertebral artery transluminal angioplasty study (33), a randomized study is needed between medical and PTCBA techniques to assess the safety and efficacy of PTCBA therapy more accurately. Although repeatability is one of the benefits of PTCBA, whether PTCBA should be repeated for restenosis prior to symptomatic recurrence is controversial, even when SPECT scans show lesions to be hemodynamically significant.

Conclusion

Our results suggest that PTCBA for simple (type A) intracranial lesions produces a favorable clinical outcome for symptomatic patients, a hypothesis that warrants further testing by means of a randomized trial of PTCBA for intracranial atherosclerotic type A lesions.

Acknowledgment

We thank Louise E. Johnstone, Department of Physiology, Kochi Medical School, for proofreading the manuscript.

References

- Diener HC, Hacke W, Hennerici M, et al. **Lubeluzole in acute ischaemic stroke: a double-blind, placebo-controlled phase II trial.** *Stroke* 1996;27:76–81
- Nishimaru K, McHenry LC Jr, Toole JF. **Cerebral angiographic and clinical differences in carotid system transient ischemic attacks between American Caucasian and Japanese patients.** *Stroke* 1984;15:56–59
- Mathur VS, Guinn GA, Anastassiades LC, et al. **Surgical treatment for stable angina pectoris: prospective randomized study.** *N Engl J Med* 1975;292:709–713
- The EC/IC bypass study group. **Failure of extracranial-intracranial arterial bypass to reduce the risk of ischaemic stroke.** *N Engl J Med* 1985;313:1191–1200
- Hopkins LN, Budny JL. **Complications of intracranial bypass for vertebrobasilar insufficiency.** *J Neurosurg* 1989;70:207–211
- Higashida RT, Tsai FY, Halbach VV, et al. **Percutaneous transluminal angioplasty of extra- and intracranial cerebral vascular disease.** *Neuroradiology* 1995;37(Suppl):449–450
- Clark WM, Barnwell SL, Nesbit G, O'Neil OR, Wynn ML, Coull BM. **Safety and efficacy of percutaneous transluminal angioplasty for intracranial atherosclerotic stenosis.** *Stroke* 1995;26:1200–1204
- Mori T, Fukuoka M, Mori K. **Percutaneous transluminal angioplasty for arteriosclerotic lesions of extra- and intracranial arteries.** *Neuroradiology* 1995;37(Suppl):451–452
- Mori T, Mori K, Fukuoka M, et al. **Serial angiographic follow-up after percutaneous transluminal cerebral angioplasty.** *Neuroradiology* 1997;39:111–116
- Neto JIS, Santos AC, Fabio SRC, Sakamoto AC. **Cerebral infarction in patients aged 15 to 40 years.** *Stroke* 1996;27:2016–2019
- Vorstrup S, Brun B, Lassen NA. **Evaluation of the cerebral vasodilatory capacity by the acetazolamide test before EC-IC bypass surgery in patients with occlusion of the internal carotid artery.** *Stroke* 1986;17:1291–1298
- Touho H. **Percutaneous transluminal angioplasty in the treatment of atherosclerotic disease of the anterior cerebral circulation and haemodynamic evaluation.** *J Neurosurg* 1995;82:953–960
- Gibbs JM, Wise RJS, Leenders KL, Jones T. **Evaluation of cerebral perfusion reserve in patients with carotid-artery occlusion.** *Lancet* 1984;1:310–314
- Gibbs JM, Wise RJS, Thomas DJ, Mansfield AO, Russel RWR. **Cerebral haemodynamic changes after extracranial-intracranial bypass surgery.** *J Neurol Neurosurg Psychiatry* 1987;50:140–150
- North America Symptomatic Carotid Endarterectomy Trial Collaborators. **Beneficial effect of carotid endarterectomy in symptomatic patients with high-grade carotid stenosis.** *N Engl J Med* 1991;325:445–453
- Ryan TJ, Bauman WB, Kennedy JW. **Revised guidelines for percutaneous transluminal coronary angioplasty: a report of the American College of Cardiology/American Heart Association Task Force on Assessment of Diagnostic and Therapeutic Cardiovascular Procedures (Subcommittee on Percutaneous Transluminal Angioplasty).** *Circulation* 1993;88:2987–3007
- Serryus PW, Luiten HE, Beatt KJ, et al. **Incidence of restenosis after successful coronary angioplasty, a time-related phenomenon: a quantitative angiographic study in 342 consecutive patients at 1, 2, 3, and 4 months.** *Circulation* 1988;77:361–371
- Nobuyoshi M, Kimura T, Nosaka H, et al. **Restenosis after successful percutaneous transluminal coronary angioplasty: serial angiographic follow-up of 229 patients.** *J Am Coll Cardiol* 1988;12:616–623
- Nishimaru K, Takeya Y, Nishino Y, Omae T. **Long-term prognosis of cerebral infarction-Influence of arterial stenotic lesion for survival.** *No Shinkei Geka* 1979;31:1111–1116
- Chimowitz MI, Kokkinos J, Strong J, et al. **The warfarin-aspirin symptomatic intracranial disease study.** *Neurology* 1995;45:1488–1493
- Hinton RC, Mohr JP, Ackerman RH, Adair LB, Fisher CM. **Symptomatic middle cerebral artery stenosis.** *Ann Neurol* 1979;5:152–157

22. Corston RN, Kendall BE, Marshall J. **Prognosis in middle cerebral artery stenosis.** *Stroke* 1984;15:237-241
23. Caplan L, Babikian V, Helgason C, et al. **Occlusive disease of the middle cerebral artery.** *Neurology* 1985;35:975-982
24. Wechsler LR, Kistler JP, Davis KR, Kaminski MJ. **The prognosis of carotid siphon stenosis.** *Stroke* 1986;17:714-718
25. Marzewski DJ, Furlan AJ, St Louis P, Little JR, Modic MT, Williams G. **Intracranial internal carotid artery stenosis: long-term prognosis.** *Stroke* 1982;13:821-824
26. Craig DR, Meguro K, Watridge C, Robertson JT, Barnett HJM, Fox AJ. **Intracranial internal carotid artery stenosis.** *Stroke* 1982;13:825-828
27. Pessin MS, Gorelick PB, Kwan ES, Caplan LR. **Basilar artery stenosis: middle and distal segments.** *Neurology* 1987;37:1742-1746
28. Moufarrij NA, Little JR, Furlan AJ, Leatherman JR, Williams GW. **Basilar and distal vertebral artery stenosis: long-term follow-up.** *Stroke* 1986;17:938-942
29. Caplan LR. **Bilateral distal vertebral artery occlusion.** *Neurology* 1983;33:552-558
30. Gruentzig AR, King SB III, Schlumpf M, Siegenthaler W. **Long-term follow-up after percutaneous transluminal coronary angioplasty: the early Zurich experience.** *N Engl J Med* 1987;316:1127-1132
31. Mori T, Fukuoka M, Kazita K, Mori K. **Follow-up study after percutaneous transluminal cerebral angioplasty.** *Euro Radiol* 1998;8:403-408
32. Mori T, Mori K, Fukuoka M, Mori K. **Percutaneous transluminal cerebral angioplasty for total occlusion of middle cerebral arteries.** *Neuroradiology* 1997;39:71-74
33. Brown MM. **Carotid and vertebral artery transluminal angioplasty study (CAVATAS): progress report.** *Cerebrovasc Dis* 1996;6(S2):34

Please see the Editorial on page 1387 in this issue.