



## Discover Generics

Cost-Effective CT & MRI Contrast Agents



WATCH VIDEO

# AJNR

### **The use of electrolytically detachable coils in treating high-flow arteriovenous fistulas.**

G M Nesbit and S L Barnwell

*AJNR Am J Neuroradiol* 1998, 19 (8) 1565-1569

<http://www.ajnr.org/content/19/8/1565>

This information is current as  
of June 18, 2025.

# The Use of Electrolytically Detachable Coils in Treating High-Flow Arteriovenous Fistulas

Gary M. Nesbit and Stan L. Barnwell

**BACKGROUND AND PURPOSE:** High-flow arteriovenous fistulas (AVFs) are commonly treated by using an endovascular approach with a variety of materials. The use of a Guglielmi electrolytically detachable coil (GDC) provides the ability to reposition or remove the coil if its position is not optimal and may minimize the risk of coil migration or distal embolization. This study reports our experience in using these coils alone or in combination with other materials in the treatment of intracranial and cervical high-flow fistulas.

**METHODS:** Twelve patients with AVFs were treated with GDCs via the transvenous or transarterial-transfistulous routes. The six dural AVFs treated transvenously were also treated transarterially, and the GDCs were combined with fibered coils in three of these patients and in two other patients with pial AVFs. All patients have been clinically followed up for 12 to 48 months (mean, 28 months).

**RESULTS:** Angiographic obliteration was obtained in all 12 patients. The fistulas have remained closed in 11 patients, as ascertained by angiographic confirmation in two patients and by clinical examination in nine patients. The one patient with recurrence experienced neurologic improvement and refused further treatment. GDCs required repositioning before detachment in seven patients, and no migration occurred after detachment.

**CONCLUSION:** GDCs are useful for the treatment of high-flow AVFs. They afford more control in the placement of coils and may provide an anchoring point for more thrombogenic materials.

Treatment of arteriovenous fistulas (AVFs) involving the arteries and veins of the brain, head and neck, and spine are commonly treated by using a variety of embolic materials. To maximize the chance for long-term closure of the fistula, it is usually recommended to treat either the fistula directly with some form of occlusive device or to treat both the supplying arteries and the fistulous venous segment (1), if this can be done safely. Significant risk exists for either proximal or distal coil migration and possible pulmonary embolization because of rapid flow. Guglielmi electrolytically detachable coils (GDCs) may be repositioned if their position is not optimal, a characteristic that represents a significant advancement over standard platinum coils. This study reports our experience in using these coils to treat AVFs of the dural and cavernous sinuses, the vertebral artery, and the vein of Galen.

## Methods

Twelve patients with AVFs were treated with GDCs and their records were then reviewed retrospectively. Six of the patients had high-flow dural AVFs of the sigmoid or marginal sinus. These patients were each initially treated with transarterial particulate embolization with polyvinyl alcohol particles (Contour [355–500  $\mu$ m], ITC, Fremont, CA) and a fibered coil. In one patient, transarterial embolization was additionally performed by using a 2-mm 4–0 silk suture and 50% dextrose on the arterial side. This treatment was followed with transvenous GDC embolization over the fistulous region in all six patients with dural AVFs. Fibered platinum coils were also used in three patients. Systemic heparinization was administered in one patient during the transarterial embolization of a vertebral dural branch.

The remaining six patients included three with direct traumatic carotid-cavernous fistulas, one with a postsurgical direct vertebral artery to vertebral plexus fistula, one with a single-hole perimedullary fistula and a lower thoracic spinal cord pial AVF, and one with a posterior cerebral artery pial AVF that drained into the vein of Galen (Yasargil type 4). All six of these patients were treated via a transarterial transfistulous route by using GDCs placed both distal and proximal to the fistula. Fibered platinum coils were also used in three patients (two with vein of Galen and spinal cord pial AVFs and one with a carotid-cavernous fistula) to increase thrombogenicity, once it was determined that the fistula was “protected” by the GDCs. Systemic heparinization with a transarterial transfistulous approach was used in all six patients.

All patients were treated via the transfemoral approach for both the transarterial and transvenous embolizations. Com-

Received August 15, 1997; accepted after revision January 22, 1998.

From the Dotter Interventional Institute and the Departments of Radiology and Neurosurgery, Oregon Health Sciences University Portland. Address reprint requests to Gary M. Nesbit, MD, OHSU Neuroradiology, L340, 3181 SW Sam Jackson Park R, Portland, OR 97201.

**Patient findings**

Patient	Age, y/Sex	Presentation	Type of AVF	Initial Treatment	Repositioning/Embolization
1	62/F	Left bruit	Sigmoid dural AVF	TA-PVA/coils TV-GDC	None
2	2.5/F	Myelopathy	Perimedullary AVF	TA/TF-GDC and fibered coils	Distal herniation: repositioned
3	71/F	Left bruit	Sigmoid dural AVF	TA-PVA/coils TV-GDC	Distal herniation: repositioned
4	72/F	Left bruit	Sigmoid dural AVF	TA-PVA/coils TV-GDC and fibered coils	None
5	60/F	Proptosis ↓ Vision Bruit	Direct CCF	TA/TF-GDC	Proximal herniation: repositioned
6	64/F	Left bruit	Marginal sinus AVF	TA-PVA/coils TV-GDC and fibered coils	Distal embolization of fibered coil; proximal herniation: repositioned
7	51/F	Radiculopathy Bruit	Vertebral AVF	TA/TF-GDC	Proximal herniation: repositioned
8	59/F	Left bruit	Sigmoid dural AVF	TA-PVA/coils/Silk/Dextrose TV-GDC	None
9	5/M	↓ Mentation  Bruit	Pial-galenic AVF	TA/TF-GDC and fibered coils	Embolization of initial fibered coil; distal herniation
10	42/M	Proptosis ↓ Vision	Direct CCF	TA/TF-GDC	Proximal herniation: repositioned
11	51/F	GSW ↓ Vision	Direct CCF	TA/TF-GDC fibered coils	None
12	56/F	Left bruit	Sigmoid dural AVF	TA-PVA/coils TV-GDC and fibered coils	None

Note.—CCF, carotid-cavernous fistula; TA, transarterial; TV, transvenous; TA/TF, transarterial-transfistulous; PVA, polyvinyl alcohol; GSW, gunshot wound.

plete neurologic examination and assessment were performed before, immediately after, and during follow-up in all patients. All patients have been clinically followed up for 12 to 48 months (mean, 28 months).

## Results

All 12 patients experienced angiographic obliteration of the AVFs after one treatment with the GDC system. The fistulas have remained closed in 11 of the 12 patients, as ascertained by angiographic confirmation in two patients and by clinical examination in nine patients.

A severe pulsatile tinnitus or a significantly audible bruit on auscultation had occurred previously in all 12 of these patients. In 10 patients, symptoms resolved; in two, they were diminished. These two patients continued to report pulsatile tinnitus but had no bruit and angiograms were negative at 6 and 8 months. The patient with the large spinal cord perimedullary AVF experienced clinical recurrence of her audible spinal bruit on auscultation but has had no recurrence of her myelopathy, no back pain, and no neurologic deterioration. She has refused further therapy (see Table).

In two patients, a fibered coil embolized to a pulmonary arterial branch before the placement of a GDC, and its embolization was the primary reason for switching to the GDC device. In one patient, a 5-year-old boy with a fistula of the vein of Galen, the coil was retrieved after the embolization was complete. In the other patient, a 64-year-old woman with

a marginal sinus AVF, the coil was left in place because of its small size. No further coil embolization occurred with the GDCs or with other fibered coils after the GDCs had been placed and detached.

Repositioning of the GDC before detachment was required in seven patients because of migration. In three of these cases, GDC repositioning was required because of proximal herniation into the parent artery, two in carotid-cavernous fistulas and one in a vertebral artery to paravertebral plexus fistula. Proximal herniation into the dominant internal jugular vein required repositioning in the patient with a marginal sinus AVF. In two other patients, repositioning was required because of distal migration of the coil too far into the draining vein. In the remaining patient, repositioning was required because of migration proximal to the origin of the vein of Labbé. All coils were successfully repositioned, with no herniation of coils into the parent artery. No migration of the GDC or other coils occurred after detachment. The two patients with pulmonary arterial embolization of a fibered coil before placement of the GDC required repositioning of the GDC during its placement. No neurologic sequelae were detected during follow-up in any of the 12 patients.

## Discussion

The endovascular therapy of high-flow AVFs poses significant problems in certain cases. The risk of distal embolization into the venous system with a rapid increase in fistula pressure or pulmonary emboliza-

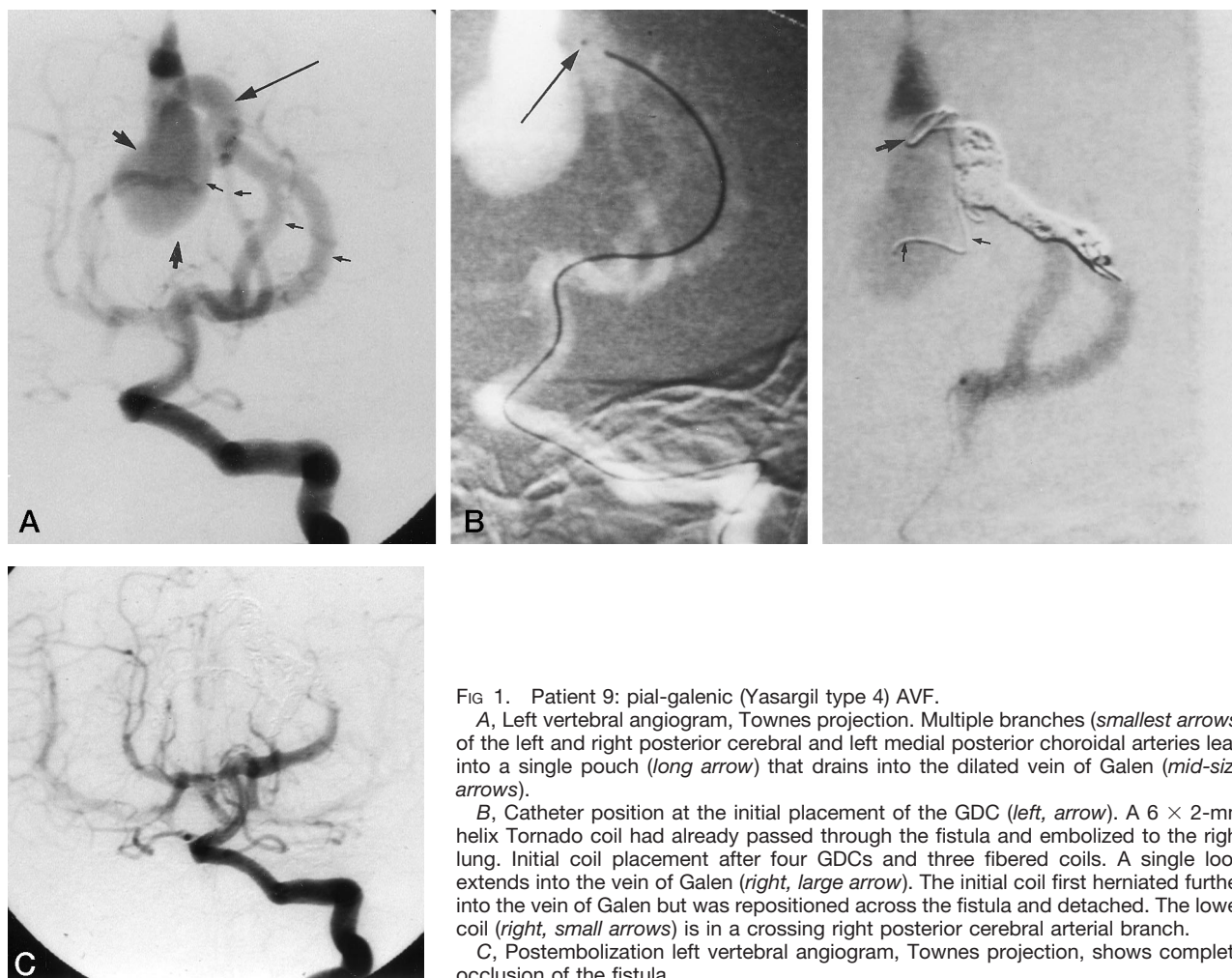


FIG 1. Patient 9: pial-galenic (Yasargil type 4) AVF.

A, Left vertebral angiogram, Townes projection. Multiple branches (*smallest arrows*) of the left and right posterior cerebral and left medial posterior choroidal arteries lead into a single pouch (*long arrow*) that drains into the dilated vein of Galen (*mid-size arrows*).

B, Catheter position at the initial placement of the GDC (*left, arrow*). A 6 × 2-mm helix Tornado coil had already passed through the fistula and embolized to the right lung. Initial coil placement after four GDCs and three fiberoil coils. A single loop extends into the vein of Galen (*right, large arrow*). The initial coil first herniated further into the vein of Galen but was repositioned across the fistula and detached. The lower coil (*right, small arrows*) is in a crossing right posterior cerebral arterial branch.

C, Postembolization left vertebral angiogram, Townes projection, shows complete occlusion of the fistula.

tion is almost always a consideration when treating these lesions (1, 2). With the advent of the GDC, the ability to reposition or remove the coil if this occurs provides better control and reduces the risks of endovascular treatment (3).

Descriptions of the use of GDCs have been reported in the treatment of a pial AVF (4), a ruptured intracavernous aneurysm (5), and an iatrogenic traumatic carotid-cavernous fistula (6). All cases were treated successfully without sequelae. Other detachable coil devices, such as the interlocking detachable coil, have also shown promise in the treatment of AVFs of the extremities and the dura (7, 8). The results reported in these case reports are also good, but the inherent low thrombogenicity of these devices may limit their efficacy when used alone. The electrolytic detachment of the GDCs increase their thrombogenicity; however, the degree of this in vivo, especially during systemic heparinization, is not well established (9). The use of fiberoil coils, when they can be safely placed, should increase the overall thrombogenicity of the embolization, enabling more complete and persistent occlusion.

Our experience shows that distal embolization can be eliminated or minimized by using GDCs (Fig 1). The distal embolization in two patients might have

been prevented if GDCs had been used initially, and the distal herniation of the GDC in three patients, which was corrected with repositioning, supports this point. Other techniques, such as temporary flow arrest by means of an occlusion balloon microcatheter or a guiding catheter, may also minimize the distal migration of coils. However, a possible risk of migration exists when the balloon is deflated, unless adequate coil packing is achieved. We elected to use GDCs whose helix size was 20% to 50% greater than the vessel to be occluded to provide good wall contact, unlike in the treatment of aneurysms. With careful catheter positioning, a compact zone of coil placement can be achieved. We tend to use the GDCs to provide a nest for the placement of fiberoil coils, if proximal herniation is not a concern. This nest technique can also provide an anchor point for other materials, such as more thrombogenically coated coils or more completely occlusive materials, such as cyanoacrylates. The use of more thrombogenic materials may be necessary in some high-flow fistulas to achieve occlusion. Some fistulas in this study may possibly have recurred, since angiographic follow-up was only obtained in two patients.

The concern in transvenous embolization of sigmoid or other dural AVFs is occlusion of important



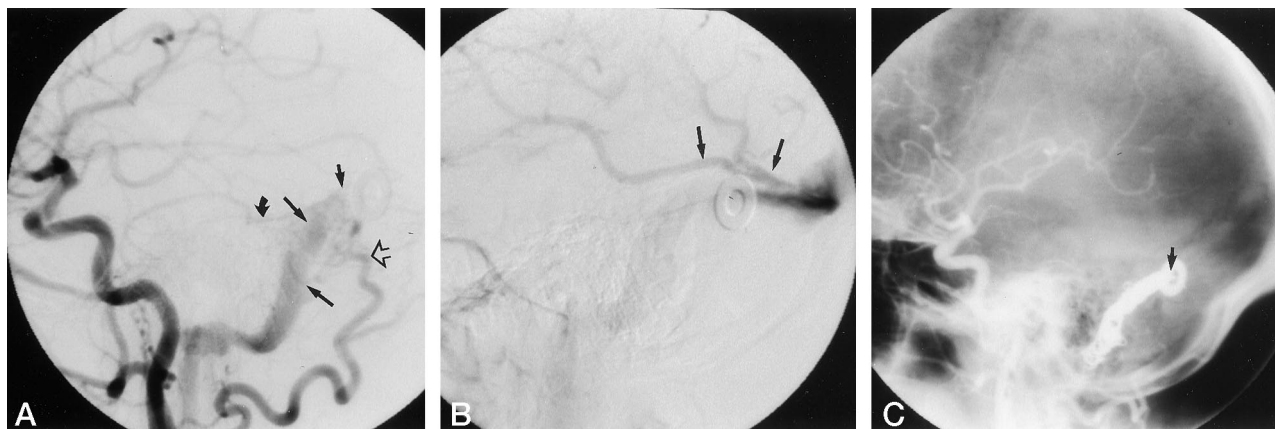


FIG 2. Patient 3: left sigmoid dural AVF.

A, Left common carotid artery angiogram, lateral projection, shows enlarged branches of the left occipital (*open arrow*), ascending pharyngeal, and posterior division of the middle meningeal (*curved arrow*) arteries supplying fistulas to the sigmoid sinus (*long arrows*). The posterior margin of the fistula is at the level of the washer (*short arrow*).

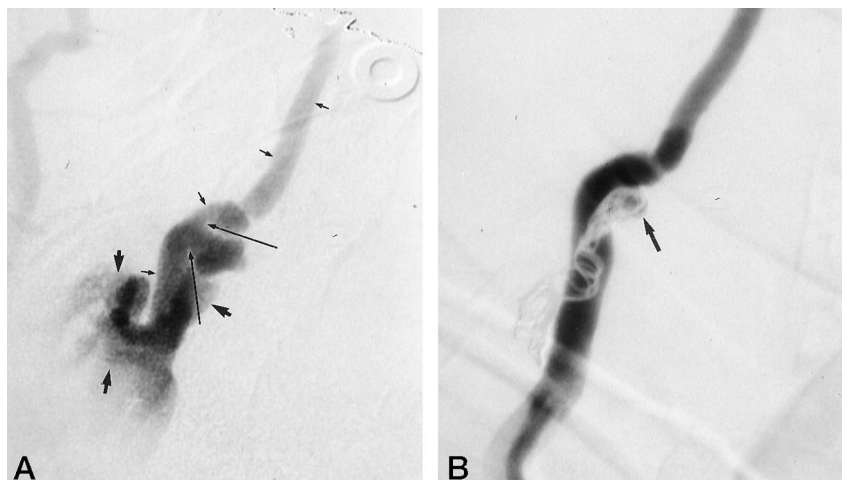
B, Left internal carotid artery angiogram, lateral projection, shows left vein of Labbé (*arrows*) lying just distal to the fistulous segment, at the level of the washer.

C, Postembolization left common carotid angiogram. The coiled segment lies at the washer (*arrow*), which is immediately below the termination of the vein of Labbé, enabling adequate drainage of the vein of Labbé.

FIG 3. Patient 7: right vertebral artery AVF.

A, Right vertebral artery angiogram, anteroposterior projection. The right vertebral artery (*smallest arrows*) has a single-hole fistula (*long arrows*) that drains into the vertebral plexus (*mid-size arrows*). An attempt at balloon occlusion in the proximal pouch with variable filling rates and volumes resulted in distal herniation or vertebral occlusion.

B, Postembolization right vertebral angiogram shows complete occlusion of the fistula with minimal filling of the proximal pouch (*arrow*) and preservation of the parent artery.



normal draining veins, such as the vein of Labbé; however, with careful catheter and coil manipulation, the coils can be placed over the fistulous segment (Fig 2). Distal or pulmonary embolization may be a lesser concern in sigmoid dural AVFs because of the variable tortuosity and narrowing of the sinus as it enters the jugular bulb. Caudal to the jugular bulb, the internal jugular vein enlarges as it descends, increasing the risk of distal migration in this region. GDCs or other detachable coils may also decrease the risk in embolizing fistulas involving the internal jugular vein.

In the treatment of fistulas immediately adjacent to a large parent artery, such as a carotid-cavernous fistula or vertebral fistula, exact coil positioning and the prevention of herniation into the parent vessel are critical in minimizing the persistence of pseudoaneurysms and embolic complications (Fig 3). The transarterial-transfistulous route of embolization of these lesions is similar to that used for treatment of aneurysms, with the exception that more distal and extensive coil packing may be necessary to occlude the

rapidly flowing fistula compared with a more slowly flowing aneurysm. This initial treatment is followed by treatment similar to that used for an aneurysm, with the direct fistula acting as the aneurysmal neck. The balloon technique described by Moret et al (10) could also be applied to direct carotid-cavernous fistulas to minimize proximal migration.

## Conclusion

GDCs provide a useful adjunct in the treatment of high-flow AVFs. They afford more control in the placement of coils and may provide an anchoring point for more thrombogenic materials.

## References

1. Halbach VV, Higashida RT, Barnwell SL, Dowd CF, Hieshima GB. Transarterial platinum coil embolization of carotid-cavernous fistulas. *AJNR Am J Neuroradiol* 1991;12:429-433

2. Ishii K, Goto K, Ihara K, et al. **High-risk dural arteriovenous fistulae of the transverse and sigmoid sinuses.** *AJNR Am J Neuroradiol* 1987;8:1113-1120
3. Guglielmi G, Viñuela F, Dion J, et al. **Electrothrombosis of saccular aneurysms via endovascular approach, 2: preliminary clinical experience.** *J Neurosurg* 1991;75:8-14
4. Teitelbaum GP, Higashida RT, Halbach VV, et al. **Flow-directed use of electrolytically detachable platinum embolization coils.** *J Vasc Interv Radiol* 1994;5:453-456
5. Guglielmi G, Viñuela F, Briganti F, Duckwiler G. **Carotid-cavernous fistula caused by a ruptured intracavernous aneurysm: endovascular treatment by electrothrombosis with detachable coils.** *Neurosurgery* 1992;31:591-597
6. Guglielmi G, Viñuela F, Duckwiler G, Dion J, Stocker A. **High-flow, small-hole arteriovenous fistulas: treatment with electrode-detachable coils.** *AJNR Am J Neuroradiol* 1995;16:325-328
7. Reidy JF, Qureshi SA. **Interlocking detachable platinum coils, a controlled embolization device: early clinical experience.** *Cardiovasc Intervent Radiol* 1996;19:85-90
8. Yoshimura S, Hashimoto N, Kazekawa K, Nishi S, Sampei K. **Embolization of dural arteriovenous fistulas with interlocking detachable coils.** *AJNR Am J Neuroradiol* 1995;16:322-324
9. Guglielmi G, Viñuela F, Sepetlea I, et al. **Electrothrombosis of saccular aneurysms via endovascular approach, 1: electrochemical basis, technique, and experimental results.** *J Neurosurg* 1991;75:1-7
10. Moret J, Cognard C, Weill A, et al. **Reconstruction technic in the treatment of wide-neck intracranial aneurysms: long-term angiographic and clinical results.** *J Neuroradiol* 1997;24:30-44