



Get Clarity On Generics

Cost-Effective CT & MRI Contrast Agents



FRESENIUS
KABI

WATCH VIDEO

AJNR

**Traumatic vertebral arterial dissection and
vertebrobasilar arterial thrombosis
successfully treated with endovascular
thrombolysis and stenting.**

R F Price, R Sellar, C Leung and M J O'Sullivan

This information is current as
of August 27, 2025.

AJNR Am J Neuroradiol 1998, 19 (9) 1677-1680
<http://www.ajnr.org/content/19/9/1677>

Traumatic Vertebral Arterial Dissection and Vertebrobasilar Arterial Thrombosis Successfully Treated with Endovascular Thrombolysis and Stenting

Rupert F. Price, Robin Sellar, Clarence Leung, and Michael J. O'Sullivan

Summary: A case of traumatic extracranial vertebral arterial dissection leading to vertebrobasilar thrombosis and respiratory compromise requiring mechanical ventilation was managed with intraarterial thrombolysis and stenting of the vertebral intimal dissection. In contrast to similar, previously reported cases, this critically ill patient made a full recovery, returning to his job as a secondary school teacher.

Dissection of the extracranial cerebral vasculature may occur spontaneously, after trauma, or in association with a variety of vasculopathies. The natural history of this condition remains contentious (1, 2). There is a recognized tendency for delayed or progressive deterioration in about a third of patients, which has been attributed to local vascular occlusion and/or distal thromboembolism, leading many authors to advocate elective treatment with anticoagulants (3–5). On the other hand, up to 85% of dissection-related stenoses have been reported to resolve with conservative management alone (6). It seems clear that if distal thromboembolic phenomena occur in the vertebrobasilar territory, they are associated with significant mortality and neurologic morbidity, although even here some authors report a more benign natural history than was previously accepted (7). Where deterioration has occurred, a variety of surgical interventions have been advocated, including endarterectomy and/or embolectomy, ligation, resection and reconstruction, or bypass of an occluded segment (1). In the search for less invasive strategies, endovascular balloon occlusion of the dissected vessel and, more recently, clot dissolution have been used. There is some evidence that aggressive treatment centered on active thrombolysis has produced improvements in clinical outcome (8, 9). Mortality appears to depend on the presentation and angiographic findings. Patients with a stuttering presentation of fluctuating mild neurologic deficits, short-segment basilar thromboses, and good collateral supply can do very well

without thrombolysis (7). A series of patients with more marked deficits, acute presentations, and extensive basilar thromboses had a 40% mortality with only 30% surviving with mild deficits even after thrombolysis (8), and an extreme group of 22 patients with acute presentations who all required mechanical ventilation, either for loss of airway control or for apneic episodes, had a uniformly poor outcome, with 88% mortality and all survivors “locked in” when treated with intravenous heparin (10).

Case Report

A 33-year-old male school teacher, normally fit and well, sustained two episodes of minor cervical trauma in the 3 weeks prior to admission to our unit. In the first, he had a low-velocity whiplash-type injury while go-carting, and in the second, 1 week later, his 3-year-old son jumped onto his chest and lower neck, causing an extension injury to the left side of his neck. Following these events, he reported intermittent severe headaches, left-sided neck pain, and nausea. Three days before admission to our unit, he went to a different hospital after an episode of complete blindness and dysarthria, followed by a brief collapse with loss of consciousness. This episode resolved within hours, to be replaced by positional nausea and vomiting and horizontal nystagmus. A diagnosis of viral labyrinthitis was made, and with symptomatic treatment he improved until the day of his admission to us, when he was found collapsed in the ward. His Glasgow Coma Scale (GCS) score was 6 (E1, V1, M4) with a dense right hemiparesis, fixed dilated left pupil (the right had unfortunately been exposed to mydriatic eye drops), uniformly brisk tendon reflexes, and bilaterally upgoing plantar responses. In transit to our unit, he had a further decline in his conscious level, to a GCS score of 4, with a weak extensor response to pain on the left side, intermittent airway obstruction, and arterial oxygen saturation of 90% on air. He tolerated an oropharyngeal airway without gagging, and his earlier neurologic signs persisted. He was emergently paralyzed, intubated, and ventilated and taken for a cranial CT scan, which showed high signal in the basilar artery, suggestive of thrombosis, but no evidence of low-signal change in the parenchyma.

Cerebral angiography was performed. Given the history of left-sided neck pain, the left vertebral artery was looked for first but could not be found and was assumed to have been dissected and occluded. The right vertebral artery was there-

Received May 27, 1997; accepted after revision January 17, 1998.

From the Department of Clinical Neurosciences, Western General Hospitals NHS Trust, Crewe Rd, Edinburgh EH4 2XU, Scotland.
Address reprint requests to Dr. R. Sellar.

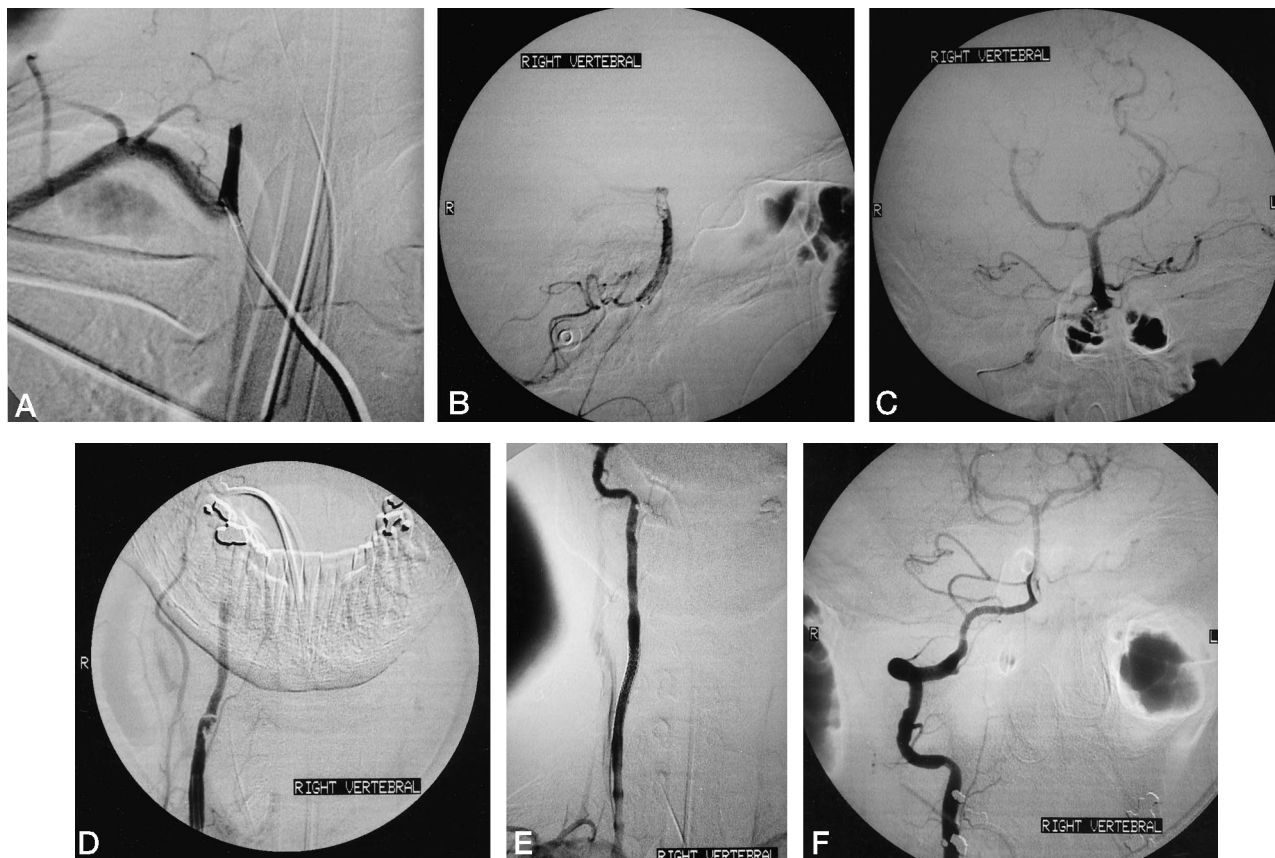


FIG 1. 33-year-old man with traumatic vertebral arterial dissection and vertebrobasilar arterial thrombosis.

- A, Right vertebral angiogram shows occlusion of the vessel 3 cm from its origin.
 B, Lateral right vertebral angiogram shows a large filling defect at the basilar tip.
 C, Anteroposterior right vertebral angiogram shows a patent vertebrobasilar tree with the exception of the superior cerebellar arteries.
 D, Anteroposterior right vertebral angiogram shows a complex intimal flap 12 cm from the vessel origin.
 E, Anteroposterior right vertebral angiogram shows the Strecker stent in place and a fully patent cervical vessel.
 F, Anteroposterior right vertebral angiogram shows a fully patent vertebrobasilar arterial tree, now including the superior cerebellar arteries.

fore catheterized and somewhat to our surprise was found to be occluded 3 cm from its origin (Fig 1A). Small (2-mg) aliquots of recombinant tissue plasminogen activator (rtPA) were injected to a total dose of 30 mg, sequentially dissolving the thrombus and reopening the right vertebral artery.

As this progressed, it became apparent that the entire length of the basilar artery had also been occluded from the outset. Even after extensive attempts with rtPA, a large clot at the basilar tip could not be chemically lysed (Fig 1B) and the microcatheter guidewire was used to break it up physically. At this point, good filling of most of the posterior cerebral circulation had been obtained, apart from both superior cerebellar arteries, which remained occluded (Fig 1C). It was decided to conclude thrombolysis; the microcatheter was removed, and a check angiogram performed, which showed rethrombosis of the right vertebral artery within minutes of terminating thrombolysis. Further thrombolysis followed with rtPA, when it became apparent that there was an intimal dissection 12 cm from the origin of the right vertebral artery with an intimal flap that was partially occluding the vessel lumen (Fig 1D). This was treated by placing a 4 cm \times 6 mm Strecker stent across the area of dissection to reappose intima and media (Fig 1E). A final check angiogram revealed good filling of the entire posterior cerebral circulation, including the superior cerebellar arteries (Fig 1F). Given the disease in his right vertebral artery and his initially left-sided symptoms, a further attempt was made to find the left vertebral artery, and an aberrant origin direct from the aortic arch was identified; the vessel was of small diameter,

but otherwise normal, and both carotid circulations were normal. The patient was anticoagulated with intravenous heparin for 48 hours, maintaining the activated partial thromboplastin time at 2.0 to 2.5 times control, followed by 3 months of oral warfarin therapy.

Within 10 hours of the procedure, the patient had regained the use of his paretic limbs and was obviously awake. Upon extubation, he was found to have a GCS score of 15, with mild dysarthria, diplopia due to a left fourth nerve palsy, and mid-line and hemispheric cerebellar signs in all four limbs. There were no complications during the remainder of his stay, and he was transferred 10 days later to our rehabilitation unit. At 1 month follow-up, his dysarthria was barely noticeable, but mild four-limb and truncal cerebellar signs persisted, his gait was slightly unsteady, and ophthalmologic examination revealed excyclotorsion, consistent with a residual left fourth nerve palsy. At 3 months follow-up, the patient had successfully returned to his job as a teacher, had no significant neurologic findings, and was weaned from his oral warfarin therapy without incident.

Discussion

Our patient had a typical presentation of vertebral arterial dissection, both in terms of the evolution of his symptoms and signs, and also in that the diagnosis

was not initially suspected. When he came to our institution, he was moribund and fell into the class of patients studied by Wijdicks and Scott (10) who carry a uniformly grim prognosis, and it was believed that thrombolysis represented his best hope of useful recovery. The majority of the experience with thrombolysis in this setting is with nonfibrin-specific agents (8), although experience with TPA, which we opted to use in this case, is growing (11–13). The only treatment endpoint available to us was angiographic demonstration of a restored circulation, since the patient was paralyzed and ventilated so that neurologic assessment was not possible. To minimize the risks of hemorrhage, we approached this endpoint slowly with the use of small aliquots of rTPA. It appears that intracerebral hemorrhage during thrombolysis is quite uncommon unless there is a preexisting low-attenuation lesion on CT scans, suggestive of a stroke, which can then go on to hemorrhagic modification. Indeed, finding such a lesion is probably a contraindication to thrombolysis (8). The use of a microcatheter guidewire to fragment thrombus resistant to chemical thrombolysis is controversial. We are not aware of any reports of intentional use of this maneuver in the literature, but several authors have described passing a microcatheter guidewire beyond an occluding thrombus in order to infuse thrombolytic agents centrally. In the course of this intervention, fragmentation of the thrombus has been observed, without undue neurologic sequelae for the patient (9, 14). Faced with our inability to chemically lyse this patient's distal basilar thrombus, we felt that the potential risk to the patient of distal embolization was less than that of leaving him with bilaterally occluded posterior cerebral and superior cerebellar arteries (Fig 1B), as well as with a large thrombus that could act as the nidus for reocclusion of the entire basilar artery. We therefore proceeded to fragment the embolus mechanically, and, fortunately, uneventfully.

In this case, we elected to stent the vertebral arterial dissection because there was a large intimal flap that was directly occluding the vessel lumen, leading to early rethrombosis. There is increasing experience with this technique after iatrogenic dissection of coronary arteries and of a variety of peripheral vessels (15–17), but we are aware of only a few reports of stenting of internal carotid and vertebral arterial dissections (18–20). We used anticoagulation for several reasons. First, the vessels in our patient had demonstrated a propensity for rethrombosing during the course of the procedure. Second, a basilar tip thrombus had been mechanically fragmented, potentially showering microemboli distally as well as leaving behind a patch of damaged intima. Finally, a thrombogenic metallic foreign body had been inserted into the region. Our protocol concords with those developed by cardiologists after coronary artery stenting, although they routinely use antiplatelet drugs as well (aspirin ticlopidine). However, evidence is accumulating that a single periprocedural dose of heparin com-

bined with antiplatelet drugs may be all that is necessary to prevent stent occlusion, thus avoiding the complications of several days of intravenous heparin and subsequent warfarin therapy (21).

Conclusion

Wijdicks and Scott (22) have recently concluded that patients who require mechanical ventilation after acute basilar artery thrombosis can be expected to progress to brain death, with significant implications for early management decisions. Our case shows that these patients can in fact survive and may have a good neurologic recovery if treated early and aggressively. While we feel that our intervention in this case was life-saving, it will be difficult to prove this rigorously with a controlled trial, given the rarity of such patients. A Bayesian approach to this condition, as recently proposed by Lilford et al (23), may help to optimize treatment strategies in the future.

References

1. Morgan MK, Sekhon LHS. Extracranial-intracranial saphenous vein bypass for carotid or vertebral artery dissections: a report of six cases. *J Neurosurg* 1994;80:237–246
2. Anson J, Crowell RM. Cervicocranial arterial dissection. *Neurosurgery* 1991;29:89–95
3. Bogousslavsky J, Regli F. Ischaemic stroke in adults younger than 30 years of age. *Arch Neurol* 1987;44:479–482
4. Blunt SB, Galton C. Cervical carotid or vertebral artery dissection. *BMJ* 1997;314:243
5. Sherman DG, Hart RG, Easton JD. Abrupt change in head position and cerebral infarction. *Stroke* 1981;12:3–6
6. Mokri B, Sundt TM Jr, Houser OW, Piepgras DG. Spontaneous dissection of the cervical internal carotid artery. *Ann Neurol* 1986;19:126–138
7. Brandt T, Pessin MS, Kwan ES, Caplan LR. Survival with basilar artery occlusion. *Cerebrovasc Dis* 1995;5:182–187
8. Zeumer H. Fibrinolysis in cerebrovascular diseases of the central nervous system. In: *Interventional Neuroradiology: Endovascular Therapy of the Central Nervous System*. New York: Raven Press; 1992:141–152
9. Hacke W, Zeumer H, Ferbert A, Bruckmann H, del Zoppo GJ. Intra-arterial thrombolytic therapy improves outcome in patients with acute vertebrobasilar occlusive disease. *Stroke* 1988;19:1216–1222
10. Wijdicks EFM, Scott JP. Outcome in patients with acute basilar artery occlusion requiring mechanical ventilation. *Stroke* 1996;27:1301–1303
11. Henze TH, Boer A, Tebbe U, Romatowski J. Lysis of basilar artery occlusion with tissue plasminogen activator. *Lancet* 1987;2:1391
12. Buteaux G, Jubault V, Suisse A. Local recombinant tissue plasminogen activator to clear cerebral artery thrombosis developing soon after surgery. *Lancet* 1988;2:1143–1144
13. Kwan ES, Kwon OJ, Borden JA. Successful thrombolysis in the vertebrobasilar artery after endovascular occlusion of a recently ruptured large basilar tip aneurysm. *AJNR Am J Neuroradiol* 1995;16:847–851
14. Goto K, Ogata N. "Central" intraarterial thrombolysis using a newly developed low friction guidewire/catheter system. In: *Thrombolytic Therapy in Acute Ischaemic Stroke III*. Tokyo: Springer; 1995:301–306
15. Becker GJ, Palmaz JC, Rees CR, et al. Angioplasty-induced dissection in human iliac arteries: management with Palmaz balloon-expandable intraluminal stents. *Radiology* 1990;176:31–38
16. Kuntz RE, Baim DS. Defining coronary stenosis: newer clinical and angiographic paradigms. *Circulation* 1993;88:1310–1323
17. Schmitter SP, Marx M, Bernstein R, Wack J, Semba C, Dake MD.

- Angioplasty-induced subclavian artery dissection in a patient with internal mammary artery graft: treatment with endovascular stent and stent-graft.** *AJR Am J Roentgenol* 1995;165:449–451
18. Marks MP, Dake MD, Steinberg GK, Norbash AM, Lane B. **Stent placement for arterial and venous cerebrovascular disease: preliminary experience.** *Neuroradiology* 1994;191:441–446
19. Higashida RT, Tsai FY, Halbach VV, Dowd CF, Hieshima GB. **Transluminal angioplasty, thrombolysis and stenting for extracranial and intracranial cerebral vascular disease.** *J Intervent Cardiol* 1996;9:245–255
20. Eckard DA, Lee G, Tsai F. **The implication of stents and cyanoacrylates for the treatment of cerebrovascular disease.** In: Maciunas RJ, ed. *Endovascular Neurologic Intervention*. Park Ridge, IL: American Association of Neurologic Surgeons; 1994:159–177
21. Mehan VK, Salzmann C, Kaufmann M, Meier B. **Coronary artery stenting without anticoagulation.** *Cathet Cardiovasc Diagn* 1995;34:137–140
22. Wijedicks EFM, Scott JP. **Outcome in patients with acute basilar artery occlusion requiring mechanical ventilation.** *Stroke* 1996;8:1301–1303
23. Lilford RJ, Thornton JG, Braunholz D. **Clinical trials and rare diseases: a way out of a conundrum.** *BMJ* 1995;311:1621–1625