

Generic Contrast Agents

Our portfolio is growing to serve you better. Now you have a *choice*.



FRESENIUS
KABI

[VIEW CATALOG](#)

AJNR

Total Myelography with Metrizamide through the Lumbar Route

Afra Khan, Joseph A. Marc, Michael Chen and Joseph A. Epstein

AJNR Am J Neuroradiol 1981, 2 (1) 85-90

<http://www.ajnr.org/content/2/1/85>

This information is current as
of May 17, 2025.

Total Myelography with Metrizamide through the Lumbar Route

Afra Khan¹
Joseph A. Marc¹
Michael Chen¹
Joseph A. Epstein²

Myelography of the entire spinal cord was performed in 64 consecutive patients using metrizamide via lumbar puncture. Adequate to good opacification of the cervical and thoracic subarachnoid space was obtained in 63 patients. The technical factors responsible for this success rate are patient cooperation, high iodine concentration (250 mg/ml), slow injection rate, delayed removal of the needle, minimal patient motion, and rapid performance. Side effects were minor and no more frequent than with lumbar metrizamide myelography alone. Adequate hydration before and after and upright position after seem to be important in minimizing adverse effects.

Metrizamide, a water-soluble, nonionic contrast agent for myelography, has received wide acceptance [1-17]. Although lumbar myelography has been its major application, its use for cervical and dorsal myelography is less enthusiastically accepted. This has been due to inadequate visualization of the thoracic and cervical area using a lumbar injection. Consequently, many have advocated C1-C2 puncture for cervical myelography [1, 3, 4, 7, 8, 14]. We describe a technique, initiated by one of us (J. M.), for total metrizamide myelography performed by the lumbar route. The efficacy of this method is substantiated in a series of 64 patients.

Technique

The 64 consecutive patients in this study included 32 men and 32 women aged 18-75 years. The most frequent indications for the myelography were suspected herniated lumbar disc, spinal stenosis, and spondylosis. Preparation included maintenance of adequate hydration; a liquid diet was permitted until 2 hr before the procedure. No premedication was given.

Lumbar puncture is performed with the patient prone. The point of entry is fluoroscopically located at L2-L3 or L3-L4 interspace and a 20 gauge spinal needle is introduced into the subarachnoid space. With the head of the table elevated 15°-30°, 4-8 ml of spinal fluid is withdrawn and 10-12 ml of metrizamide (iodine 250 mg/ml) is injected very slowly into the subarachnoid space over at least 3-5 min. The needle is left in place to avoid leakage through the puncture site. The table is then slowly brought to an upright position and spot films of the lumbar region in anteroposterior, both oblique, and lateral views are obtained. The table is then returned to the horizontal position, and anteroposterior, oblique, and cross-table lateral views of the lumbar subarachnoid space are obtained as indicated.

With the patient still prone and the neck extended, the contrast medium is transferred from lumbar to cervical region by tilting the head of the table steeply downward. Anteroposterior views of the low and midthoracic subarachnoid space are obtained as the contrast material flows to the cervical region. Rapid and smooth downward movement of the table is essential in order to preserve useful

Received May 15, 1980; accepted after revision July 24, 1980.

Presented at the annual meeting of the American Roentgen Ray Society, Las Vegas, April 1980.

¹ Department of Radiology, Long Island Jewish-Hillside Medical Center, New Hyde Park, NY 11042. Address reprint requests to A. Khan.

² Department of Neurosurgery, Long Island Jewish-Hillside Medical Center, New Hyde Park, NY 11042.

This article appears in January/February 1981 *AJNR* and April 1981 *AJR*.

AJNR 2:85-90, January/February 1981
0195-6108/81/0021-0085 \$00.00
© American Roentgen Ray Society

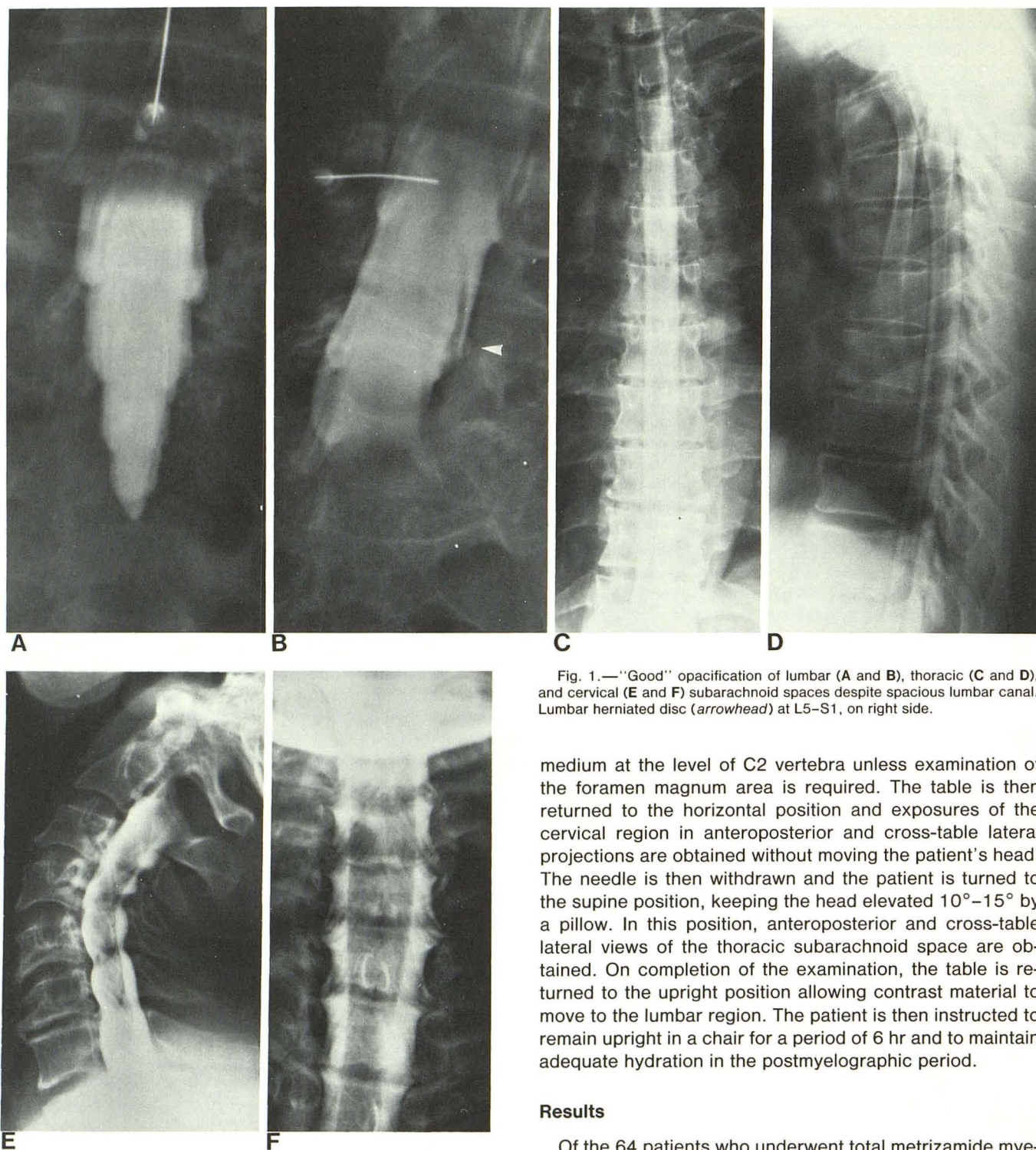


Fig. 1.—“Good” opacification of lumbar (A and B), thoracic (C and D), and cervical (E and F) subarachnoid spaces despite spacious lumbar canal. Lumbar herniated disc (arrowhead) at L5–S1, on right side.

medium at the level of C2 vertebra unless examination of the foramen magnum area is required. The table is then returned to the horizontal position and exposures of the cervical region in anteroposterior and cross-table lateral projections are obtained without moving the patient's head. The needle is then withdrawn and the patient is turned to the supine position, keeping the head elevated 10° – 15° by a pillow. In this position, anteroposterior and cross-table lateral views of the thoracic subarachnoid space are obtained. On completion of the examination, the table is returned to the upright position allowing contrast material to move to the lumbar region. The patient is then instructed to remain upright in a chair for a period of 6 hr and to maintain adequate hydration in the postmyelographic period.

Results

Of the 64 patients who underwent total metrizamide myelography via lumbar puncture, opacification of cervical and thoracic subarachnoid space was graded good in 57 (89%), fair in six (9%), and poor in one (1.6%). In all cases visualization of the lumbar region was good. Image quality of the nerve roots and sleeves, the subarachnoid space, and the spinal cord were used as criteria for grading. In examinations characterized as good, the root sleeves were well filled and the nerve roots could be seen across the subarachnoid

contrast medium concentration. Dilution of metrizamide by cerebrospinal fluid is also minimized by maintaining the patient's position and avoiding excessive patient movement.

The arrival of contrast medium in the cervical region is controlled with fluoroscopy, and a tilted position of the table maintained for 1–2 min until maximum filling of the cervical space is achieved. Attempt is made to arrest the contrast

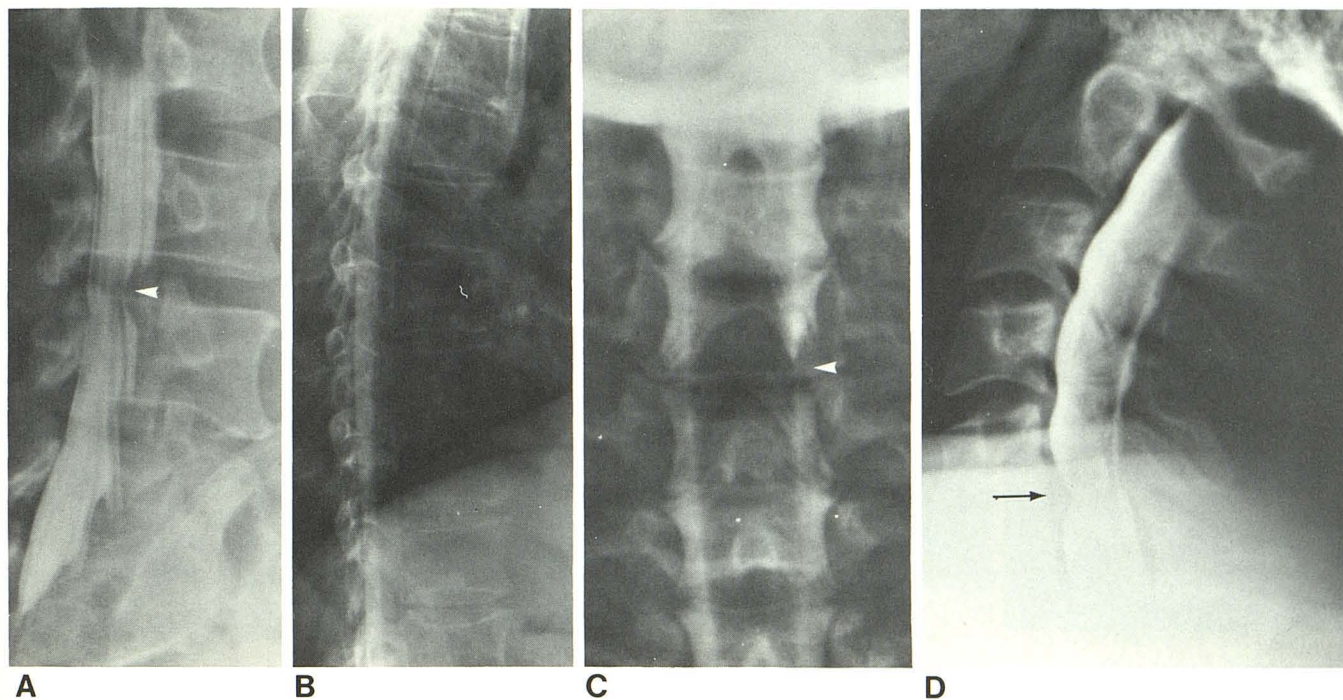


Fig. 2.—43-year-old woman with low back pain and right sciatica. **A**, Oblique view, lumbar myelogram. Herniated disc at L4–L5 (arrowhead). **B**, Thoracic myelogram, lateral view. Anteroposterior (**C**) and lateral (**D**) views of cervical myelogram. Herniated disc at C5–C6 on right side (arrowhead, arrow).

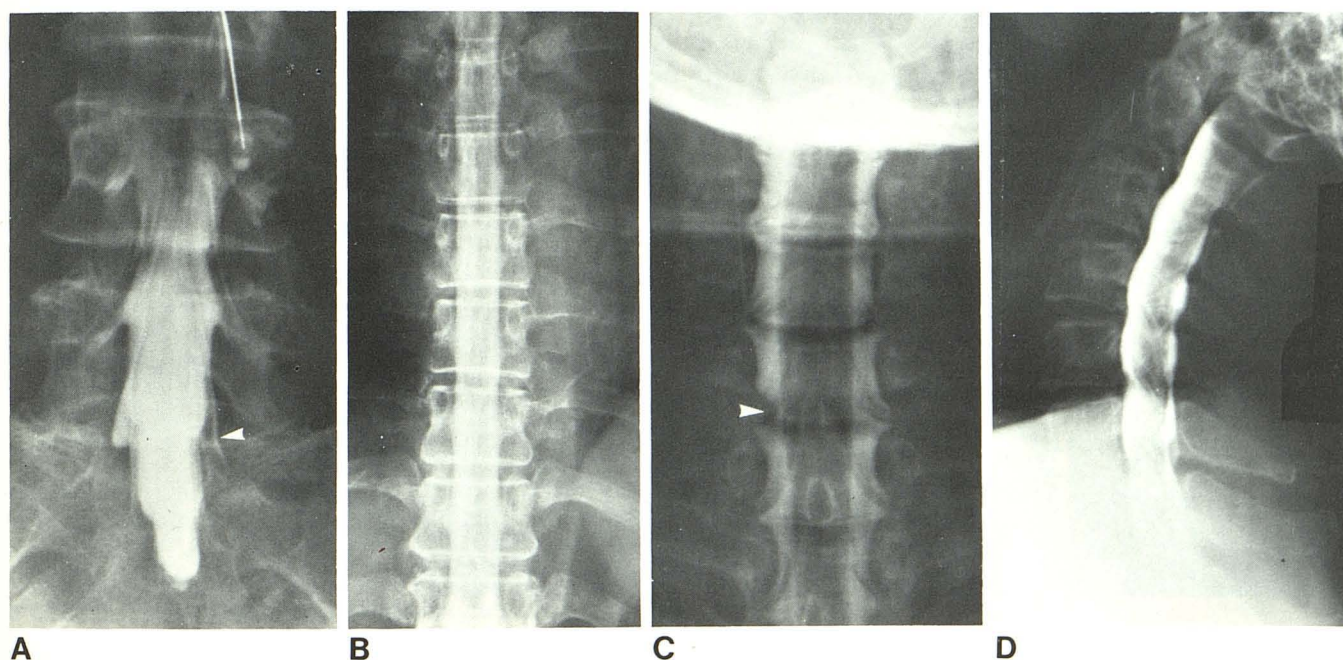


Fig. 3.—56-year-old woman with right sciatica. **A**, Anteroposterior view of lumbar myelogram. Herniated disc at L5–S1 on right side (arrowhead). **B**, Thoracic myelogram, anteroposterior view. Anteroposterior (**C**) and lateral (**D**) views of cervical myelogram. Amputation of nerve rootlets at level of C5–C6 on left side (arrowhead).

space to their origins. The spinal cord was sharply outlined and the subarachnoid space was densely opacified (figs. 1–5). Of the six cases judged fair, three patients were obese, one had kyphoscoliosis, and one was unable to cooperate

due to multiple rib fractures. In the one case of poor cervical and thoracic visualization, extreme dorsal kyphosis led to interrupted flow and increased dilution of the contrast medium.

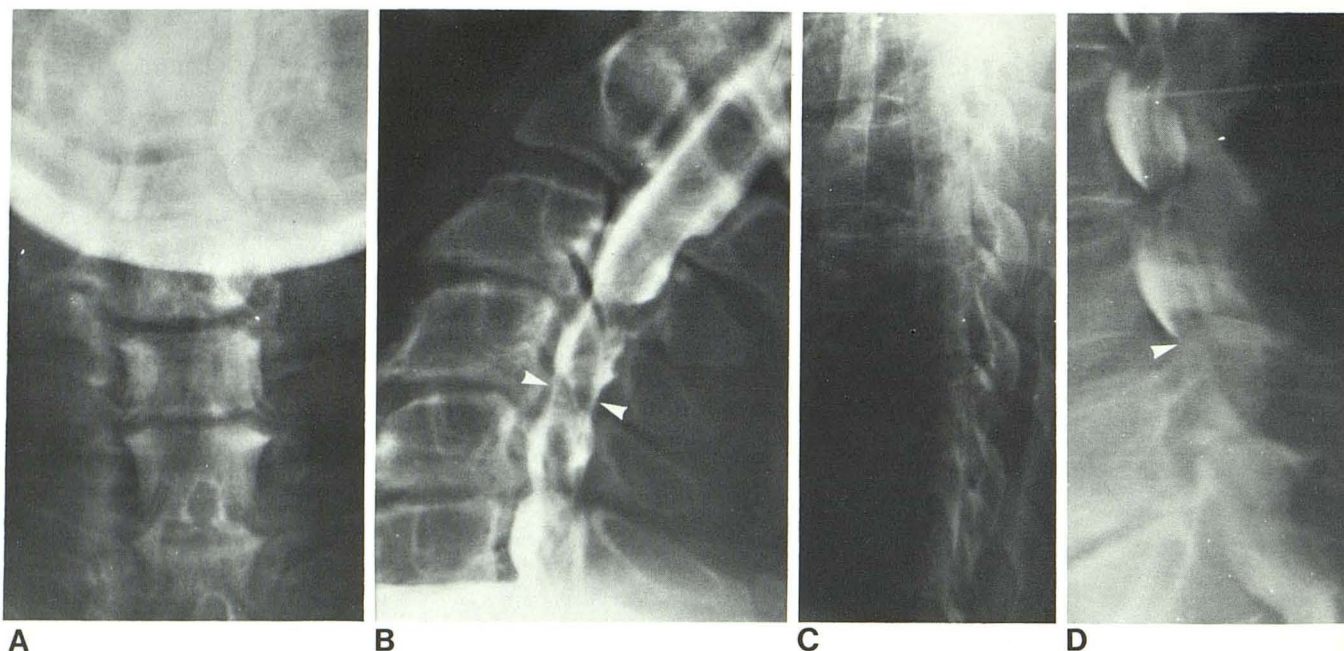


Fig. 4.—67-year-old man with deteriorating ambulation. Anteroposterior (A) and lateral (B) views of cervical myelogram. Stenosis of lower cervical

canal (arrowheads). C, Thoracic myelogram, lateral view. D, Lumbar myelogram, lateral view. Spinal stenosis with partial block at L4–L5 (arrowhead).

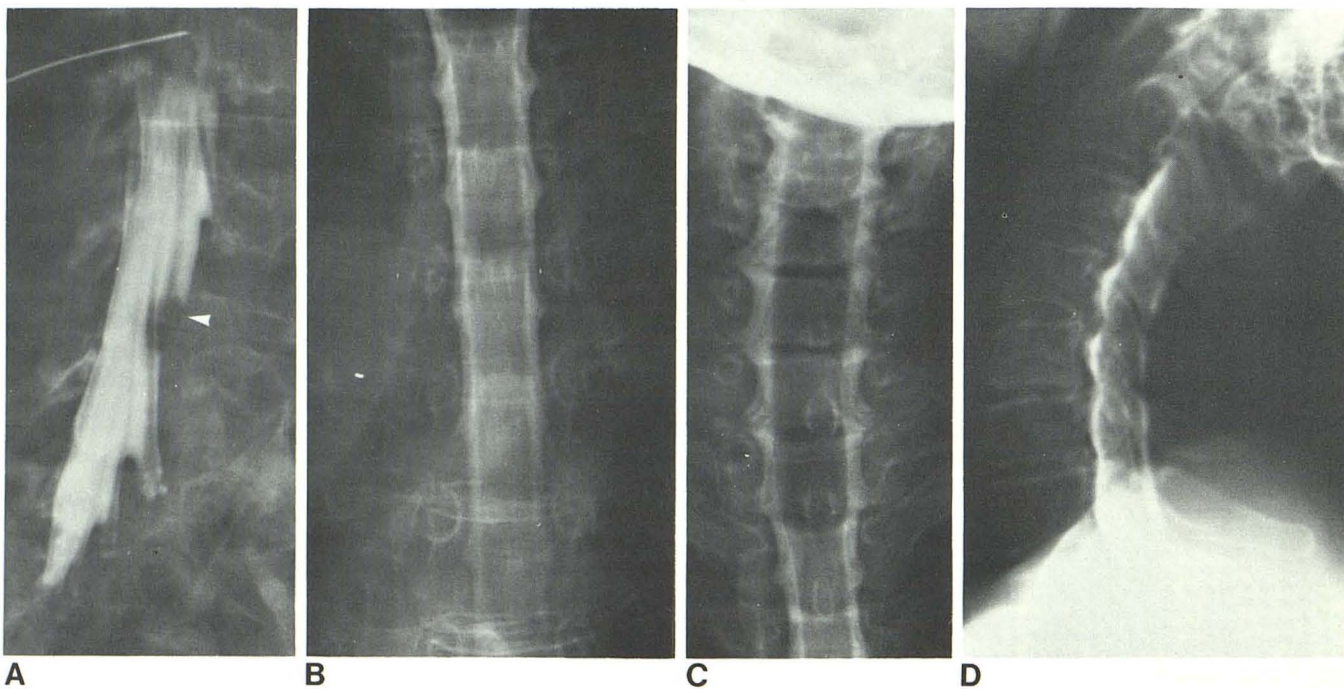


Fig. 5.—54-year-old woman with low back pain and right lower leg radiculitis. A, Lumbar myelogram, oblique view. Herniated disc at L4–L5 (arrowhead). B, Anteroposterior view of thoracic myelogram. Anteroposterior

(C) and lateral (D) views of cervical myelogram. Significant spinal cord widening at T2–C2.

The side effects were minor and included nausea, vomiting, and headache. The frequency of side effects was not found to be any greater than those reported or in those patients in whom we have examined only the lumbar region with metrizamide. Two patients developed mental confusion and disorientation that lasted 24 hr; both had ignored the

instructions to maintain the upright position after the procedure.

Discussion

The superiority of metrizamide over any previous positive contrast agent for myelography is now widely accepted [1–

17]. It fulfills many of the demands made of the ideal contrast medium for myelography set forth by Di Chiro and Fisher in 1964 [18]. One problem has been inadequate cervical and thoracic visualization using the lumbar injection. Modified techniques and equipment have been used with variable results. Hindmarsh [9] used the lumbar route with the patient in the lateral recumbent position, strapped in a rotating chair. The contrast medium was allowed to flow to the cervical region; the patient was then placed prone and anteroposterior films were taken. For examination of the nerve roots on the contralateral side, the patient had to be turned to the other side. An additional injection of contrast medium was then usually required. In addition, tomography was performed in order to obtain good visualization of the cervical region.

Sortland [10] used lumbar injection with transportation of the contrast medium into the cervical region with the patient prone and the neck hyperextended. Sufficient contrast medium concentration for diagnostic purposes was seen with anteroposterior and lateral tomography. In four patients with poor diagnostic films, three had increased thoracic kyphosis and one had a stenosis in the lumbar region above the level of the puncture.

Sortland and Skälpe [11] compared the diagnostic quality of cervical myelography by C1–C2 and lumbar injection and found that a high diagnostic yield was obtained by both methods. However, the lumbar injection was less hazardous. The cervical route offered films of higher quality in patients with stiff neck or marked dorsal kyphosis. No difference in adverse effects was noted in the two series.

The experience of Skälpe and Amundsen [12] was different from that of Hindmarsh [9] and Sortland [10, 11]. Although high quality myelograms in the lumbar and thoracic region were obtained through lumbar injection, cervical myelograms were unsatisfactory due to dilution of the contrast medium. Subsequently, a C1–C2 puncture was used.

Cronquist and Brismar [13] reported the results of 190 cervical myelograms with metrizamide, 52 after C1–C2 puncture and 138 after lumbar injection. While the latter technique was considered safer, the first caused fewer adverse reactions and offered films of higher quality.

Sackett et al. [14] evaluated 215 patients with metrizamide myelography. Cervical myelography was performed by C1–C2 puncture, thoracic and lumbar by lumbar puncture. Increase in side effects from 64% to 74% was observed when cervical myelography was performed by the lumbar route.

Boyd and Gardiner [15] performed complete myelography using metrizamide and lumbar puncture in 20 patients. Good visualization of the cervical region was obtained in 19 of 20 patients. In one case of poor cervical visualization, the concentration of contrast material was inadequate because of an abnormally large subarachnoid space.

In our series of 64 patients with total metrizamide myelograms through the lumbar route, diagnostic quality films of the cervical and thoracic canal were obtained in 98%. An important factor in obtaining good quality myelograms of the thoracic and cervical region with metrizamide is the prevention of contrast dilution by the cerebrospinal fluid. This is

accomplished by maintaining the contrast as a bolus and minimizing cerebrospinal fluid turbulence. In our experience the following factors are important in achieving these objectives:

1. Patient selection. The patient must be alert, cooperative, and responsive to positional instructions. Unsatisfactory image quality was most frequently encountered in (1) patients with marked dorsal kyphosis; (2) patients with limited range of motion of the cervical spine; and (3) obese patients.

2. High iodine concentration. Since some dilution necessarily occurs during the passage from the lumbar to the cervical region, it is an advantage to commence the examination with high iodine concentration (at least 250 mg iodine/ml).

3. Slow injection rate. Injection time of 3–5 min decreases turbulence of cerebrospinal fluid thereby minimizing dilution.

4. Delayed removal of the spinal needle prevents leakage of contrast material through the needle tract.

5. Minimal patient motion and positioning.

6. Rapid performance of the procedure. Total examination time should not exceed 30 min. This allows good quality films to be obtained before contrast dilution.

The minimal adverse effects were well tolerated. We believe that this is related to proper hydration of the patient before and after the procedure, and maintenance of an upright position for at least 6 hr after the examination. The contrast medium should be arrested at C2 level unless specific examination of the foramen magnum is necessary, thereby preventing medium from entering the cranial cavity.

REFERENCES

1. Gonsette RE. Metrizamide as a contrast medium. *Acta Radiol [Suppl]* (Stockh) **1973**;335:346–358
2. Hindmarsh T. Myelography with the non-ionic water soluble contrast medium metrizamide. *Acta Radiol [Suppl]* (Stockh) **1975**;16:417–435
3. Amundsen P, Skälpe IO. Cervical myelography with a water-soluble contrast (metrizamide). A preliminary clinical report with special reference to technical aspects. *Neuroradiology* **1975**;8:209–212
4. Skälpe IO, Sortland O. Thoracic myelography with metrizamide. *Acta Radiol [Suppl]* (Stockh) **1977**;355:57–61
5. Grainger RG, Kendall BE, Wylie IG. Lumbar myelogram with metrizamide—a new non-ionic contrast medium. *Br J Radiol* **1976**;49:996–1003
6. Hansen EB, Praestholm J, Fahrenkrug A, Bjerrum J. A clinical trial of Amipaque in lumbar myelography. *Br J Radiol* **1976**;49:34–38
7. Ahlgren P. Myelography with metrizamide in the cervical region. *Acta Radiol [Suppl]* (Stockh) **1977**;355:98–104
8. Amundsen P. Metrizamide in cervical myelography—survey and present state. *Acta Radiol [Suppl]* (Stockh) **1977**;355:85–97
9. Hindmarsh T. Metrizamide in selective cervical myelography. *Acta Radiol [Suppl]* (Stockh) **1977**;355:127–134
10. Sortland O. Cervical myelography with metrizamide using lumbar injection. *Acta Radiol [Suppl]* (Stockh) **1977**;355:141–153
11. Sortland O, Skälpe IO. Cervical myelography by lateral cervical

- and lumbar injection of metrizamide—a comparison. *Acta Radiol [Suppl]* (Stockh) **1977**;355:154–163
12. Skälpe IO, Amundsen P. Thoracic and cervical myelography with metrizamide. *Radiology* **1975**;116:101–106
 13. Cronquist S, Brismar J. Cervical myelography with metrizamide. *Acta Radiol [Suppl]* (Stockh) **1977**;355:110–120
 14. Sackett JF, Strother MC, Quaglieri CE, Javid MJ, Levin AB, Duff TA. Metrizamide—C.S.F. contrast medium. *Radiology* **1977**;123:779–782
 15. Boyd WR, Gardiner GA. Metrizamide myelography. *AJR* **1977**;129:481–484
 16. Valk J. Myelography with metrizamide (Amipaque). *Medicamundi* **1976**;21:164–177
 17. Valk J. Thoracic myelography with metrizamide. *Acta Radiol [Suppl]* (Stockh) **1977**;355:77–82
 18. Di Chiro G, Fisher RL. Contrast radiography of the spinal cord. *Arch Neurol* **1964**;11:125–143