



Get Clarity On Generics

Cost-Effective CT & MRI Contrast Agents



FRESENIUS
KABI

WATCH VIDEO

AJNR

Metrizamide myelography for disk disease: continuing need for epidural venography.

T F Stephenson

AJNR Am J Neuroradiol 1981, 2 (3) 255-259

<http://www.ajnr.org/content/2/3/255>

This information is current as
of August 8, 2025.

Metrizamide Myelography for Disk Disease: Continuing Need for Epidural Venography

Thomas F. Stephenson¹

Metrizamide is largely replacing iophendylate (Pantopaque) for routine lumbar myelography. Better visualization of the nerve root sheaths should make metrizamide myelography more sensitive in detecting laterally herniated disks, such that epidural venography might be required less often. However, that expectation has not been realized. In over 800 consecutive myelograms, one-half obtained with iophendylate and one-half obtained with metrizamide, 60 patients still required epidural venography. Nearly as many had metrizamide as had iophendylate (28 versus 32). Further, the number of positive epidural venograms with herniated disks confirmed at surgery was not significantly different (12 versus 11). Epidural venography is still indicated after negative or equivocal metrizamide myelography if strong clinical suspicion of herniated disk persists.

At many institutions, metrizamide, a water-soluble nonionic contrast agent, has replaced iophendylate (Pantopaque) in lumbar myelography [1-7]. Unlike iophendylate, metrizamide is miscible with cerebrospinal fluid and passes out along the nerve root sleeves for a greater distance. Because of this better visualization of nerve roots and nerve root sleeves, a greater sensitivity for detecting laterally herniated intervertebral disks might be anticipated. Thus, epidural venography could be expected to be required less often after metrizamide myelography. To evaluate this expectation, over 800 consecutive myelograms, one-half with iophendylate and one-half with metrizamide, were reviewed.

Materials and Methods

Since January 1979, lumbar myelography at this institution has been performed exclusively using metrizamide. The two 14 month periods before and after this date were compared (table 1). Over 800 myelograms were obtained, one-half with iophendylate and one-half with metrizamide. Sixty patients with a strong clinical suspicion of lumbar disk disease were subsequently referred for epidural venography because of negative or equivocal myelograms. Iophendylate myelograms were obtained with 9-12 ml of contrast material. Metrizamide myelograms used 6.75 g of metrizamide in isotonic dilution. Routine views include posteroanterior, lateral, and oblique projections in the supine position and an erect extension lateral view. These were supplemented by decubitus and cross-table oblique films if the nerve root sheaths were not already well demonstrated. Supplemental views were required less often with metrizamide. To mix the metrizamide with cerebrospinal fluid, patients were rolled 360° twice after the injection but before radiography. This usually provided opacification of the entire cerebrospinal fluid space at the level of interest, eliminating the need for decubitus and cross-table views. These views were sometimes necessary to opacify the area of interest with non-cerebrospinal fluid-miscible, markedly hyperbaric, iophendylate.

Epidural venography was performed with a 5 French polyethylene catheter and injection of 20-40 ml of Conray 60% at 5-8 ml/sec into an ascending lumbar or presacral vein. Usually the femoral vein corresponding to the side of the patient's greatest symptoms was catheterized; generally there was bilateral opacification of the epidural veins of the lower

Received August 26, 1980; accepted after revision November 6, 1980.

¹Department of Radiology, St. Mary's Hospital, 89 Genesee St., Rochester, NY 14611.

AJNR 2:255-259, May/June 1981
0195-6108/81/0203-0255 \$00.00
© American Roentgen Ray Society

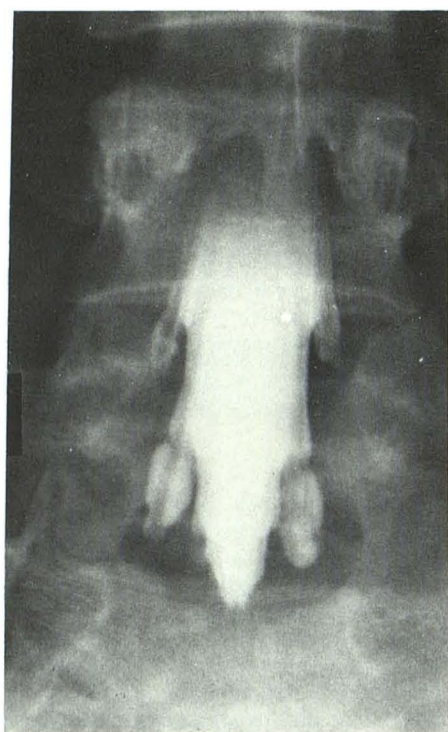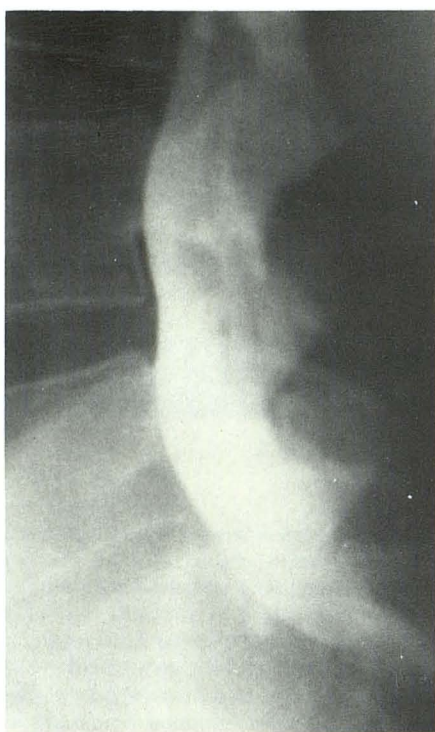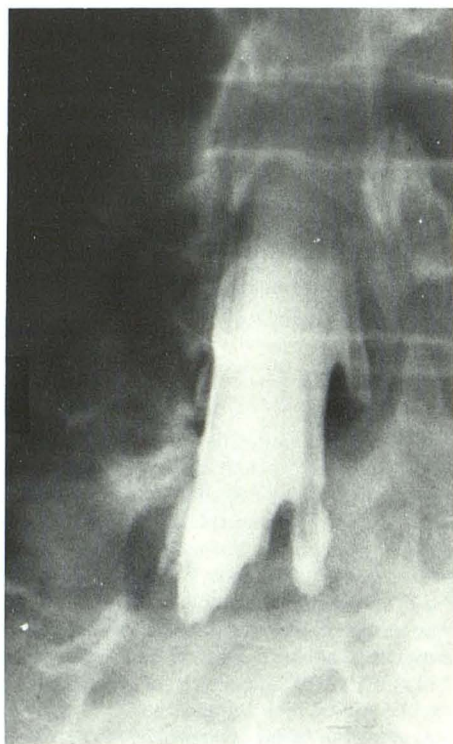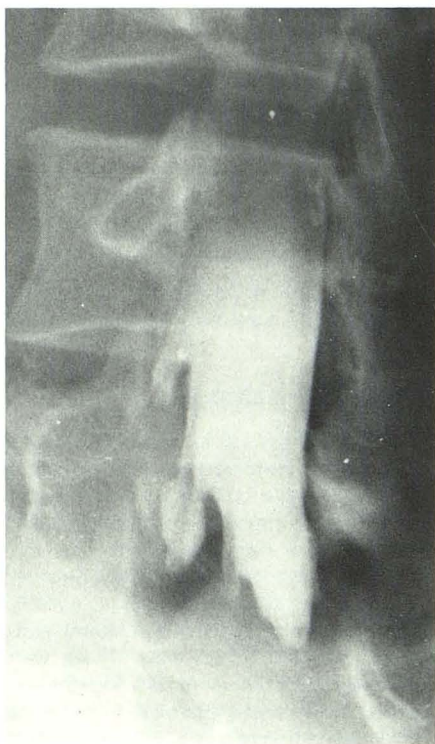
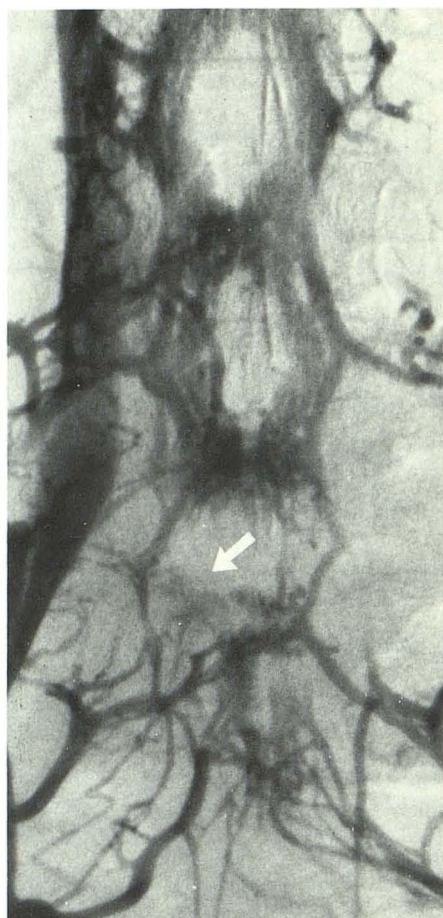
**A****B****C****D****E**

Fig. 1.—A-D, Metrizamide myelograms, several views. No abnormality at L4-L5 or L5-S1 levels. E, Epidural venogram. Interruption of anterior internal vertebral vein on right at L5-S1 (arrow). At surgery, a herniated disk was confirmed at this site.

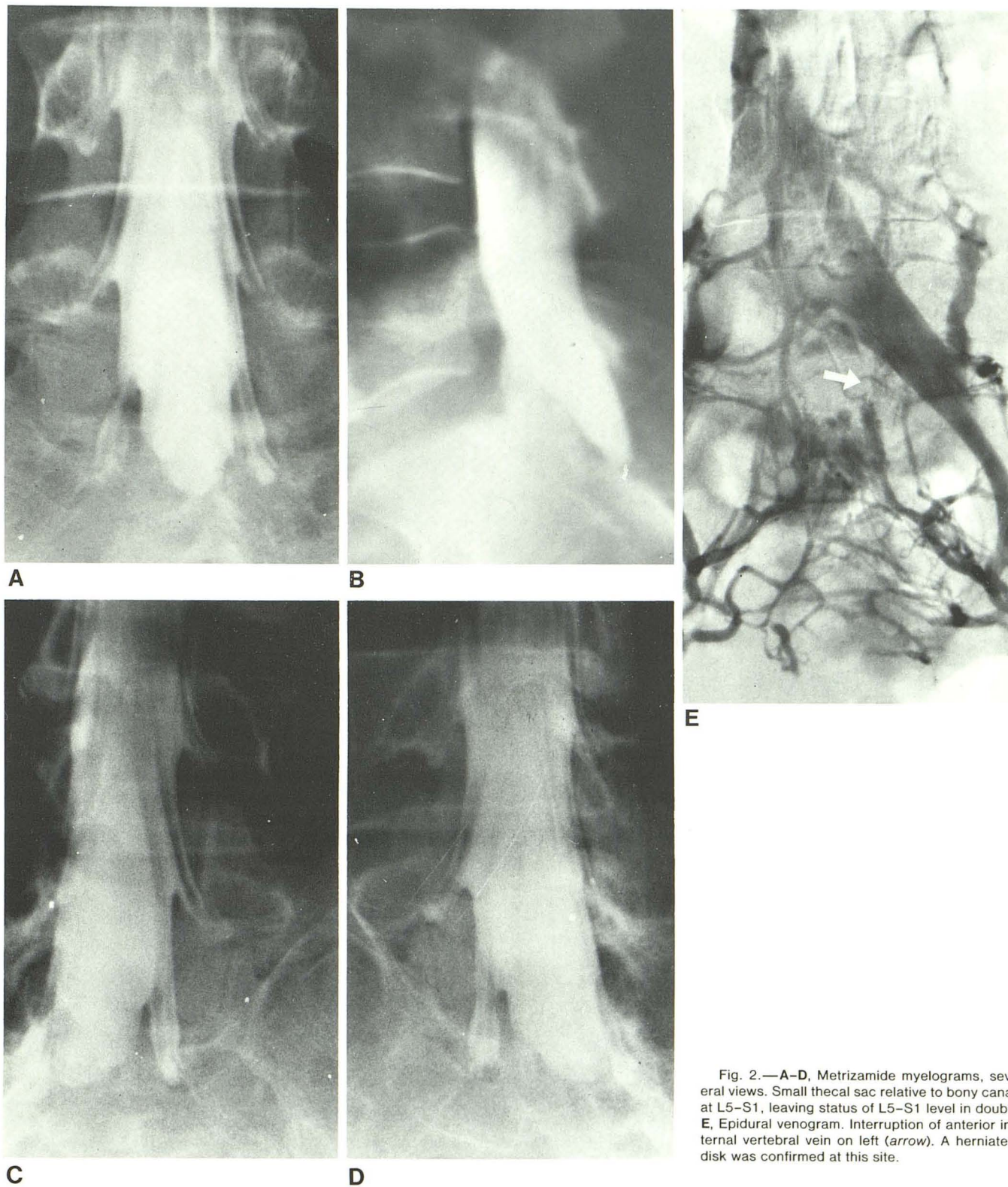


Fig. 2.—A-D, Metrizamide myelograms, several views. Small thecal sac relative to bony canal at L5-S1, leaving status of L5-S1 level in doubt. E, Epidural venogram. Interruption of anterior internal vertebral vein on left (arrow). A herniated disk was confirmed at this site.

TABLE 1: 806 Consecutive Lumbar Myelograms; 60 Subsequent Epidural Venograms

| Study | Myelographic Contrast Agent | |
|---|-----------------------------|-------------|
| | Iophendylate* | Metrizamide |
| Myelograms | 400 | 406 |
| Positive epidural venograms: | | |
| Treated conservatively | 7 | 3 |
| Confirmed at surgery | 11 | 12 |
| Unconfirmed at surgery (false-positives) | 0 | 1 |
| Subtotal | 18 | 16 |
| Negative epidural venograms: | | |
| Treated conservatively | 12 | 12 |
| With herniated disk at surgery (false-negative) | 2 | 0 |
| Subtotal | 14 | 12 |
| Total | 32 | 28 |

* Pantopaque.

lumbar region. This was facilitated by abdominal compression of the inferior vena cava and performance of a Valsalva maneuver during filming. Films were obtained in the anteroposterior projection and occasionally in the lateral projection at a rate of 1 exposure/sec for 10 sec. Segmental obstruction or displacement of the anterior internal vertebral veins and the intervertebral veins was noted in cases of disk herniation as previously reported [8-17].

Results

As shown in table 1, nearly equal numbers of myelograms were obtained during the two 14 month periods before and after the introduction of metrizamide. There was a slightly different number of patients referred for epidural venography after metrizamide myelography (28 after; 32 before). The rates of positive epidural venograms were nearly identical (57% after; 56% before). Fewer patients with positive epidural venograms were treated conservatively after metrizamide (three versus seven), possibly reflecting increased confidence in the results of epidural venography. A similar number of patients had positive venograms confirmed as herniated disks at surgery (12 versus 11). There were one false-positive venogram and two false-negative venograms, as judged by surgery in the group of 60 patients undergoing epidural venography. The number of negative epidural venograms (not surgically confirmed) was similar in each group (12 after; 14 before).

Discussion

Epidural venography has been found useful for recognizing herniated lumbar disks when the myelogram is equivocal or negative [8-11]. Gershater and Holgate [12] recommended venography as the procedure of choice but lack of a significant difference in the accuracy of the two procedures and consideration of technical and economic factors led Lotz and others [18] to recommend that transfemoral

epidural venography not replace iophendylate myelography as the primary investigation. The availability of metrizamide has made lumbar myelography easier, giving further priority to myelography over venography. However, cases still occur with negative or equivocal metrizamide myelograms and surgically verified herniated disks. Laterally herniated disks may not impinge on relatively short nerve root sleeves despite their more complete visualization with metrizamide (fig. 1). In addition, there remain patients with a short dural sac terminating at L5-S1 or above with a small thecal sac relative to the bony canal at L5-S1, obscuring a disk herniation within the anterior soft tissue space (fig. 2). These situations can often be resolved by epidural venography. In our experience, anticipated improved sensitivity with metrizamide has not been significant. Epidural venography is still indicated following a negative or equivocal myelogram with either iophendylate or metrizamide when there is a strong clinical suspicion of lumbar disk disease.

ACKNOWLEDGMENTS

I thank George Paul for assistance, Joan Baker and Betty Kern for technical assistance, and Sandy Johnson and Deborah Meritt for assistance in manuscript preparation.

REFERENCES

- Hindmarsh T. Myelography with non-ionic water soluble contrast medium metrizamide. *Acta Radiol [Diagn]* (Stockh) **1975**;16:417-435
- Berg Hansen E, Praestholm J, Fahrenkrug A, Bjerrum J. Clinical trial of amipaque in lumbar myelography. *Br J Radiol* **1976**;49:34-38
- Grainger RG, Kendall BE, Wylie IG. Lumbar myelography with metrizamide—new non-ionic contrast medium. *Br J Radiol* **1976**;49:996-1003
- Skolpe IO, Amundsen P. Lumbar radiculography with metrizamide: a nonionic water soluble contrast medium. *Radiology* **1975**;115:91-95
- Sackett JF, Strother CM, Quaglieri CE, Javid MJ, Levin AB, Duff TA. Metrizamide—CSF contrast medium: analysis of clinical application in 215 patients. *Radiology* **1977**;123:779-782
- Boyd WR, Gardiner GA. Metrizamide myelography. *AJR* **1977**;129:481-484
- Kieffer SA, Binet EF, Esguerra JV, Hantman RP, Gross CE. Contrast agents for myelography: clinical and radiological evaluation of amipaque and pantopaque. *Radiology* **1978**;129:695-705
- Gargano FP, Meyer JD, Sheldon JJ. Transfemoral ascending lumbar catheterization of the epidural veins in the lumbar disk disease. Clinical application and results in the diagnosis of herniated intervertebral disks of the lumbar spine. *Radiology* **1974**;111:329-336
- Miller MH, Handel SF, Coan JD. Transfemoral lumbar epidural venography. *AJR* **1976**;126:1003-1009
- Macnab I, St. Louis EL, Grabias SL, Jacob R. Selective ascending lumbosacral venography in the assessment of lumbar disk herniation. An anatomical study and clinical experience. *J Bone Joint Surg [Am]* **1976**;58:1093-1098
- Roland J, Treil J, Larde D, Picard L, Manelfe C. Lumbar

- phlebography in the diagnosis of disc herniations. *J Neurosurg* **1978**;49:544-550
12. Gershater R, Holgate RC. Lumbar epidural venography in the diagnosis of disc herniations. *AJR* **1976**;126:992-1002
 13. Theron J, Houtteville JP, Ammerich H, et al. Lumbar phlebography by catheterization of the lateral sacral and ascending lumbar veins with abdominal compression. *Neuroradiology* **1976**;11:175-182
 14. O'Dell CW Jr, Coel MN, Ignelzi RJ. Ascending lumbar myelography in lumbar disc disease. *J Bone Joint Surg [Am]* **1977**;59:159-163
 15. Drasin GF, Daffner RH, Sexton RF, Cheatham WC. Epidural venography: diagnosis of herniated lumbar intervertebral disc and other disease of the epidural space. *AJR* **1976**;126:1010-1016
 16. Gershater R, St. Louis EL. Lumbar epidural venography. Review of 1200 cases. *Radiology* **1979**;131:409-421
 17. Giustra PE, Wickenden JW, Furman RS, Wickenden RW, Kiloran PJ. Multiple contrast injections in epidural venography. *AJR* **1978**;131:485-488
 18. Lotz PR, Seeger JF, Gabrielsen TO. Prospective comparison of epidural venography and iophendylate myelography in the diagnosis of herniated lumbar disks. *Radiology* **1980**;134:127-132