



Discover Generics

Cost-Effective CT & MRI Contrast Agents



FRESENIUS
KABI

WATCH VIDEO

AJNR

Arteriography after Carotid Endarterectomy

John Holder, Eugene F. Binet, Stevenson Flanigan and Ernest J. Ferris

AJNR Am J Neuroradiol 1981, 2 (4) 325-329

<http://www.ajnr.org/content/2/4/325>

This information is current as
of June 22, 2025.

Arteriography after Carotid Endarterectomy

John Holder¹
Eugene F. Binet²
Stevenson Flanigan³
Ernest J. Ferris¹

Of 55 patients undergoing carotid endarterectomy, 16 had abnormal postoperative angiograms by accepted literature criteria. Five of the 16 were symptomatic. The other 11 were neurologically stable or improved from their preoperative condition. None of the 16 patients underwent reoperation. Of those 11 who had abnormal postoperative angiograms but a good clinical result, four had a second postoperative angiogram some months later that demonstrated marked improvement in the appearance of the endarterectomy site. Patients undergoing carotid endarterectomy should not be subjected to routine postoperative angiography without clinical indications nor should they undergo reoperation on the basis of angiographic findings alone without consideration of their clinical status.

Cerebral angiography remains the most precise method to evaluate the pathologic changes that occur in extracranial cerebrovascular disease involving the internal carotid artery in the neck. Several authors have strongly endorsed its use in the immediate postoperative period to evaluate the patency of the endarterectomy site. In some institutions reoperation is performed if the angiographic findings appear unsatisfactory without consideration of the patient's neurologic status. This report will examine the preoperative and postoperative angiograms of patients who were not subjected to reoperation despite having abnormal appearing postoperative carotid angiograms.

Materials and Methods

Postoperative arteriography has been routinely performed on all patients subjected to carotid endarterectomy by the Neurosurgery Service at the Little Rock Veterans Administration Medical Center. The angiographic studies of 55 such patients operated on during a 6 year period were evaluated. These male patients were 42–81 years old (average, 60½ years). Seventy percent of the patients were seen with transient ischemic episodes and 30% were evaluated for completed stroke. In addition to their extracranial cerebrovascular disease, two patients had diabetes mellitus, two had hyperlipidemia, and 12 showed intracranial cerebrovascular disease at angiography.

The preoperative angiographic evaluation in these cases consisted of selective catheterization of both common carotid arteries with anteroposterior and lateral angiography of both the head and neck vessels performed in all patients. In certain cases selective vertebral angiograms were also obtained. Oblique projections of the carotid bifurcation were also included when necessary. Aortic arch examination preceded the selective studies in 75% of the cases. The postoperative angiographic evaluation consisted of selective catheterization of the "operated artery" with anteroposterior and lateral angiograms of the head and neck plus selective study of the opposite carotid artery if significant disease was noted involving that vessel on the preoperative study.

All patients were operated under general anesthesia, most with electroencephalographic monitoring. Intraarterial shunts were not used unless electroencephalographic changes occurred or disease on the contralateral side was present.

The hospital charts on 48 (87%) of the 55 patients were available for review. These 48

Received August 28, 1980; accepted after revision March 4, 1981

Presented at the annual meeting of the American Roentgen Ray Society, Las Vegas, NV, April 1980.

¹ Department of Radiology, University of Arkansas for Medical Sciences, 4301 W. Markham, Little Rock, AR 72205. Address reprint requests to J. Holder.

² Department of Radiology, Veterans Administration Medical Center, Little Rock, AR 72206.

³ Department of Neurosurgery, University of Arkansas for Medical Sciences, Little Rock, AR 72205.

This article appears in July/August 1981 *AJNR* and September 1981 *AJR*.

AJNR 2:325–329, July/August 1981

0195–6108/81/0204–0325 \$00.00

© American Roentgen Ray Society

patients were followed an average of 15½ months; the longest follow-up was 5 years, 3 months and the shortest was 6 weeks. Two patients died in the immediate postoperative period.

Results

Of the 48 patients available for clinical follow-up, 77% were stated to have had a good clinical result. That is, their transient ischemic episodes ceased or their cerebrovascular disease did not progress in the postoperative period. On the other hand, 23% of the patients available for follow-up had a poor result; that is, they suffered a stroke in the postoperative period or their transient ischemic episodes continued.

Of the 55 immediate postoperative angiograms obtained in this series, 9% were given an *excellent* rating. An excellent postoperative angiogram was interpreted as entirely normal or showing very minimal postoperative changes. Another 57.5% of the angiograms were given a *good* rating. They showed only irregularity of the vessel wall, occlusion of the external carotid artery, or a stenosis of the internal carotid artery that did not exceed 30%. The other 33.5% of angiograms were given a *poor* appearance rating as they showed stenosis of the internal carotid artery greater than 30%. Almost two-thirds of the patients had their follow-up angiogram within 30 days of their surgical procedure, most of them while still in the hospital. In an attempt to compare the results of the surgical procedure and the radiographic appearance of the carotid artery on the postoperative angiogram, the patient population was divided into four groups.

Group 1. This group comprised the 26 patients having a good clinical result and a good or excellent appearance of the carotid artery on their postoperative angiogram. The average clinical follow-up for this group was 12.7 months with the longest patient being followed 3½ years and the shortest, 2 months.

Group 2. These six patients had a poor clinical result but a good or excellent appearance on their postoperative angiogram. Their average follow-up time was 3½ months. Included in this group were several patients whose transient ischemic episodes either persisted into or returned in the early postoperative period despite a satisfactory appearing internal carotid artery on postoperative arteriography.

Group 3. These five patients had a poor clinical result and a poor radiographic appearance on their postoperative angiograms. They had an average clinical follow-up of 21 months with the longest being 5 years, 3 months and the shortest being 1 day. In this group were several patients who complained of persistent transient ischemic attacks or vertebrobasilar insufficiency. One patient died of a massive cerebral infarct. Several postoperative angiograms in this group showed internal carotid artery occlusion or intraluminal clots or webs.

Group 4. These 11 patients were said to have a good clinical result, but a poor radiographic appearance on their follow-up angiogram. They were followed for an average of slightly over 11 months, with the longest follow-up being 4 years and the shortest, 15 days. Included in this group were two patients with asymptomatic occlusion of the internal

carotid artery on postoperative arteriography, three with significant stenosis in the distal limb of their endarterectomy, and three with stenosis of the proximal limb. Also included were three patients with large persistent filling defects or webs on the postoperative angiographic study. Four of the 11 patients in this group had a second follow-up angiogram at 19, 19.5, 20, and 33 months, respectively. Their case presentations follow.

Case Reports

Case 1

A 55-year-old man had acute onset of right-sided weakness and expressive aphasia. His preoperative angiogram demonstrated 95% stenosis of the left internal carotid artery (fig. 1A). A follow-up angiogram 9 days after a successful endarterectomy showed a thick cuff of tissue at the proximal margin of the endarterectomy site with 50% stenosis of the common carotid artery and 99% stenosis of the external carotid artery (fig. 1B). The patient was clinically stable and was not returned to the operating room. Follow-up angiogram 19 months later showed very minimal postoperative changes. The cuff had disappeared and the external carotid artery had returned to normal (figs. 1C and 1D). The patient remained well.

Case 2

A 60-year-old man was seen after several attacks of aphasia. A 95% stenosis of the carotid artery was seen on preoperative angiogram (fig. 2A). Repeat angiogram 5 days after surgery showed a large intimal flap within the lumen of the common carotid artery (fig. 2B). The patient was asymptomatic so surgery was deferred. Follow-up angiogram at 95 days again identified the intimal flap (figs. 2C and 2D). The patient remained asymptomatic. A subsequent angiogram at 19.5 months after endarterectomy revealed the flap to still be present but less prominent (figs. 2E and 2F). The patient's clinical status remained stable during this period.

Case 3

A 59-year-old known hypertensive white man had sudden onset of left hemiparesis and left facial numbness. His preoperative carotid angiogram demonstrated a 40% stenosis of the internal carotid artery with ulceration (fig. 3A). A follow-up study 6 days after surgery showed a thick cuff of tissue at the proximal margin of the endarterectomy causing a 50% stenosis of the common carotid artery (fig. 3B). The patient was asymptomatic so no surgery was performed. A second angiogram at 20 months after surgery showed only very minimal postoperative changes (figs. 3C and 3D). The patient has been well since surgery.

Case 4

A 60-year-old man had transient diplopia. His preoperative angiogram showed an ulcerated plaque and a 50% stenosis of the internal carotid artery (fig. 4A). Repeat angiogram 26 days after surgery showed 40% stenosis of the carotid artery (fig. 4B). Reoperation was not performed. A second follow-up angiogram at 33 months showed minimal postoperative changes (figs. 4C and 4D).

Fig. 1.—Case 1, 55-year-old man with acute onset of right hemiparesis and expressive aphasia. **A**, Preoperative carotid angiogram shows 95% stenosis of internal carotid artery. **B**, Postoperative angiogram 9 days later. Thick cuff of tissue at proximal margin of endarterectomy site with 50% stenosis of common carotid artery and 99% stenosis of external carotid artery. **C** and **D**, Follow-up angiogram 19 months later. Very minimal postoperative changes. Cuff has disappeared and external carotid artery has returned to normal.

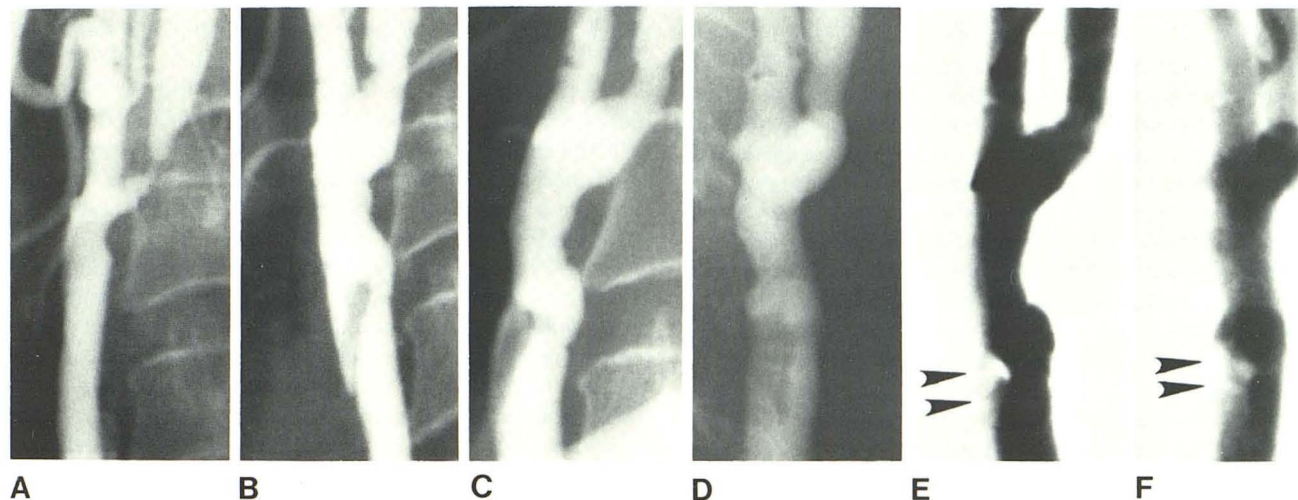
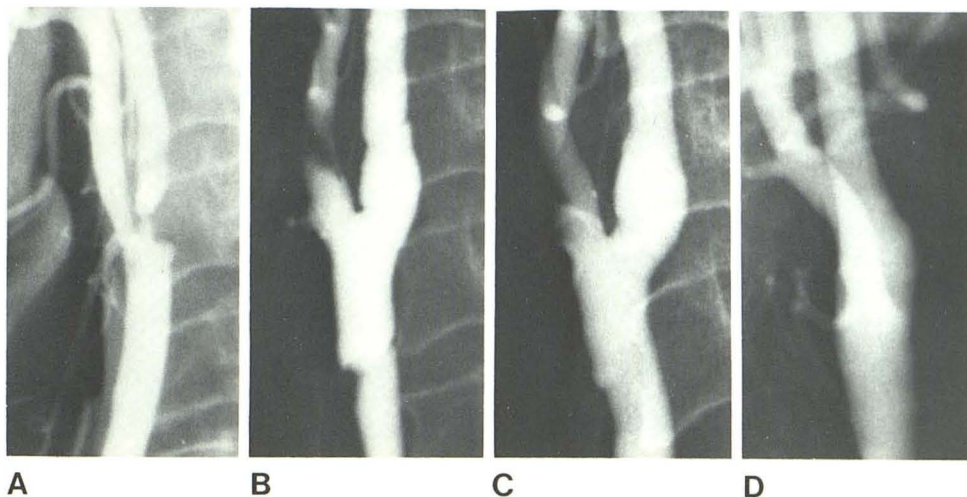


Fig. 2.—Case 2, 60-year-old man with multiple attacks of aphasia. **A**, Preoperative carotid angiogram shows 95% stenosis of carotid artery. **B**, Repeat angiogram 5 days after surgery. Large intimal flap. **C** and **D**, Repeat

angiogram at 95 days. Flap is unchanged. **E** and **F**, Final angiogram at 19.5 months. Flap is still present but less prominent (arrowheads).

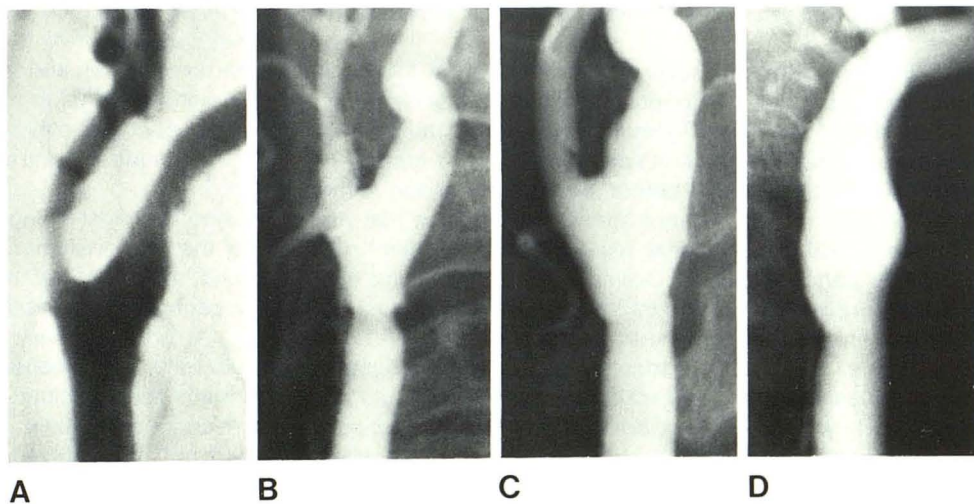


Fig. 3.—Case 3, 55-year-old man with acute onset of left hemiparesis and facial numbness. **A**, Preoperative carotid angiogram shows 40% stenosis of internal carotid artery with ulceration. **B**, Follow-up study 6 days after surgery. Thick cuff of tissue at proximal margin of endarterectomy causes 50% stenosis of common carotid artery. **C** and **D**, Repeat angiogram 20 months after surgery. Only very minimal postoperative changes.

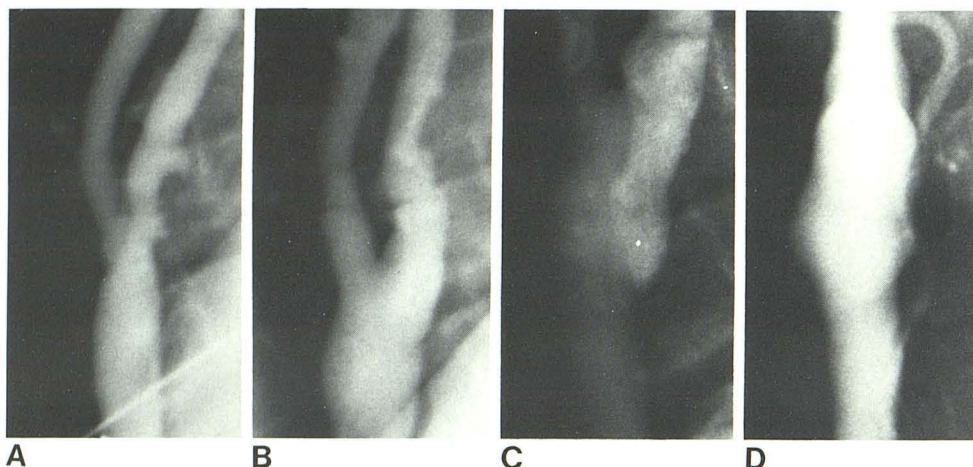


Fig. 4.—Case 4, 60-year-old man with transient diplopia. **A**, Preoperative carotid angiogram shows ulcerative plaque and 50% stenosis of internal carotid artery. **B**, Repeat study 26 days after surgery shows 40% stenosis of carotid artery. **C** and **D**, Follow-up study at 33 months after operation. Only minimal postoperative changes.

Discussion

Angiography after carotid endarterectomy may be performed either within the operative suite while the patient is still under anesthesia (intraoperative angiography) or in the radiology department at varying times after surgery (postoperative angiography). There are advantages and disadvantages to both techniques. Intraoperative angiograms are usually of poor technical quality for several reasons, including insufficient contrast material concentration within the blood vessel. Sterile field constraints often preclude proper positioning of the patient. The physical limitations of the x-ray equipment do not allow for high milliamperage, short exposure, or rapid, serial radiographs. The resultant product is frequently overexposed, mistimed, and poorly positioned. Routine intraoperative angiography has enjoyed its greatest success at those medical centers where the operating room is equipped with x-ray apparatus capable of producing radiographs of high diagnostic quality.

On the other hand, angiography in the immediate postoperative period is accomplished under more ideal circumstances. It is usually done in a specially equipped angiography suite within the radiology department by trained angiographers using catheter techniques. High quality, properly positioned, rapid sequence serial films are obtainable.

In the experience of several investigators the technical difficulties associated with intraoperative studies are more than offset by the desire to immediately assess their operative result. Blaisdell et al. [1] performed routine intraoperative carotid angiography before closing the incision in the belief that a normal operative study assures them that the immediate and late technical results will be excellent. On the other hand, Anderson, Collins and Rich [2] found that routine intraoperative angiography did not change their incidence of postoperative neurologic complications. Their experience with 131 consecutive operative angiograms failed to support the contention that its use should be routine. They indicated that operative angiography should be performed in only certain circumstances such as when the operator had difficulty passing a shunt tube or when it could not be ascertained that the distal intima had been

properly tacked down. They also felt that an angiogram should be obtained to evaluate the hemodynamic significance of externally apparent narrowings or to evaluate the final result of a technically difficult operation.

Shultz et al. [3] indicated that angiography in the immediate postoperative period should be performed if a transient or progressive neurologic deficit occurred. His group also performed postoperative studies to determine the "smoothness" of a vessel wall before operating on the contralateral carotid artery.

There is a diversity of opinion as to what constitutes an acceptable angiogram after carotid endarterectomy. Authors differ as to what angiographic findings would require them to reoperate on a carotid artery. Plecha and Pories [4] revised their vascular reconstructions when a significant defect was noted on angiography. They did not comment on the meaning of the word "significant." Gurdjian et al. [5] reoperated if the follow-up angiogram showed an obvious stenosis but did not elaborate further on "obvious."

The presence of a suture line stricture, platelet thrombi, atherosclerotic debris, or an intimal flap on angiography were all cited by Dardik et al. [6] as reasons for reoperation. Of the seven reoperated patients in the series of 131 consecutive cases reported by Anderson et al. [2], one intraoperative angiogram showed a significant stenosis, two showed exceptionally thick cuffs at the proximal ends of the endarterectomies, and three showed occlusion of the external carotid arteries. In a series of 100 patients reported by Blaisdell et al. [1], only patients demonstrating a stenosis of 30% or greater on intraoperative angiography were reoperated.

Using the most stringent criterion reported in the literature, that is, a restenosis of 30% or more of an operated carotid artery, 16 of the patients in our series had an unacceptable post endarterectomy angiogram. Of that number, 11 (group 4) were asymptomatic. These 11 patients would have been reoperated on immediately had their angiograms been obtained while they were still in the operating room under anesthesia. Their stable neurologic examination would not have played a role in determining the need for reexploration of their endarterectomy sites.

Of the five patients (group 3) who had both an abnormal

postoperative angiogram and a poor clinical result, two had total occlusion of the operated carotid artery at postoperative angiography. Immediate reoperation of an occluded carotid artery has met with mixed results. In the other three patients in group 3, intraoperative angiography may have been of value in delineating a remedial lesion but was not done for technical reasons.

In four of the 11 patients in group 4, a second angiogram was obtained at 19, 19.5, 20, and 33 months postendarterectomy, respectively (figs. 1-4). In three of the four patients with this second postoperative angiogram, the significant abnormalities identified on the immediate postoperative study had resolved. In case 4, while the intimal flap remained visible, it had become less prominent. By literature criteria, all four of these patients should have been returned to the operating room for reoperation in the immediate postoperative period. Instead, because of the lack of clinical symptoms they were not reoperated and their repeat follow-up angiograms demonstrated that the changes on arteriography seen in the immediate postoperative period were temporary. Speculation as to why the appearance of these vessels would so drastically change in periods of less than 3 years is conjecture but may be related to vessel wall edema and tissue fragmentation caused by the trauma of the surgical procedure [7]. Perhaps reendothelialization is principally responsible for the improved appearance of the vessel wall on the follow-up study.

While the group of patients studied here is of only modest size, their clinical and radiographic findings strongly suggest that patients who are neurologically stable or improved

should not be subjected to reoperation on the basis of abnormal postendarterectomy angiograms alone. The patient's clinical status should also be considered when making that decision.

Intraoperative angiography will continue to be performed in those instances when the operator is concerned about the integrity of the surgical procedure. Postoperative studies should be performed when the patient's clinical condition demands it. Routine postoperative studies after carotid endarterectomy should not be done on asymptomatic or neurologically improving patients.

REFERENCES

1. Blaisdell FW, Lim R, Hall AD. Technical result of carotid endarterectomy. *Am J Surg* **1967**;114:239-246
2. Andersen CA, Collins GJ, Rich NM. Routine operative arteriography during carotid endarterectomy: a reassessment. *Surgery* **1978**;83:67-73
3. Schutz H, Fleming JFR, Awerbuck B. Arteriographic assessment of carotid endarterectomy. *Ann Surg* **1970**;171:509-521
mediate assessment of arterial reconstruction. *Arch Surg* **1972**;105:902-907
5. Gurdjian ES, Hardy WG, Lindner DW, Thomas LM. Results of endarterectomy in the treatment of cerebrovascular disease. *Angiology* **1964**;15:88-102
6. Dardik II, Ibrahim IM, Sprayregen S, Veith F, Dardik H. Routine intraoperative angiography. *Arch Surg* **1975**;110:184-190
7. Dirrenberger RA, Sundt TM Jr. Carotid endarterectomy. *J Neurosurg* **1978**;48:201-219