



**Traumatic aneurysms of cavernous internal carotid artery with secondary epistaxis.**

E F Chambers, A E Rosenbaum, D Norman and T H Newton

*AJNR Am J Neuroradiol* 1981, 2 (5) 405-409

<http://www.ajnr.org/content/2/5/405>

This information is current as  
of July 2, 2025.

# Traumatic Aneurysms of Cavernous Internal Carotid Artery with Secondary Epistaxis

Evan F. Chambers<sup>1</sup>  
 Arthur E. Rosenbaum<sup>2</sup>  
 David Norman<sup>1</sup>  
 Thomas H. Newton<sup>1</sup>

The syndrome of delayed epistaxis and monocular blindness following nonpenetrating head injury is reviewed. Bleeding results from rupture of a traumatic cavernous internal carotid artery aneurysm into the sphenoid sinus. There were 96 patients with this syndrome found in the literature and another four are added in this report. In 73% of the patients, the cause of the epistaxis was not appreciated until 4 months after the initial episode. No antemortem diagnosis was made in 15% of the patients. More frequent use of carotid angiography in patients with posttraumatic monocular blindness and delayed epistaxis might help reduce the reported mortality of 30%.

Injury to the internal carotid artery after nonpenetrating head trauma may result in: (1) dissection of the internal carotid artery with secondary occlusion; (2) carotid-cavernous sinus fistula; (3) rupture of the internal carotid artery; or (4) false aneurysm of the internal carotid artery which may subsequently rupture into the sphenoid sinus.

The triad of unilateral blindness, false aneurysm of the cavernous part of the internal carotid artery, and severe delayed epistaxis after nonpenetrating head injury was first reported by Barth [1] in 1924. Since then, sporadic reports have appeared in the world literature [2-4]. The diagnostic significance of severe head trauma, transient or permanent neurologic sequelae, and a latent period between injury and onset of epistaxis was emphasized by Brihaye and coworkers [5].

Severe epistaxis is usually caused by hypertension while trauma is an unusual etiology. In a series of 200 patients with epistaxis reviewed by Evans [6], only three had a history of trauma. Holger [7] reviewed 1,724 patients with epistaxis and found that trauma was the cause in only 47 (2.7%) patients. While injury to the internal carotid artery may not be a common cause of epistaxis, it is not an infrequent occurrence judging by the number of cases reported in the literature. The clinical and radiologic aspects of four patients with monocular blindness and delayed epistaxis following nonpenetrating head trauma and 96 previously reported patients are reviewed to familiarize the radiologist with this syndrome. Patients with penetrating head injuries are excluded from this report.

Received January 29, 1981; accepted March 16, 1981.

Presented at the annual meeting of the American Society of Neuroradiology, March 1980, Los Angeles, CA, March 1980.

<sup>1</sup>Department of Radiology, M 296, University of California, San Francisco, School of Medicine, San Francisco, CA 94143. Address reprint requests to T. H. Newton.

<sup>2</sup>Department of Radiology, Johns Hopkins Medical Center, Baltimore, MD 21205.

**AJNR 2:405-409, September/October 1981**  
 0195-6108/81/0205-0405 \$00.00  
 © American Roentgen Ray Society

## Case Reports

### Case 1

A 52-year-old man had repeated epistaxis from the left naris. He had had severe head trauma 22 years before, followed by unilateral blindness of the left eye. Following the first episode of massive epistaxis, the left external carotid artery was ligated, but severe epistaxis soon recurred. The patient then underwent a left ethmoidectomy and left lateral rhinotomy. Identification of blood arising from the left lateral sphenoid sinus prompted arteriography. Carotid arteriography revealed an aneurysm of the cavernous segment of the left internal carotid artery projecting into the lateral sphenoid sinus (fig. 1). The left internal carotid artery was ligated with control of the epistaxis.



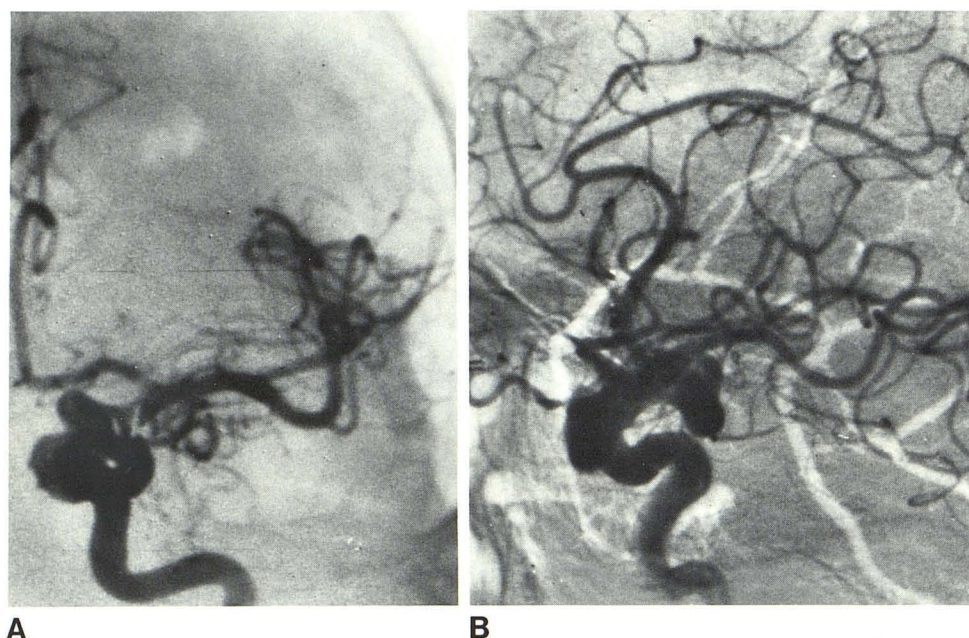


Fig. 1.—Case 1. Selective internal carotid arteriograms. Aneurysm of cavernous segment of left internal carotid artery.

#### Case 2

A 17-year-old man, involved in a motor vehicle accident, was admitted in a somnolent confused state. Over the next 24 hr he became more alert and it became apparent that he had loss of vision in the left eye. Computed tomography (CT) revealed fracture of the left orbit, but no intracerebral hematoma was visualized. He was discharged 1 week later.

About 2 weeks after the accident he noted the sudden onset of severe headache, nausea, vomiting, and lethargy. At physical examination, he was confused and somnolent. A CT scan showed a bifrontal intracerebral hemorrhage. He was treated with supportive measures and within 24 hr he became alert and, except for a blind left eye, showed no focal neurologic findings.

The patient had a profuse episode of epistaxis 2 weeks later which required blood transfusions. Carotid arteriography revealed an aneurysm of the cavernous part of the left internal carotid artery projecting into the sphenoid sinus (fig. 2). The left internal carotid artery was clamped.

#### Case 3

A 59-year-old man had repeated epistaxis from the left naris. He had had severe head trauma 40 years before which resulted in loss of vision in the left eye and basilar skull fracture. On the basis of history and physical examination, a traumatic aneurysm of the left internal carotid artery was suspected. Carotid arteriography demonstrated a lobulated aneurysm of the cavernous part of the left internal carotid artery which protruded into the anterior sphenoid sinus (fig. 3). Double ligation of the internal carotid artery was performed.

#### Case 4

A 65-year-old man had several episodes of epistaxis after a motor vehicle accident 4 years before. The initial episode of epistaxis immediately following the accident was treated with anterior

nasal packing. The patient had normal vision and no cranial nerve palsies. Fracture of the right zygoma and of the left cribriform plate were found.

He had one episode of epistaxis during the next 4 years. Six weeks prior to the present admission the patient suffered severe epistaxis from the left naris. The anterior ethmoidal arteries were ligated without cessation of the epistaxis. Left carotid arteriography demonstrated a false aneurysm of the cavernous segment of the left internal carotid artery with extension into the sphenoid sinus (fig. 4).

A Silverstone clamp was placed on the left internal carotid artery. The patient tolerated the procedure and there was no recurrence of the epistaxis.

#### Discussion

We reviewed 100 patients with blunt head trauma who developed epistaxis secondary to rupture of a traumatic aneurysm of the internal carotid artery into the sphenoid sinus. Of these, 96 are from the literature and four are from our series [1-3, 8-71].

Sixty-six patients were in a motor vehicle accident, 15 were injured in falls, six had miscellaneous injuries, and in 13 the type of trauma was not specified. There were 85 males and 14 females (one was not specified); they were 3-70 years old (average, 28 years).

The latent period between injury and onset of epistaxis was a few days to many years. Of the patients, 54% had the first episode of epistaxis within the first month; 87% had epistaxis within the first 6 months after trauma. In three patients, epistaxis was first noted between 6 and 12 months; in four it occurred 4-40 years following trauma. In six patients, the latent period between trauma and epistaxis was not specified. It is of interest that three of the four patients in our series had the onset of epistaxis 4, 22, and



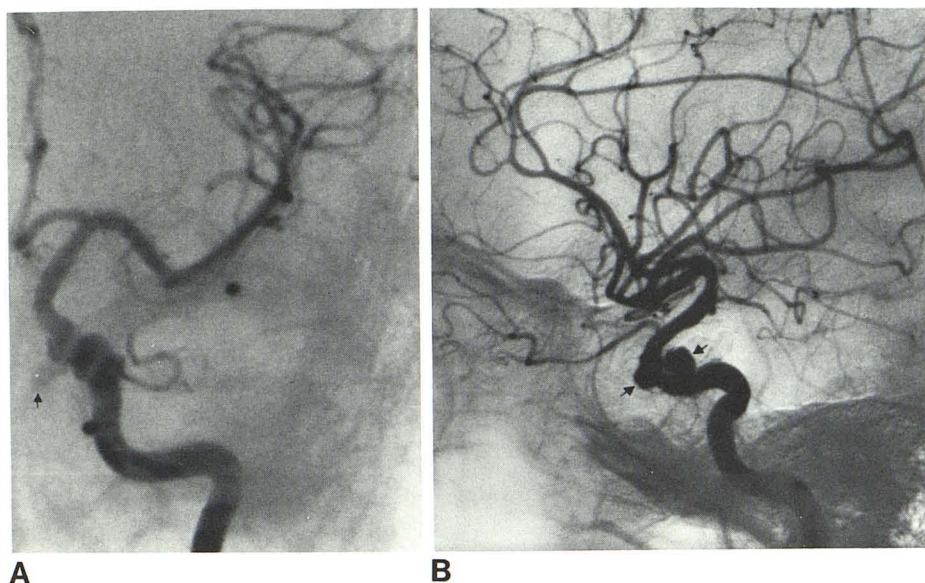


Fig. 2.—Case 2. Anteroposterior (A) and lateral (B) arteriograms. Bilobed aneurysm (arrows) of cavernous part of left internal carotid projects anteroinferiorly and medially.

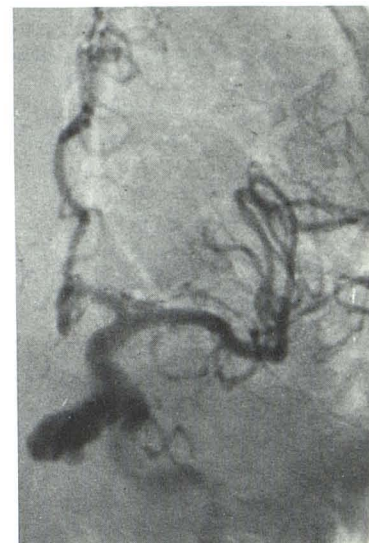

Fig. 3.—Case 3. Large aneurysm of cavernous segment of left internal carotid artery projects inferiorly and medially into sphenoid sinus.

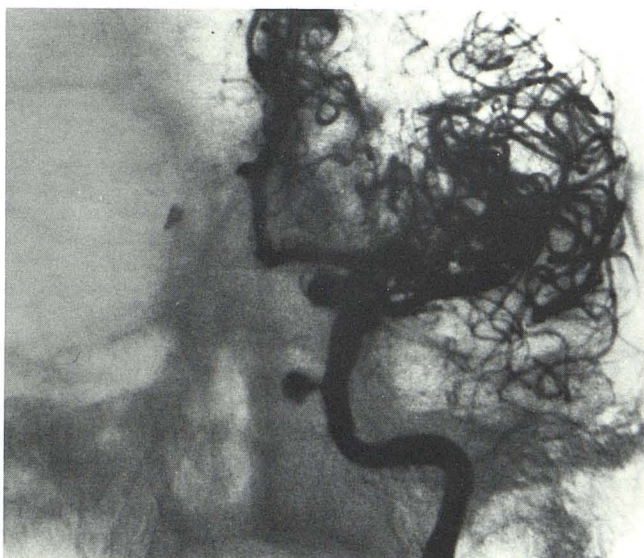

Fig. 4.—Case 4. Anteroposterior internal carotid artery angiogram. Aneurysm projects medially from cavernous part of left internal carotid artery.

40 years after initial trauma. The initial episodes of epistaxis were seldom fatal; bleeding usually recurred and became more severe with time.

Unilateral visual loss was observed in 73 patients (39, left side; 30, right; four, side not specified), bilateral blindness was noted in five patients, and 14 patients had normal ophthalmologic examinations. The visual loss was usually noted immediately after trauma. In eight patients visual

function was not specified. Blindness probably results either from direct trauma to the optic nerve or ophthalmic artery by fracture of the optic canal or from compression of the optic nerve or ophthalmic artery by the aneurysm or hematoma.

Involvement of other cranial nerves was variable. Third cranial nerve palsy was noted in 33 patients, sixth nerve involvement in 17, fifth nerve damage in 16, and the first cranial nerve was affected in 14. Involvement of the fourth, eighth, and ninth cranial nerves was less frequently noted. Bilateral cranial nerve involvement was infrequent.

Basilar skull fractures involving the orbit, sphenoid sinus, or sella turcica were found in 77 of the 88 patients examined radiologically. Carotid arteriography, performed in 69 patients, revealed an aneurysm of the cavernous internal carotid artery projecting anteriorly, inferiorly, and medially into the sphenoid sinus in 65 patients. The left side was involved in 36, the right in 29. In four patients, no aneurysm was shown. However, in six of the patients reported to have aneurysms, initial arteriography did not reveal the aneurysm, which was only shown on subsequent studies [23, 27, 37, 53, 56, 69].

The mortality in this group of patients was 30%. This high mortality is in part due to inadequate diagnosis and improper treatment. In 73% of patients, the cause of the bleed was not appreciated until 4 months after the initial epistaxis. Shirai et al. [69] reviewed the results of different surgical procedures for the treatment of this condition. They concluded that ligation of the internal carotid artery provided the best results. In 1972, Konovalov et al. [57] reported several patients in whom balloon occlusion of the cavernous part of the internal carotid artery was used.



## ACKNOWLEDGMENTS

We thank Ronald E. Shallitt, Berkeley, Cal., for case 2; G. A. Magid, Santa Cruz, Cal., for case 3; and Art Dublin, University of California, Davis, Cal., for case 4.

## REFERENCES

- Barth G. Tödliche Spätblutung aus der Carotis interna nach Schädeltrauma. *Dtsch Med Wochenschr* 1924;50:875-876
- Maurer JJ, Mills M, German WJ. Triad of unilateral blindness, fractures and massive epistaxis after head injury. *J Neurosurg* 1961;18:837-840
- Bonnal J, Stevenaert A, Beaujean M, Thibaut A. Épistaxis répétées graves, parfois mortelles, secondaires à des lésions de la carotide interne. *Neurochirurgie* 1967;13:417-430
- Mahmoud NA. Traumatic aneurysm of the internal carotid artery and epistaxis (review of literature and report of a case). *J Laryngol Otol* 1979;93:629-656
- Brihayé J, Mage J, Verriest G. Anévrisme traumatique de la carotide interne dans sa portion supraclinoidienne. *Acta Neurol Belg* 1954;54:411-438
- Evan J. The etiology and treatment of epistaxis: based on a review of 200 cases. *J Laryngol Otol* 1962;76:185-191
- Holger J. Epistaxis—a clinical study of 1,724 patients. *J Laryngol Otol* 1974;88:317-327
- Cairns H. The vascular aspects of head injuries. *Lisboa Med* 1942;19:375-410
- Birley JL. Traumatic aneurysm of the intracranial portion of the internal carotid artery. *Brain* 1928;51:184-208
- Davis EDD. Severe epistaxis, difficult to control. *Br Med J* 1939;1:721-723
- Jacques PM. Épistaxis graves et répétées d'origine caverneuse complication tardive de traumatismes cranio-faciaux. *Rev Laryngol Otol Rhinol (Bord)* 1940;61:233-238
- Rousseau F, Spillman J. Deux cas d'épistaxis incoercibles avec cécité homolatérale par lésion de la carotide interne intracranienne après chute sur la tête. *Ann Otol Rhinol Laryngol* 1951;68:461-465
- Fabian G. Traumatisches Aneurysma der Carotis interna in der Keilbeinhöhle. *HNO* 1952;3:346-348
- Hamilton JG. Massive epistaxis following closed head injury. *Guys Hosp Rep* 1953;102:360-367
- Bonnet P, Bonnet I. Le syndrome du trou déchiré antérieur, symptomatique de l'anévrisme intra-caverneux de la carotide interne. *Archiv Ophthalmol (Paris)* 1953;13:121-126
- Schlosshauer B, Vosteen KH. Zur Diagnostik und Therapie der Carotisblutung nach Keilbeinhöhlenfrakturen. *Arch Otorhinolaryngol* 1957;165:270-277
- Denecke HJ, Hartert H. Carotis interna-Verletzung mit unstillbarem Nasenbluten, geheilt durch intraarterielle Thrombininjektion. *Chirurg* 1954;25:470-472
- Takeda R, Kawakita T. Basilar fracture with secondary epistaxis. *Otorhinolaryngology (Tokyo)* 1954;20:173-174
- Bonnet MP. Epistaxis mortelle, par rupture traumatique de la carotide interne dans le sinus sphénoïdal. *Rev Otoneuroophthalmol* 1955;27:24-26
- Christensen JC. Epistaxis por aneurismas carotídeos infracilinoideos. *Acta Neurol Lat Am* 1955;1:60-70
- MacKenzie I. The intracranial bruit. *Brain* 1955;78:350-370
- Fabian G. Traumatisches Aneurysma der Carotis interna in der Keilbeinhöhle. *HNO* 1956;6:42-45
- Bengochea FG, Revuelta R, Carrera JCF. Aneurisma sacular traumático de la carótida interna en el seno aéreo esfenoidal tratado con ligadura de ambas carótidas externas y de la carótida interna homolateral. *Acta Neurol Lat Am* 1957;3:395-399
- Stenger HH. Dauertamponade bei schwerem arteriellem Nasenbluten nach Trauma. *HNO* 1957;6:276-279
- Seftel DM, Kolson H, Gordon BS. Ruptured intracranial carotid artery aneurysm with fatal epistaxis. *Arch Otolaryngol* 1959;70:52-60
- Packer P. Severe epistaxis due to a leaking extracranial aneurysm of the internal carotid artery. *S Afr Med J* 1960;34:641-642
- Yarborough WL, Harrill JA, Alexander E. Traumatic internal carotid aneurysm rupture into sphenoid sinus with angiographic demonstration. *Laryngoscope* 1960;45:1313-1325
- Voris HC, Basile JXR. Recurrent epistaxis from aneurysm of the internal carotid artery. *Neurosurgery* 1961;18:841-842
- Weaver DF, Gates EM, Nielsen AE. Traumatic intracranial vascular lesions producing late massive nasal hemorrhage. *Trans Am Ophthalmol Soc* 1961;65:759-774
- Malicka K. A contribution to the late post-traumatic nasal haemorrhages. *Otolaryngol Pol* 1963;17:215-219
- McCormick WF, Beals JD. Severe epistaxis caused by ruptured aneurysm of the internal carotid artery. *J Neurosurg* 1964;21:678-686
- Araki C, Handa H, Handa J, Yoshida K. Traumatic aneurysm of the intracranial extradural portion of the internal carotid artery. *J Neurosurg* 1964;23:64-67
- Weinman DF, Subramaniam N. Traumatic aneurysm of the internal carotid artery—a cause of torrential epistaxis. *Ceylon Med J* 1964;9:80-82
- Zakrzewski A, Durska-Zakrzewska A, Gradzki J, Gradzki J, Gerwel T. Post-traumatic aneurysm of the internal carotid artery in its intracranial course with recurrence of nasal hemorrhages. *Otolaryngol Pol* 1964;18:47-51
- Hitchcock E. Profuse epistaxis and sphenoidal sinus fractures. *Br J Surg* 1965;52:197-198
- Gouazé A, Ardouin P, Larmande A, Salles M, Santini JJ. Anévrysmes traumatiques du siphon carotidien révélés par des épistaxis massives, secondaires. *Rev Otoneuroophthalmol* 1966;38:202-207
- Decroix G, Piquet JJ, Massol P. Épistaxis grave par fissuration d'un anévrysme post-traumatique de la carotide interne. *Ann Otolaryngol Chir Cervicofac* 1966;83:581-583
- Gotfrýd O, Morávek V, Schröder R, Bzonek J. Injury of the arteria carotis interna with massive epistaxis. *Rozhl Chir* 1966;45:770-773
- Jamart P, Stevenaert A, Thibaut A, Beaujean M, Bonnal J. Epistaxis cataclysmique par rupture d'un anévrysme de la carotide interne dans le sinus sphénoïdal. *Acta Otorhinolaryngol Belg* 1967;21:21-30
- Handa J, Kikuchi H, Iwayama K, Teraura T, Handa H. Traumatic aneurysm of the internal carotid artery. *Acta Neurochir (Wien)* 1967;17:161-177
- Schürmann K, Brock M, Becker W. Verletzung der Arteria carotis interna an der Schadelbasis bei frontobasalen Schädelhirntraumen. *Laryngol Rhinol Otol (Stuttg)* 1967;46:41-48
- Loiseau G, Marchand J, Moncade J, Tomasini. Épistaxis grave par rupture d'anévrysme de la carotide interne dans son segment infraclinoidien. *Ann Otolaryngol Chir Cervicofac (Paris)* 1967;84:472-475
- Matecki J. Contribution to caustics of nasal hemorrhages due to the aneurysm of the internal carotid artery. *Otolaryngol Pol* 1967;21:475-478
- Zakrzewski A, Tokarz F, Kozaryn P. Diagnostic and therapeutic difficulties of the management of violent nasal hemorrhages, following injury to the internal carotid artery. *Otolaryngol Pol*



- 1967;21:479-482
45. Salmon JH, Blatt ES. Aneurysm of the internal carotid artery due to closed trauma. *J Thorac Cardiovasc Surg* 1968;56:28-32
  46. Zakrzewski A, Konopacki K, Kwaskowski A, Gradzki J. Rupture of the internal carotid artery during fracture of the cranial base. *Otolaryngol Pol* 1969;23:685-692
  47. Papo I, Carusseli G, Salvolini U. Epistaxis post-traumatique massive par rupture d'anévrysme infraclinoidien. *Neurochirurgie* (Paris) 1969;15:283-290
  48. Zebkowski J, Hassman W, Lewko J. Poorly controllable epistaxis as a result of complicated fracture of the cranial base. *Otolaryngol Pol* 1969;23:679-683
  49. Arseni C, Ionesco S. Hémorrhage nasale grave provoquée par la rupture d'un anévrysme carotidien intracranien posttraumatique. *Rev Otoneuroophthalmol* 1969;41:149-154
  50. Baron F, Legent F, Desarns P, Collet M. In: *Comptes rendu des Congrès Français D'Oto-Rhino-Larynologie*. Paris: Arnette, 1950
  51. Descuns P, Collet M, Jubier P, Resche F. Epistaxis cataclysmiques posttraumatiques. Conduite à tenir. *Rev Otoneuroophthalmol* 1971;43:161-166
  52. Kellerhals B, Lévy A. Rezidivierende Epistaxis bei traumatischem Aneurysma der A. carotis interna. *HNO* 1971;19:53-56
  53. Pathak PN. Epistaxis—due to ruptured aneurysm of the internal carotid artery. *J Laryngol Otol* 1972;86:395-397
  54. Scharfetter F. Profuses Nasenbluten nach Schädeltraumen durch Carotis interna-Verletzungen. *Hefte Unfallheilkd* 1972;75:241-247
  55. Kurozumi S. Severe recurrent epistaxis caused by traumatic aneurysm of the internal carotid artery. *Otolaryngol* (Tokyo) 1971;43:685-690
  56. Keane JR, Talla A. Posttraumatic intracavernous aneurysm. Epistaxis with monocular blindness preceded by chromatopsia. *Arch Ophthalmol* 1972;87:701-705
  57. Konovalov AN, Serbinenko FA, Unirikhin AK. Traumatic aneurysms of the internal carotid artery and nasal bleedings. *Zh Vopr Neurokhir* 1972;36:16-27
  58. Takahashi S, Ebina T. Massive epistaxis from the traumatic aneurysm of the internal carotid artery within the cavernous portion—report of a case with review of literature. *Brain Nerve* 1973;25:1751-1754
  59. Burton R. Massive epistaxis from a ruptured traumatic internal carotid artery aneurysm. *Med J Aust* 1973;1:692-694
  60. Popiel L, Kopczynski. The aneurysm of the internal carotid artery as a cause of nasal hemorrhages. *Otolaryngol Pol* 1973;27:519-521
  61. Ulasowicz AF. Aneurysms of the internal carotid artery in cavernous sinus as a cause of the bleeds from the nose. *Vestn Otorinolaringol* 1974;5:94
  62. Intaraprasong S, Sombunsin R, Bunyaratavej S. Epistaxis due to ruptured aneurysm of the internal carotid artery. *J Med Assoc Thai* 1974;57:613-616
  63. Put TR. Epistaxis ten gevolge van rupturen van aneurysma's van de carotis interna of van de carotis interna zelve na trauma capitis. *Acta Chir Belg* 1974;6:587-596
  64. Blagoveshchenskma N. (Title in Russian.) In: *Zh Ushn Nos Gorl Bolezn* 1974;0:92-94
  65. Zakrzewski A. Zespół Krwotoków nosowych i ślepoty w następstwie pourazowego rozdarcia syfonu tętnicy szyjnej wewnętrznej. *Otolaryngol Pol* 1975;29:149-158
  66. Handa J, Handa H. Severe epistaxis caused by traumatic aneurysm of cavernous carotid artery. *Surg Neurol* 1976;5:241-243
  67. Ishikawa S, Kajikawa H, Hibino H, et al. Massive epistaxis from intracranial extradural aneurysm of the internal carotid artery associated with head injury. *No Shinkei Geka* 1976;4:953-961
  68. Rusu M, Sandulescu G, Dinu C, Berigoi E, Cezar D. Ruptura traumatică a arterei carotide interne cu epistaxis masiv repetat. *Rev Chir [Otorinolaringol]* 1976;21:299-302
  69. Shirai S, Tomono Y, Owada T, Maki Y. Traumatic aneurysm of the internal carotid artery. Report of a case with late severe epistaxis. *Eur Neurol* 1977;15:212-216
  70. Timoszenko PA, Sekacz SF. The bleeds from the nose after tears of the aneurysms of the internal carotid artery. *Vestn Otorinolaringol* 1978;5:110-111
  71. Flieger S, Citowicki W, Bystrzycki B, Aniol K. Lethal epistaxis due to damage to the internal carotid artery after fracture of the cranial base and facial bones. *Czas Stomatol* 1979;32:159-163