



Intraoperative delineation of lesions in the sellar region with metrizamide.

M Banna and S W Schatz

AJNR Am J Neuroradiol 1981, 2 (5) 461-464
<http://www.ajnr.org/content/2/5/461.citation>

This information is current as
of July 1, 2025.

Intraoperative Delineation of Lesions in the Sellar Region with Metrizamide

M. Banna¹ and S. W. Schatz²

Televised fluoroscopy during surgery has been an important factor in the resurgence and refinement of the transsphenoidal approach to sellar lesions. It provides continuous control of placement of instruments, and permits further radiologic evaluation of the extent of the lesion. Intraoperative pneumoencephalography has been used to delineate sellar tumors [1], but the image obtained is often unsatisfactory. We have found intralesion injection of metrizamide to be a better method for radiologic visualization of pituitary and parapituitary lesions during surgery.

Subjects and Methods

Transsphenoidal injection of metrizamide (Amipaque) was performed in 40 consecutive patients with clinical and radiologic evidence of lesions in the sellar area. Age range was 6–82 years (average, 48). There were 24 male and 16 female patients. All but seven had pituitary adenomas. Four patients had malignant lesions: a chordoma, a sphenoidal sinus carcinoma, and two patients with metastases. Three other patients had a craniopharyngioma, "empty" sella, and neurilemmoma, respectively.

After fenestration of the sellar floor, but before incision of its lining, a lumbar puncture needle (22 gauge or smaller in caliber) is

introduced into the lesion. Less than 1 ml of metrizamide, in a concentration of 190 mg I/ml, is gently injected under fluoroscopy. Radiographs in lateral and anteroposterior projections are obtained. Additional contrast material is required to outline larger tumors. Despite the occasional escape of some solution into the sphenoidal sinus or the basal cisterns, the total volume used has never exceeded 9.5 ml (3.75 g metrizamide + 7.8 ml diluent), even in massive lesions.

Results

The extent of the lesion was clearly demonstrated in all cases (figs. 1–6). In one patient, thought preoperatively to have a pituitary tumor, metrizamide outlined an "empty" sella (fig. 7).

Extravasation of some contrast medium outside the confines of the tumor occurred in about half the cases. It outlined the ventricular system in one patient with pituitary apoplexy (fig. 8). Extravasation into the subarachnoid spaces occurred only from adenomas with suprasellar extension. It was more profuse in recurrent tumors (fig. 9) or with forced injection. In one patient the contrast medium,

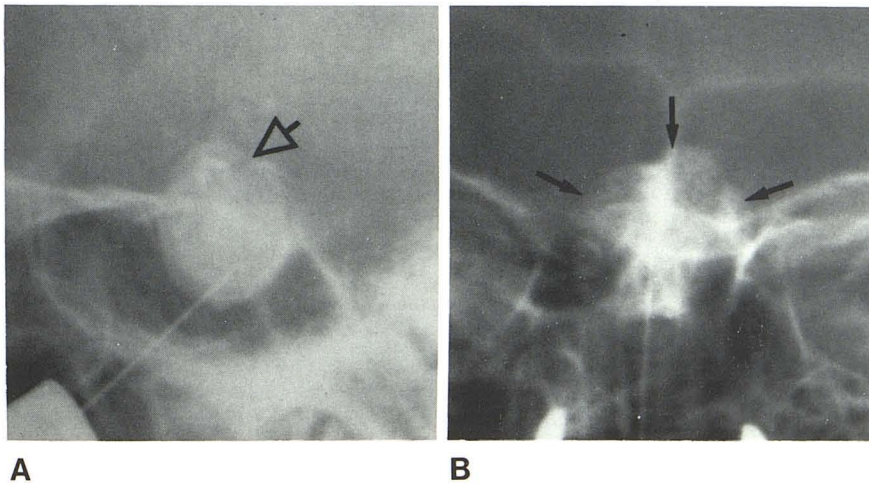


Fig. 1.—Lateral (A) and anteroposterior (B) radiographs of metrizamide injection into pituitary adenoma (arrows).

Received October 22, 1980; accepted after revision March 18, 1981.

¹Department of Radiology, McMaster University Medical Centre, Hamilton, Ontario L8N 3Z5, Canada.

²Department of Neurosciences, McMaster University Medical Centre, 1200 Main St. W., Hamilton, Ontario L8N 3Z5, Canada. Address reprint requests to S. W. Schatz.

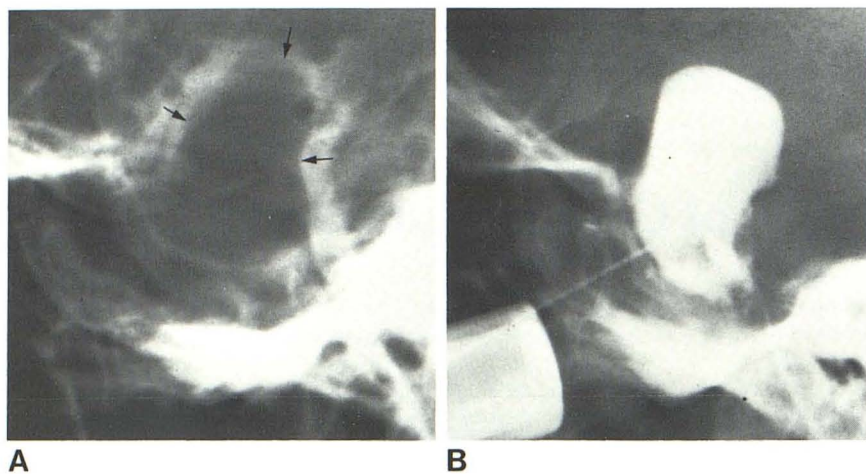


Fig. 2.—Suprasellar extension. **A**, Preoperative metrizamide cisternogram of pituitary adenoma with large suprasellar extension (arrows) [2]. **B**, Same lesion demonstrated by direct injection of metrizamide at surgery.

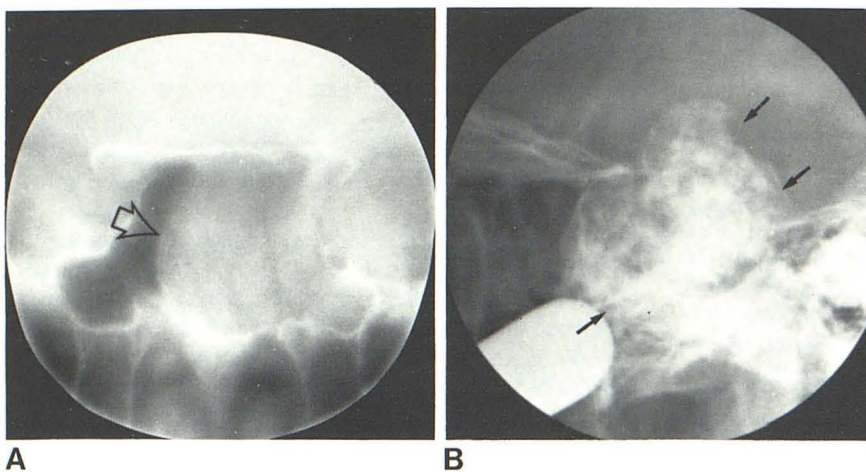


Fig. 3.—Infrasellar and suprasellar extension. **A**, Anteroposterior tomogram of pituitary adenoma with massive extension into sphenoidal sinus (arrow). **B**, Same lesion outlined by direct injection of metrizamide at surgery (arrows).

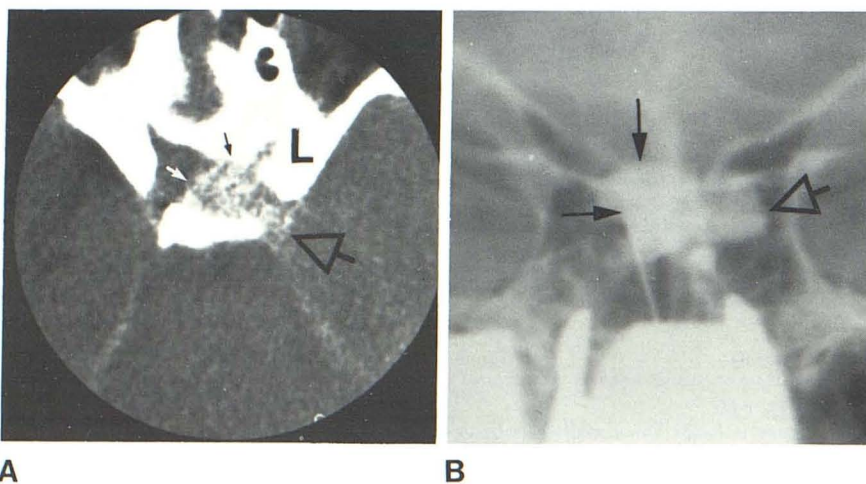


Fig. 4.—Parasellar extension. **A**, CT scan of pituitary adenoma performed during carotid injection of contrast medium (reprinted from [3]). **B**, Intraoperative demonstration of same tumor. Intrasellar (solid arrows) and parasellar (open arrows) components.

Fig. 5.—Retrosellar tumors. **A**, Axial contrast-enhanced CT scan. Large retrosellar tumor (arrow). **B**, Same lesion outlined by direct transsphenoidal injection of metrizamide. Histologically, this was neurilemmoma.

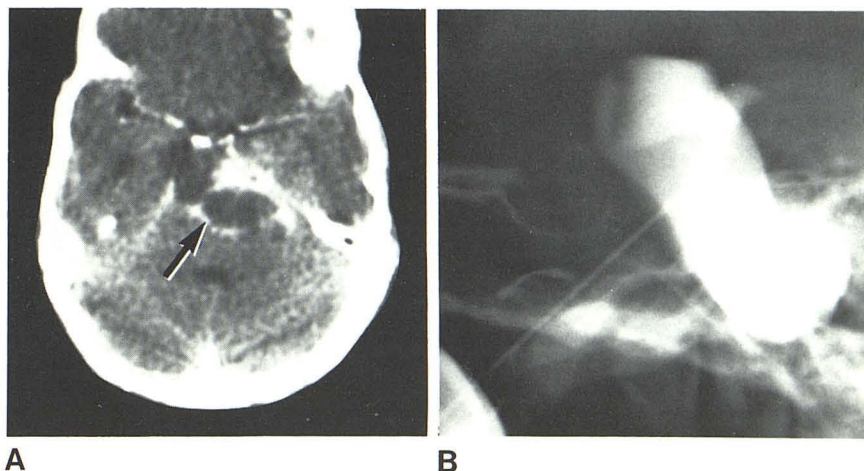


Fig. 6.—Contrast medium depicts microadenoma (arrows) which was found at surgery to be imbedded in normal gland.

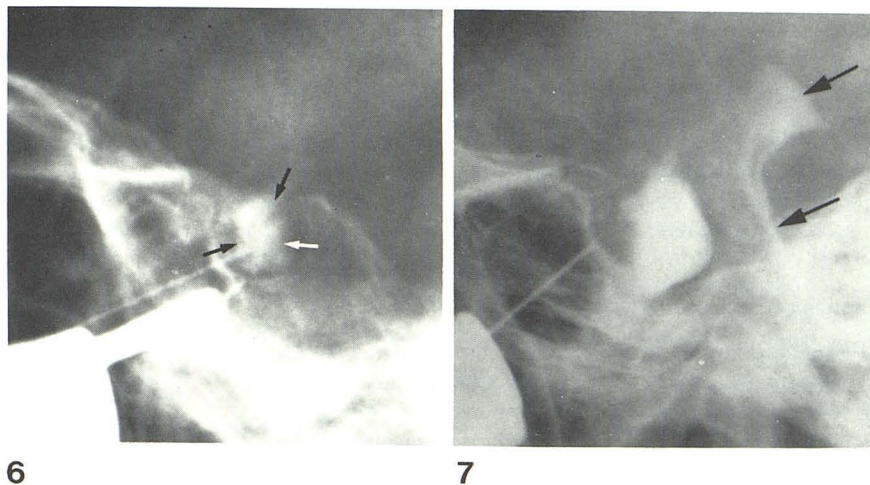


Fig. 7.—“Empty” sella. Horizontal fluid level between metrizamide and cerebrospinal fluid. Escape of contrast medium into interpeduncular and pontine cisterns (arrows).

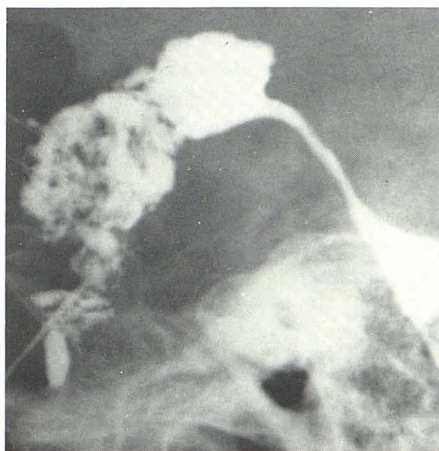


Fig. 8.—Extravasation of contrast medium into third ventricle in patient with pituitary apoplexy: 54-year-old woman who underwent transfrontal resection of pituitary adenoma 8 years earlier. She was readmitted as emergency with subarachnoid hemorrhage. Investigations, including CT scan, showed hemorrhage into recurrent adenoma, which was seen at surgery to extend into third ventricle.

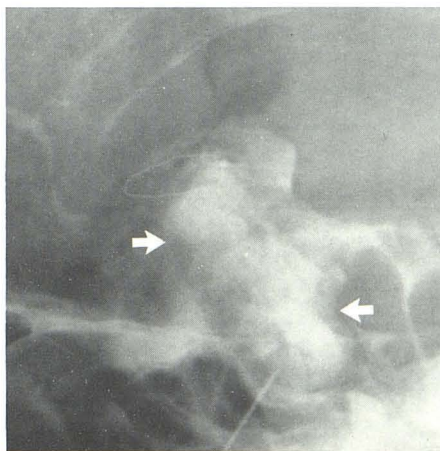


Fig. 9.—Extravasation of contrast medium into adjacent cerebrospinal fluid spaces through defect in tumor capsule from previous transfrontal surgery. Massive recurrent adenoma (arrows).

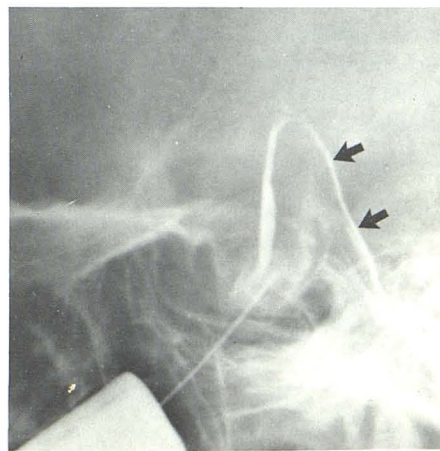

Fig. 10.—Escape of contrast medium through defect in tumor capsule. Contrast medium behind clivus (arrows), possibly in epidural space.

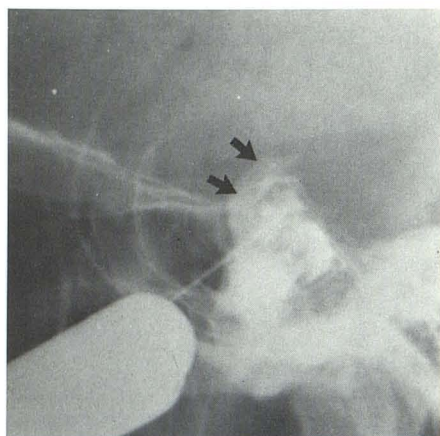
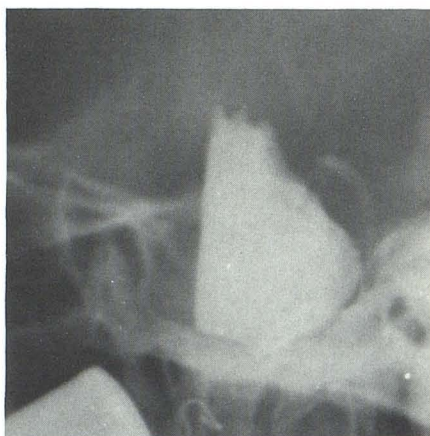
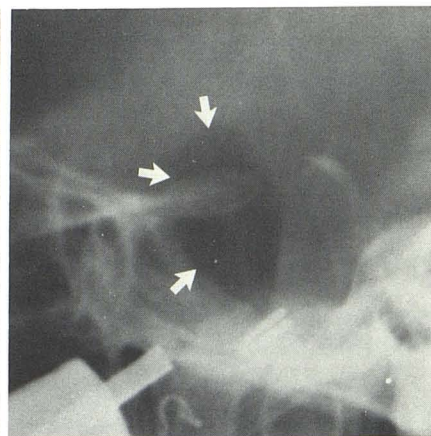


Fig. 11.—Extravasation of contrast medium into carotid sheath (arrows).



A



B

Fig. 12.—Cystic pituitary adenoma. A, Fluid level of metrizamide within tumor (patient supine). B, Air outlines anterior wall of tumor capsule (arrows).

possibly in the epidural space, outlined the clivus (fig. 10). In three patients, the carotid sheath was opacified (fig. 11). None of the patients experienced any clinical or endocrinologic abnormality that could be attributed specifically to metrizamide. This procedure did not interfere with the histopathologic diagnosis of the biopsy material.

Discussion

Pneumoencephalography on the anesthetized patient in the surgical theatre may be cumbersome, time-consuming, and occasionally unsuccessful. The clarity of the image is influenced by the volume of air within the third ventricle and the superimposition of the cortical subarachnoid spaces and is not always satisfactory. Therefore, an alternative method of tumor visualization is desirable.

Early in our study, an oily contrast medium was used with less satisfactory results. It tended to form globules and did not diffuse uniformly throughout the lesion. An ionized water-soluble iodine solution was used once. The patient developed transient, minor seizure activity in the immediate

postoperative period due to extravasation into the subarachnoid spaces. This complication did not occur with any of the patients in whom metrizamide, a nonionic solution, was used.

Our experience indicates that adenomas were more easily opacified than were the malignant tumors. This is, perhaps, related to their physical consistency. Most of the adenomas were soft and showed homogeneous or mottled opacification. In cystic lesions, a fluid level was seen (fig. 12). This could be differentiated from "empty" sella by the absence of opacification of the interpeduncular and pontine cisterns.

REFERENCES

1. Hardy J, Wigser SM. Trans-sphenoidal surgery of pituitary fossa tumours with televised radiofluoroscopic control. *J Neurosurg* 1965;23:612-619
2. Hall K, McAllister VL. Metrizamide cisternography in pituitary and juxtapituitary lesions. *Radiology* 1980;134:101-108
3. Banna M. Computed tomographic arteriography of microadenoma. *J Comput Assist Tomogr* 1980;4:690-692