

# Generic Contrast Agents

Our portfolio is growing to serve you better. Now you have a *choice*.



FRESENIUS  
KABI

[VIEW CATALOG](#)

# AJNR

## Depiction of a Postoperative Pseudomeningocele with Digital Subtraction Myelography

C. Douglas Phillips, George J. Kaptain and Nasser Razack

*AJNR Am J Neuroradiol* 2002, 23 (2) 337-338

<http://www.ajnr.org/content/23/2/337>

This information is current as  
of May 8, 2025.

## Depiction of a Postoperative Pseudomeningocele with Digital Subtraction Myelography

C. Douglas Phillips, George J. Kaptain, and Nasser Razack

**Summary:** Digital subtraction myelography is described for its utility in the detection of dural leaks associated with pseudomeningoceles. Although myelography, CT, and MR imaging have been described as effective means for diagnosing pseudomeningocele, this complicated entity can be difficult to diagnose.

Postsurgical pseudomeningoceles are relatively rare complications of spinal surgery that have received little attention in both the neurosurgical and radiologic literature (1). They result from an inadvertent meningeal tear or inadequate closure during spinal surgery (1–3). CSF extravasates from a dural-arachnoid tear and is contained within the wound. Sequelae such as wound swelling, headache, and focal neurologic may result (4). Often, radicular pain can be precipitated or aggravated by maneuvers that increase intracranial and intraspinal pressure, such as coughing, sneezing, or jugular compression (5).

We describe a case of recurrent pseudomeningocele that was not clearly defined at myelography, postmyelographic CT, or MR imaging. An experienced neurosurgical team performed an interval surgical procedure before digital subtraction angiography; the procedure did not demonstrate the leak. Diagnosis was confirmed at digital subtraction myelography, a novel study that we offer as an additional technique for use in the diagnosis of pseudomeningocele.

### Description of Technique

After MR imaging (Fig 1), myelography, and CT failed to depict a dural defect associated with a pseudomeningocele, digital subtraction myelography was performed. The patient was taken to the angiography suite (our current myelography suite does not have a cine or rapid-sequence capability). The

patient was positioned laterally and underwent a C1–C2 puncture. A rapid subtraction acquisition was performed. After a mask image was obtained, a total of 5 mL of contrast material (Omnipaque 180; Nycomed Amersham, Princeton, NJ) was injected with a hand syringe at a rate of approximately 1 mL/s. Subtraction images were acquired at a rate of one frame per second. Extravasation of contrast material through a high cervical dural defect was immediately identified (Fig 2). Postmyelographic CT images were less convincing but revealed the large fluid collection. The patient then was taken to the operating room, and the level of contrast material extravasation was surgically explored. The dural defect was intraoperatively identified at this level (Fig 3).

### Discussion

Pseudomeningocele should be suspected if the surgeon is aware of a dural tear during the time of the original surgery (5). The diagnosis of this entity is debated in the literature. Initially, myelography was recommended as the technique of choice to establish the diagnosis (5). Other studies have shown myelography to be ineffective (6) and have suggested that CT and MR imaging are the techniques of choice for depicting this entity (2, 7). The diagnosis is further complicated in that a communication between the pseudomeningocele and the subarachnoid space may not exist (2). Often, dural tears leading to pseudomeningoceles are not identified intraoperatively (5). Although myelography, CT, and MR imaging have been described as effective for diagnosing a pseudomeningocele, it remains difficult to localize.

### References

1. D'Andrea F, Maiuri F, Corriero G, Gambardella A, La Tessa G, Gangemi M. **Postoperative lumbar arachnoidal diverticula.** *Surg Neurol* 1985;23:287–290
2. Teplick JG, Peyster RG, Teplick SK, Goodman LR, Haskin ME. **CT identification of postlaminectomy pseudomeningocele.** *AJR Am J Roentgenol* 1983;140:1203–1206
3. Kim YW, Unger JD, Grinsell PJ. **Post-operative pseudodiverticular (spurious meningoceles) of the cervical subarachnoid space.** *Acta Radiol Diagn* 1974;15:16–20
4. Kaar GF, Briggs M, Bashir SH. **Thecal repair in post-surgical pseudomeningocele.** *Br J Neurosurg* 1994;8:703–708
5. Rinaldi I, Hodges TO. **Iatrogenic lumbar meningocele: report of three cases.** *J Neurol Neurosurg Psychiatry* 1970;33:484–492
6. Rinaldi I, Peach WF Jr. **Postoperative lumbar meningocele. Report of two cases.** *J Neurosurg* 1969;30:504–507
7. Murayama S, Numaguchi Y, Whitecloud TS, Brent CR. **Magnetic resonance imaging of post-surgical pseudomeningocele.** *Comput Med Imaging Graph* 1989;13:335–339

Received January 29, 2001; accepted after revision May 22.

From the Department of Radiology, Divisions of Neuroradiology (C.D.P.) and Interventional Neuroradiology (N.R.) and the Department of Neurosurgery and Otolaryngology-Head and Neck Surgery (C.D.P.), University of Virginia Health System Charlottesville, VA; and Department of Neurosurgery (G.J.K.), Loma Linda University Adventist Health Sciences Center, Loma Linda, CA.

Address reprint requests to C. Douglas Phillips, MD, University of Virginia, Department of Radiology, P.O. Box 800170, Charlottesville, VA.

© American Society of Neuroradiology

FIG 1. Sagittal T2-weighted (5400/112 [TR/TE]) cervical MR image depicts fluid dorsal to the posterior fossa and the cervical thecal sac, but no dural leak is identified.

FIG 2. Axial postmyelographic CT demonstrates the pseudomeningocele (arrow) but fails to localize the dural defect.

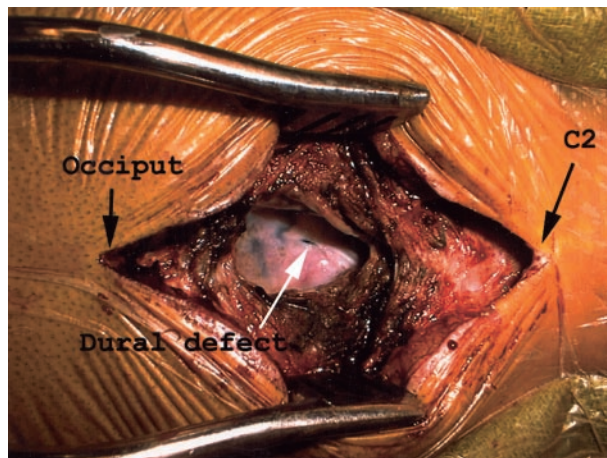
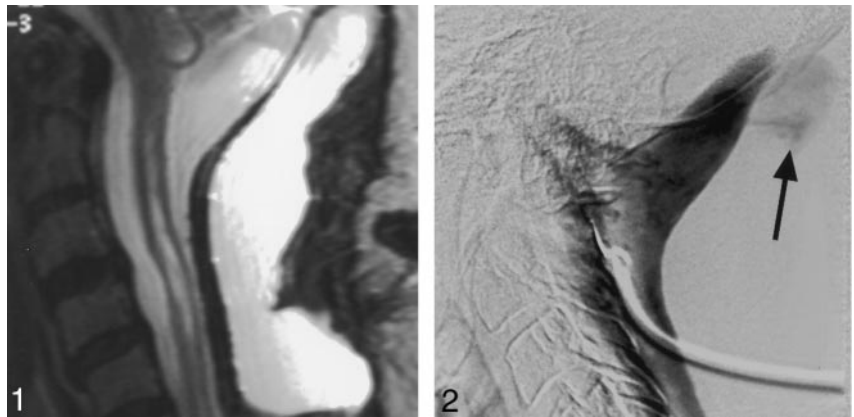


FIG 3. Intraoperative photograph shows the dural defect. Surgical retractors extend from the occiput (patient's left) to the level of C2 (patient's right).