



Get Clarity On Generics

Cost-Effective CT & MRI Contrast Agents

 **FRESENIUS
KABI**

[WATCH VIDEO](#)

AJNR

Vertebrobasilar Transcranial Color-Coded Duplex Ultrasonography: Improvement with Echo Enhancement

Erwin Stolz, Martin Nücker, Irene Mendes, Tibo Gerriets and
Manfred Kaps

This information is current as
of August 25, 2025.

AJNR Am J Neuroradiol 2002, 23 (6) 1051-1054
<http://www.ajnr.org/content/23/6/1051>

Vertebrobasilar Transcranial Color-Coded Duplex Ultrasonography: Improvement with Echo Enhancement

Erwin Stolz, Martin Nüchel, Irene Mendes, Tibo Gerriets, and Manfred Kaps

BACKGROUND AND PURPOSE: The diagnostic yield of vertebrobasilar transcranial color-coded duplex ultrasonography (US) is often hampered by insufficient acoustic penetration, anatomic variations, and vessel tortuosity. The purpose of this study was to evaluate the effect of echo enhancement on vertebrobasilar transcranial color-coded duplex US.

METHODS: In 23 consecutive patients (mean age, 61.0 ± 11.1 years) with vertebrobasilar stroke, the vertebrobasilar system (P1 segment of the posterior cerebral artery [PCA], basilar head, V4 segment of the vertebral artery, and basilar artery) was examined with transcranial color-coded duplex US before and after injection of an echo-enhancer. The acoustic window was graded according to visibility of parenchymal structures, and vessel imaging was graded according to the appearance of the color mode signal. Maximum depth of the basilar color signal was recorded. All patients with an abnormal or inconclusive US finding underwent either digital subtraction angiography or MR angiography.

RESULTS: In the P1 PCA, V4 vertebral artery, basilar artery, and basilar head, image quality was insufficient in 65%, 82%, 83%, and 38%, respectively, before echo enhancement, and in 15%, 30%, 35%, and 9%, respectively, after echo enhancement. In all graded vessels, the improved image quality with echo enhancement was statistically significant. Compared with the reference examinations in the 15 cases of occlusion or stenosis, definite diagnosis was possible in 60% (nine cases) with nonenhanced transcranial color-coded duplex US and in 93% of (14 cases) after echo enhancement.

CONCLUSION: Echo enhancement resulted in improved image quality of the vertebrobasilar system and markedly increased diagnostic confidence.

Similar to transcranial Doppler ultrasonography (US), conventional extracranial color-coded duplex US can provide only indirect diagnostic criteria for vertebrobasilar stenosis or occlusion located at the cranial base or intracranially in the form of changes in the Doppler frequency spectrum. Transcranial color-coded duplex US can depict these anatomic regions. With use of the transtemporal approach, the P1 segment of the posterior cerebral artery (PCA) and, in the coronal plane, the basilar head can be depicted (1). The transforaminal acoustic window allows direct insonation of the V3 and V4 segments of the vertebral artery and the proximal two-thirds of the basilar

artery (2). However, transcranial and transforaminal insonation are often hampered by insufficient acoustic penetration, resulting in a lack of depiction of vessel segments or fragmented color signals. On this background, frequent anatomic variations in the vertebrobasilar region and tortuosities in the vessel course impose further difficulties for transcranial color-coded duplex US examinations in patients with vertebrobasilar stroke.

In this study, we assessed echo enhancement of vertebrobasilar transcranial color-coded duplex US in terms of potential improvement in insonation conditions and diagnostic confidence.

Methods

Patients

Twenty-three consecutive patients (17 men and six women; mean age 61 ± 11.1 years; age range, 28 to 76 years) with a clinical stroke syndrome related to the basilar artery supply (alternant hemiplegia, nystagmus, or diplopia with long tract signs) were referred to our US laboratory and examined within 8 days after onset of symptoms. In all cases, informed consent

Received March 21, 2001; accepted after revision February 21, 2002.

From the Department of Neurology, Justus-Liebig-University, Giessen Germany (all authors); and the Department of Neurology, Hospital Garcia de Orta, Pragal-Almada, Portugal (I.M.).

Address reprint requests to Erwin Stolz, MD, Department of Neurology, Justus-Liebig-University, Am Steg 14, D-35385 Giessen, Germany.

Comparison of image quality before and after application of an echo-enhancing agent

Artery	Without Echo Enhancement			With Echo Enhancement			P Value
	Grade 0	Grade 1	Grade 2	Grade 0	Grade 1	Grade 2	
P1 PCA	11	19	16	4	3	39	<.001
V4 VA	13	25	8	8	6	32	<.001
BA	6	13	4	3	5	15	<.005
Visibility of VA confluents	Not visible, n = 9	Unilateral, n = 8	Bilateral, n = 6	Not visible, n = 2	Unilateral, n = 10	Bilateral, n = 11	<.05
Visibility of BA head	Not visible, n = 10		Visible, n = 13	Not visible, n = 2		Visible, n = 21	<.01

Note.—Data are number of vessels. See Methods for explanation of grades. V4 VA indicates V4 segment of the vertebral artery; BA, basilar artery.

was obtained. The study was carried out in accordance with the institution's ethical guidelines.

US Examinations

In all patients, the extracranial course of the vertebral arteries (V0–V3 segments) was assessed with 7.5-MHz linear and 5-MHz sector transducers (Sonos 2000 US unit; Hewlett Packard, Andover, MA). The transcranial and transforaminal examinations were carried out with a 2.0-MHz phased-array probe. Vertebral artery hypoplasia was diagnosed when the luminal diameter was less than 2 mm and/or a side difference of 50% or greater was documented. A further criterion was the absence of a diastolic zero flow or a reverberating flow pattern in the Doppler frequency spectrum on the affected side.

For the transtemporal insonation, the patients were lying in a supine position with slight head elevation. Transforaminal examinations were performed with the patient lying on the right side and the head bent forward as much as possible. Identification of arterial structures followed previously reported protocols (3–5).

Examinations were carried out by three experienced sonographers (E.S., M.N., I.M.). The quality of the acoustic insonation was assessed both for the transtemporal and the transforaminal approaches and depended on the visibility of parenchymal structures on the following three-point scale: 0, no visibility of mesencephalon or foramen magnum; 1, blurred visibility of the target parenchymal structures; and 2, clear visibility of the mesencephalon or the foramen magnum. The imaging quality of arterial vessel segments was graded in a similar way: 0, a vessel segment was not visible at all; 1, the color signal was fragmented or parts of the vessel segment were visible, but the vessel segment was not visible in its full anatomic course; 2, the vessel segment was visible in its full anatomic course. Depiction of the P1 PCA, V4 vertebral artery, and proximal and middle thirds of the basilar artery was graded in this way. Furthermore, visibility of the basilar head on temporal insonation and visibility of the confluents of the vertebral arteries to the basilar artery via the transforaminal acoustic window (no, unilateral, or bilateral visibility of the confluents to the basilar artery) were recorded. In addition, the maximum insonation depth of the basilar artery was measured in all cases, if possible.

First, the examination was performed without echo enhancement. Then, the pulmonary stable echo-enhancer SH U 508A (Levovist; Schering, Berlin, Germany) was applied by means of an antecubital venous injection in a concentration of 200–300 mg/dL. Injection was performed with multiple small boluses. The results of the transtemporal and transforaminal insonation were compared before and after echo enhancement. All examinations were recorded onto videotape and analyzed offline in terms of imaging quality by two sonographers, who were not involved in the examination, using the above scales. In case of disagreement, the lower (ie, the worse grading) was used for further evaluation of the data. However, the clinical US diagnosis, which depends on the hemodynamic situation at the time of examination, was recorded by the individual sonographer performing the examination.

Reference Examinations

Digital subtraction angiography (n = 5) and MR angiography (n = 11) were available in all patients with abnormal or inconclusive findings at color-coded duplex US. These images were reviewed by the neuroradiologists at our institution, who were aware of the US findings. US and reference examinations were compared in terms of the presence of a vertebrobasilar vessel occlusion or stenosis. However, patients with normal US findings or diagnosis of vertebral artery hypoplasia did not receive a reference examination. At the time of examination, the sonographers were unaware of the result of the reference examination.

Statistical Evaluation

Nominal values of the different gradings, identification frequencies, and inconclusive imaging results were compared with a χ^2 test. The insonation depth of the basilar artery before and after echo enhancement was analyzed with a Wilcoxon matched pairs test. A *P* of less than .05 was considered to indicate a statistically significant difference.

Results

Imaging Results

By the transtemporal route, two (9%) of the 23 patients had no acoustic window (grade 0), five (22%) had restricted visibility (grade 1), and 16 (69%) had a good visibility of the mesencephalon (grade 2). In the transforaminal examination plane, 14 patients (61%) had a medium quality acoustic window (grade 1), and nine (39%) had good insonation conditions (grade 2); a lack of acoustic penetration based on the visibility of the foramen magnum (grade 0) was not encountered.

The Table summarizes the imaging results of the different vessels before and after injection of the echo-enhancing agent. The echo-enhancer significantly improved the visibility of the P1 PCA (*P* < .001), the V4 vertebral artery (*P* < .001), the proximal and middle thirds of the basilar artery (*P* < .005), and the basilar head (*P* < .01). Furthermore, depiction of the confluents of the vertebral arteries to the basilar artery was significantly better (*P* < .05). The maximal insonation depth of the basilar artery in the transforaminal examination plane was significantly increased (*P* < .02) after echo enhancement (before enhancement 8.6 ± 0.6 cm vs after enhancement 9.5 ± 1.5 cm).

Diagnostic Relevance

Before application of the echo-enhancer, conventional extracranial color-coded duplex US revealed

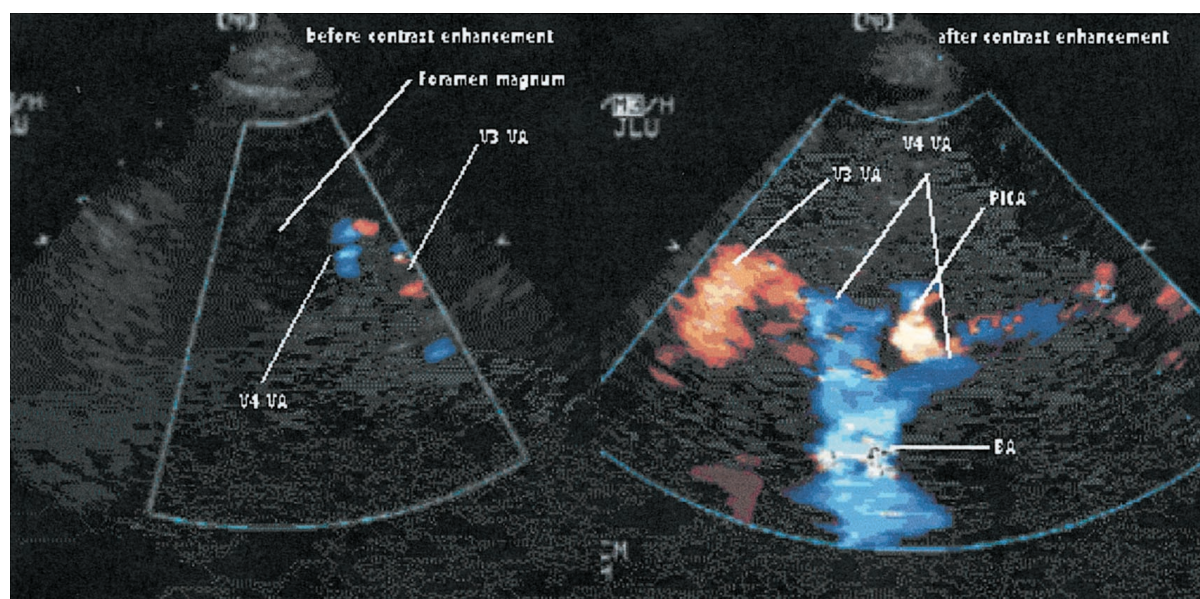


FIG 1. Transforaminal transcranial color-coded duplex sonograms before (left) and after (right) application of an echo-enhancing agent. VA indicates vertebral artery; BA, basilar artery; PICA, posterior inferior cerebellar artery. Before echo enhancement, an occlusion of the intraforaminal part of the vertebral artery might have been falsely assumed.

unilateral vertebral artery hypoplasia in four patients and a distal vertebral artery occlusion in eight patients, based on a reverberating, preocclusive flow pattern in the Doppler frequency spectrum. A proximal vertebral artery occlusion was found in one patient on the extracranial duplex sonogram.

Among the eight cases of distal vertebral artery occlusion, transcranial color-coded duplex US was able to confirm an intracranial occlusion of the V4 segment in three patients. The color signals of the contralateral V4 vertebral artery and of the basilar artery were continuous, the V4 vertebral artery showed a compensatory flow velocity increase (peak systolic flow velocity 70–164 cm/s), and the affected V4 vertebral artery was not depicted. In one patient, the V4 vertebral artery on the symptomatic side on the conventional extracranial duplex sonogram showed a short retrograde color signal, no signal of the V3 vertebral artery, and a compensatory flow velocity increase contralaterally. In the remaining four patients with distal vertebral artery occlusion, transcranial color-coded duplex US was not able to confidently show the intracranial occlusion because either the contralateral V4 could not be depicted or the color signals in the nonaffected vertebral artery and the basilar artery were scarce and fragmented, so that a lack of color signal in the other V4 due to insufficient insonation conditions could not be excluded.

Nonenhanced transcranial color-coded duplex US depicted two basilar artery stenoses (peak systolic flow velocity 165 and 365 cm/s, respectively). In one patient, a basilar head occlusion was suspected where no P1 PCA could be detected bilaterally, and the P2 PCA segments on both sides received flow from the PCA. A similar situation was found unilaterally in a case of P1 PCA occlusion. In three patients, extracra-

nial and transcranial color-coded duplex US showed normal findings. In six (40%) of the 15 abnormal cases, transcranial US alone, not taking into account the extracranial US findings, did not allow a definite diagnosis.

Echo enhancement resulted in more confidence in the diagnosis of occlusion by demonstrating the filling defect of a vessel segment more clearly (Fig 1). After echo enhancement, intracranial occlusion of the vertebral artery could be demonstrated in eight patients. One additional basilar artery stenosis (peak systolic flow velocity 168 cm/s) was diagnosed that was missed on nonenhanced transcranial color-coded duplex sonograms. In total, four patients had normal extracranial and transcranial sonograms after echo enhancement, in whom US was classified as inconclusive before. Transcranial color-coded duplex US with echo enhancement increased significantly the diagnostic confidence ($P < .05$). However, in one (7%) of the 15 abnormal cases, still no definite diagnosis was possible compared with the reference. Remarkably, in this series, one MR angiographic examination also did not allow a definitive diagnosis.

Discussion

In the evaluation of the vertebrobasilar system in patients with stroke, US techniques play an important role owing to their noninvasiveness and bedside capability. Compared with conventional transcranial Doppler US, transcranial color-coded duplex US has the advantage that parenchymal structures and flow signals are displayed in their correct anatomic relationships, thereby improving the correct identification of vessels. This is especially valuable in the vertebrobasilar system where anatomic variations and vessel tortuosity are frequently encountered. The main ob-

stacle for transcranial color-coded duplex US examinations is a limited acoustic penetration through the temporal skull bone or the connective tissue and musculature of the neck. Several studies were able to show that the application of pulmonary stable echo-enhancing agents can increase the diagnostic yield in the anterior cerebral circulation in situations with limited acoustic penetration (6–9). However, data on the effect of echo-enhancing agents for vertebrobasilar transcranial color-coded duplex US are limited (10–12).

Although our patient population was biased toward a high prevalence of abnormal results, the main findings were not affected. Through the transforaminal window, a total lack of acoustic penetration was not observed; however, no or insufficient color signals from the vertebral arteries and the basilar artery were found in 83% and 73%, respectively. A lack of a temporal acoustic window was present in 9% of cases, and insufficient insonation conditions hampered the examination of the P1 PCA and the basilar head in 65% and 38%, respectively. These data are in line with previously reported results (11, 12). Echo enhancement significantly improved the imaging conditions of all graded vascular structures in this study. Furthermore, the maximal insonation depth of the basilar artery was significantly increased to 9.5 ± 1.5 cm. A similar effect was observed in previous reports (10–12). This corresponds to the proximal and middle thirds of the basilar artery in postmortem studies (2). The basilar head was visible in 91% of cases after echo enhancement, compared with 57% at nonenhanced transcranial color-coded duplex US.

Besides improving the image quality, an important finding of this study is the increased confidence in diagnosing vessel occlusion or stenosis. Although generally undesirable, the blooming artifact (13) after application of a bolus of an echo-enhancer reduces the diagnostic problem to a first sight diagnosis by clearly showing a filling defect. Compared with the reference examinations, the rate of inconclusive vertebrobasilar transcranial color-coded duplex US examinations could be decreased significantly by echo enhancement. In fact, all abnormal results diagnosed with transcranial color-coded duplex US with echo enhancement were confirmed with either digital sub-

traction angiography or MR angiography. Only one transcranial duplex US examination remained inconclusive. This result corresponds to the findings of the only, to our knowledge, reference-controlled study evaluating vertebrobasilar transcranial color-coded duplex US with echo enhancement (10).

In summary, echo enhancement not only improves the image quality of vertebrobasilar transcranial color-coded duplex US, but also increases the diagnostic confidence in abnormal cases.

References

1. Von Reutern G, Kaps M, von Büdingen G, eds. **Ultraschalldiagnostik der Hirnversorgenden Arterien**. Stuttgart, Germany: Thieme Verlag; 2000:124–159
2. Schulte-Atedorneburg G, Droste DW, Popa V, et al. **Visualization of the basilar artery by transcranial color-coded duplex sonography: comparison with postmortem results**. *Stroke* 2000;31:1123–1127
3. Schöning M, Walter J. **Evaluation of the vertebrobasilar-posterior system by transcranial color-coded duplex sonography**. *Stroke* 1992;23:1280–1286
4. Kaps M, Seidel G, Bauer T, Behrmann B. **Imaging of the intracranial vertebrobasilar system using color-coded ultrasound**. *Stroke* 1992;23:1577–1582
5. Becker G, Lindner A, Bogdahn U. **Imaging of the vertebrobasilar system by transcranial color-coded real-time sonography**. *J Ultrasound Med* 1993;12:395–401
6. Gerriets T, Seidel G, Fiss I, Modrau B, Kaps M. **Contrast-enhanced transcranial color-coded duplex sonography: efficiency and validity**. *Neurology* 1999;52:1133–1137
7. Postert T, Braun B, Federlein J, Przuntek H, Köster O, Büttner T. **Diagnosis and monitoring of middle cerebral artery occlusion with contrast-enhanced transcranial color-coded real-time sonography in patients with inadequate acoustic bone windows**. *Ultrasound Med Biol* 1998;24:333–340
8. Nabavi D, Droste D, Kemény V, Schulte-Atedorneburg G, Weber S, Ringelstein EB. **Potential and limitations of echocontrast-enhanced ultrasonography in acute stroke patients**. *Stroke* 1998;29:949–954
9. Görtler M, Kross R, Bäumer M, et al. **Diagnostic impact and prognostic relevance of early contrast-enhanced transcranial color-coded duplex sonography in acute stroke**. *Stroke* 1998;29:955–962
10. Droste DW, Nabavi DG, Kemény V, et al. **Echocontrast enhanced transcranial colour-coded duplex offers improved visualization of the vertebrobasilar system**. *Acta Neurol Scand* 1998;98:193–199
11. Brunner-Beeg F, von Reutern GM. **Farbduplexsonographie des intrakraniellen vertebrobasilären systems: verbesserung der darstellung durch echosignalverstärker**. *Ultraschall Med* 1999;20:83–86
12. Iglseider B, Huemer M, Staffen W, Ladurner G. **Imaging the basilar artery by contrast-enhanced color-coded ultrasound**. *J Neuroimaging* 2000;10:195–199
13. Forsberg F, Liu JB, Burns PN, et al. **Artifacts in ultrasonic contrast agent studies**. *J Ultrasound Med* 1994;13:357–365