



Get Clarity On Generics

Cost-Effective CT & MRI Contrast Agents



FRESENIUS
KABI

WATCH VIDEO

AJNR

Pocket Atlas Series

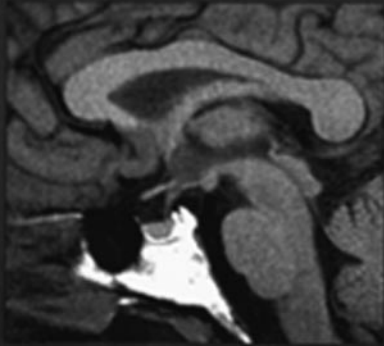
AJNR Am J Neuroradiol 2002, 23 (9) 1612-1613
<http://www.ajnr.org/content/23/9/1612>

This information is current as
of August 14, 2025.

Pocket Atlas of Cranial Magnetic Resonance Imaging

SECOND EDITION

Scott W. Atlas
Richard T. Kaplan

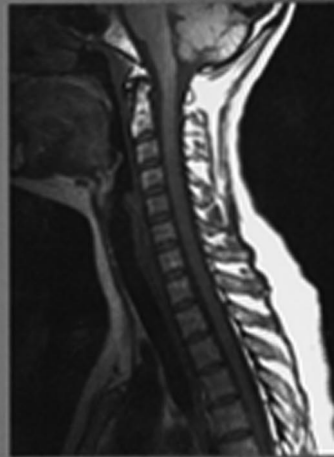


LIPPINCOTT WILLIAMS & WILKINS

Pocket Atlas of Normal Spine MRI

SECOND EDITION

Leo F. Czervionke

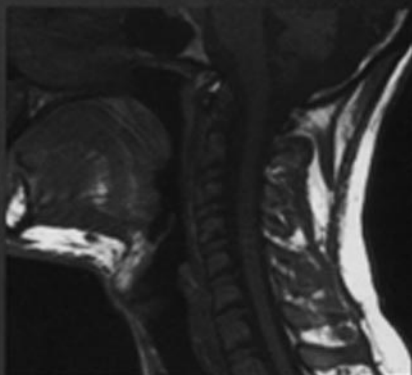


LIPPINCOTT WILLIAMS & WILKINS

Pocket Atlas of Head and Neck MRI Anatomy

SECOND EDITION

Robert B. Lufkin

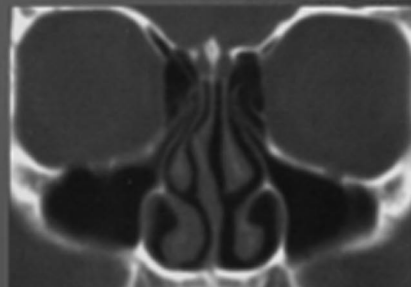


LIPPINCOTT WILLIAMS & WILKINS

Pocket Atlas of Normal CT Anatomy of the Head and Brain

SECOND EDITION

Michelle M. Smith
Timothy L. Smith



LIPPINCOTT WILLIAMS & WILKINS

Book Review**Pocket Atlas Series**

I find that I am drawn to any book with "Pocket" in the title. I suppose it is part of the same appeal of those giant Swiss Army knives with the spoons and magnifying glasses. Yes, there is something desirable about having a very useful item that fits neatly into one's pocket. Just look at the more recent success of the now ubiquitous personal digital assistants (PDAs) and the "Leatherman" tools. But it is more than just being small; it should also be something that one expects to be large that somehow gets squeezed into that small shape. Who wouldn't just love to have that car that George Jetson drove? You know, the one that folded up into a briefcase when he got to work. And unlike a library book or a \$25 hardback that returns to the shelf looking pretty much the same as when you started reading it, pocket books take on a very personalized appearance after a bit. I still have the wonderfully worn and now yellow copy of the Penguin *Pocket Book of Verse* that my Father carried with him in his deployments during World War II.

So I was delighted to receive four pocket books to review in the mail. These make up the second and recent edition of a series with the titles *Pocket Atlas of Cranial Magnetic Resonance Imaging*, *Pocket Atlas of Normal Spine MRI*, *Pocket Atlas of Head and Neck MRI Anatomy*, and *Pocket Atlas of the Normal CT Anatomy of the Head and Brain*. They really are pocket sized—well, not shirt pocket sized, but they fit pretty nicely in a white coat pocket. Although each of the four books is written by different authors, they are of fairly uniform style and quality.

The *Pocket Atlas of Cranial Magnetic Resonance Imaging* is divided into sagittal, axial, and coronal images with addition chapters on the sella and MR angiography. Each page follows a standard format of showing one large image with labeled structures below a smaller image in different planes, with a reference line to indicate the level of the section. There are approximately 10 items labeled on each image. The authors have chosen to label what I would consider basic anatomy, such as pons, medulla, and genu of the corpus callosum. The authors have reached a reasonable compromise with enough labels to be of value but not so many as to obscure the image.

The *Pocket Atlas of Normal Spine MRI* varies only slightly in format. In this book, the author has chosen to put the reference image at the beginning of each chapter, which leaves more space for the image and labels. There are nearly twice as many structures labeled on each page, with a more sophisticated audience in mind. For example, I learned that I have been mistaking the "obex" for the "clava" all these years. There is one other feature unique to this book: anatomic sections and MR images of cadavers. Although the sections are unfortunately not in color, they are well chosen and

highlight fine anatomy, such as the exiting rootlets and the dorsal root ganglia in the cervical spine. This book of the four has some of the clearest pictures and most detailed anatomy, including the muscles of the neck and back.

The *Pocket Atlas of Head and Neck MRI Anatomy* is divided into chapters on the larynx, oropharynx, nasopharynx, temporal bones, orbit, and temporomandibular joint dysfunction. This book again uses the format of reference images with no more than 10 labeled structures on each page. This book could have been considerably improved with photography of each of the images without the text and by using high resolution surface coil images of the temporal bone structures. For example, the 7th and 8th nerves cannot be resolved on the images of the internal auditory canal.

The last book in this series, *Pocket Atlas of the Normal CT Anatomy of the Head and Brain*, provides more than the title suggests. There are chapters on the paranasal sinuses as well as temporal bones. These last two chapters can be valuable if you only occasionally look at these scans in your practice. Although no reference images are used in this book, four to 13 basic structures are labeled on each image.

Although I found all the books well intentioned, I couldn't help thinking how much better they would have been with some more attention to printing. This was particularly evident regarding CT anatomy of the brain. On most of the scans, there is little or no contrast between the gray and white matter of the brain. The temporal bone scans are also disappointing because most modern scanners routinely produce better scans than these. This problem was not unique to this book of the set; similar contrast issues were evident in all four books. For a series that is basically about imaging, there seemed to be less than a full commitment to providing the best possible images. I am guessing that this is linked to the cost of printing because these books retail for less than \$20 each. Although the image quality is sufficient to show the labeled anatomic structures, the images do not capture the beauty of modern CT scans and MR images. I also couldn't help thinking that this information would be more accessible in a software version suitable for PDAs. I suppose that may have to wait for better display technology.

These books, of a size that allows them to be easily carried in a white coat pocket, contain a tremendous fund of practical anatomy useful to radiologists. All four fulfill the promise of the pocket in their title. To avoid overloading the images with arrows and labels, the books focus on basic anatomy. I think they would be most suitable for medical students on radiology electives and especially for radiology residents on their MR imaging and CT rotations. If they chose to dedicate themselves to a study of the anatomy described in any one of these books, they would find their \$20 well spent.