



## Discover Generics

Cost-Effective CT & MRI Contrast Agents



FRESENIUS  
KABI

WATCH VIDEO

# AJNR

## Cystic Hygroma of the Neck: Association with a Growing Venous Aneurysm

Erini Makariou, Andreas Pikis and Earl H. Harley

*AJNR Am J Neuroradiol* 2003, 24 (10) 2102-2104

<http://www.ajnr.org/content/24/10/2102>

This information is current as  
of June 3, 2025.

## Case Report

# Cystic Hygroma of the Neck: Association with a Growing Venous Aneurysm

Erini Makariou, Andreas Pikis, and Earl H. Harley

**Summary:** Venous anomalies are rarely seen with cystic hygromas. We describe an unusual case of cystic hygroma of the neck associated with a saccular venous aneurysm that was increasing in size. A multi-modality examination of the neck—including CT, Doppler sonography, and MR imaging—revealed multiloculated cystic lesions bilaterally with predominance on the left side. A saccular venous aneurysm was noted within one of the sacs. Comparison with previous CT images showed that the aneurysm enlarged from  $0.8 \times 0.5 \times 1.5$  cm to  $3.0 \times 1.3 \times 2.1$  cm over 2 years. Identification of these malformations before surgery is critical.

Cystic hygromas/lymphangiomas are developmental anomalies of vasculolymphatic origin. They can arise anywhere along the lymphatic system; however, they are usually located in the head and neck region and in most cases (80–90%) appear by the age of 2 years (1). Enlargement of these cystic lesions is common and may compress the adjacent organs, causing respiratory distress, feeding difficulties, or vascular compromise (2). Radiologic evaluation of the cystic hygromas includes conventional radiography, sonography, CT, and MR imaging (3–6). The association of cystic hygromas and vascular malformations is extremely rare. In the only two reported series (7, 8), cystic hygroma was associated with ectasia of the large vessels of the neck and upper trunk. In this report, we describe an unusual case of a pathologically proved cystic hygroma with a growing saccular venous aneurysm within one of its sacs.

## Case Report

A 4-year-old girl with a known history of cystic hygroma of the neck diagnosed at the age of 2 years was referred for a painful left neck mass enlarging in size over a period of 2 days. An enhanced CT study of the neck, including sagittal and coronal reconstructed images, revealed multiloculated cystic lesions on both sides of the neck spreading through the soft tissues. The major component of the cystic hygroma involved the left side of the neck from the level of the parotid gland to

the thoracic inlet. A well-defined ovoid vascular lesion, measuring  $3.0 \times 1.3 \times 2.1$  cm, was observed within one of the cystic components, most likely originating from the left posterior facial vein (Fig 1A). For complete evaluation of the lesions, contrast-enhanced MR imaging of the neck was also performed, which confirmed the CT findings. To differentiate the arterial from the venous nature of this vascular abnormality, we performed MR angiography and Doppler sonography. The MR angiogram delineated normal arteries, whereas the Doppler sonography study showed low-velocity venous blood flow within the vascular lesion (Fig 1B).

The results of the current imaging studies were compared with those from three previous CT studies of the neck. The first one was performed at the age of 2 years, when the child came to the emergency room with breathing difficulties. At that time, an enhanced CT study of the neck showed cystic lesions on both sides and at the base of the tongue. In addition, a vascular structure ( $0.8 \times 0.5 \times 1.5$  cm; Fig 1C) was seen within one of the left posterior cystic components but was not initially considered a pathologic finding. There was also moderate enlargement of the adenoids and tonsils, which, together with the cystic lesion of the tongue, was obstructing the airway. Tonsillectomy and adenoidectomy were performed to free the airway, and the cystic lesion at the base of the tongue was excised. The clinical diagnosis of cystic hygroma was confirmed by histologic results. The patient was referred to another institution for nonsurgical treatment with the experimental drug OK-432, a sclerosing agent; however, the family failed to follow-up with that referral. Two subsequent CT studies of the neck done in a community hospital were reviewed during the current admission. The first follow-up CT study was performed 10 months after the diagnosis, and the second 8 months later. Both showed enlargement of the multiloculated cystic hygromas and the vascular lesion. The size of the vascular lesion increased to  $2.0 \times 1.0 \times 1.6$  cm in the first follow-up CT study and  $2.8 \times 1.2 \times 1.8$  cm in the second.

Because of the increasing size and pain during the current admission, it was elected to remove the lesions surgically. An approach through the digastric triangle was used to access the submandibular and parapharyngeal cysts. A modified Blair incision with positive identification of the branches of the facial nerve was used in excising the intraparotid lesions. Multiple lymph-filled sacs were encountered. A cystic area with old hemorrhagic elements due to prior bleeding was observed in the left side of the neck posterolateral to the mandibular angle. Within this sac, there was a saccular venous aneurysm originating from the left posterior facial vein (Fig 2). This vein was ligated and the aneurysm resected. The patient tolerated the procedure well and suffered only minor weakness of the marginal mandibular branch of the facial nerve.

## Discussion

The embryology of the lymphatic system is complicated and not yet well understood. Different theories concerning the origin of the lymphatic system have been suggested (1). Initially, a theory of a venous origin with centrifugal spread was introduced by Sabin.

Received March 8, 2003; accepted after revision April 6.

From the Departments of Radiology (E.M.) and Otolaryngology-Head and Neck Surgery (E.H.H.), Georgetown University Medical Center, Washington, DC; and the National Institute of Dental and Craniofacial Research, Oral Infection and Immunity Branch, Bethesda, MD (A.P.)

Address correspondence to Erini Makariou, M.D., Department of Radiology, Georgetown University Medical Center, 3800 Reservoir Road NW, Washington, DC 20007.

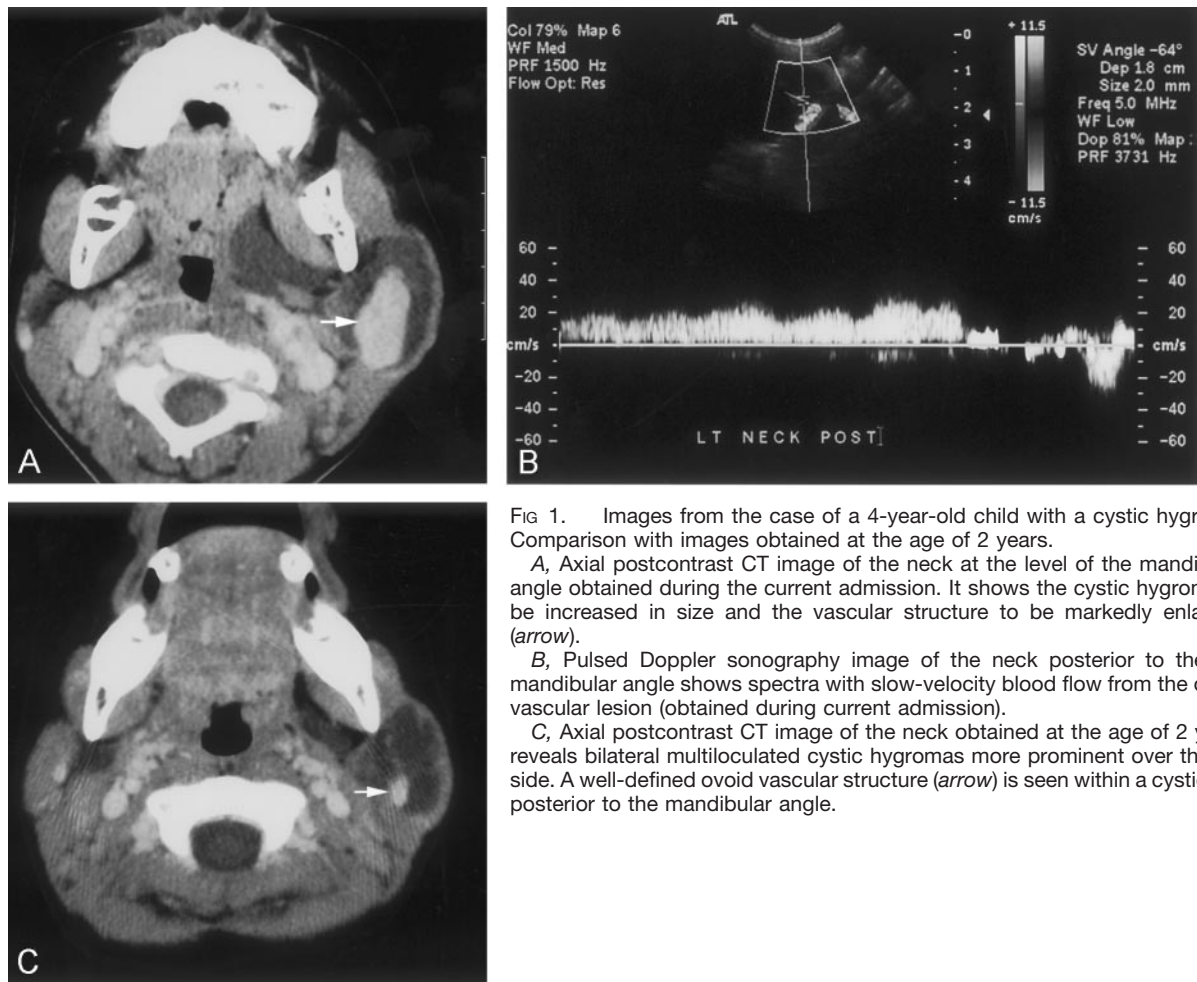


FIG 1. Images from the case of a 4-year-old child with a cystic hygroma. Comparison with images obtained at the age of 2 years.

A, Axial postcontrast CT image of the neck at the level of the mandibular angle obtained during the current admission. It shows the cystic hygroma to be increased in size and the vascular structure to be markedly enlarged (arrow).

B, Pulsed Doppler sonography image of the neck posterior to the left mandibular angle shows spectra with slow-velocity blood flow from the ovoid vascular lesion (obtained during current admission).

C, Axial postcontrast CT image of the neck obtained at the age of 2 years reveals bilateral multiloculated cystic hygromas more prominent over the left side. A well-defined ovoid vascular structure (arrow) is seen within a cystic sac posterior to the mandibular angle.

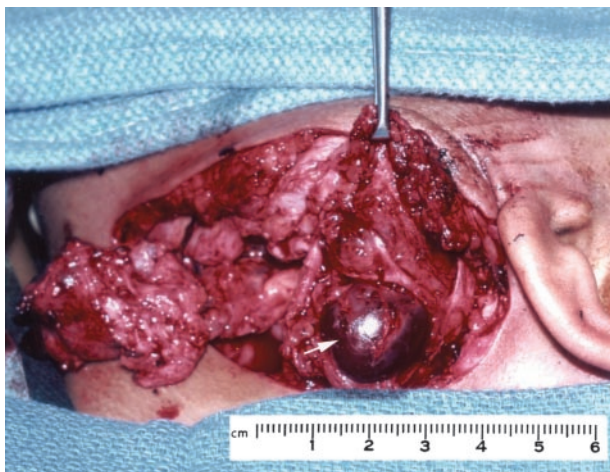


FIG 2. Intraoperative image demonstrates a large aneurysm (arrow) adjacent to an intact parotid gland. The aneurysm originated from the left posterior facial vein.

Then, a theory of mesenchymal origin with centripetal spread was proposed by Huntington and McClure and later by Kampmeier. Van der Jagt and Kutsuna supported a theory of combined venous and mesenchymal origin. Recently, the origin of the lymphatic system from seven double and two isolated primordia

was addressed by van der Putte. He agreed with Sabin that the lymphatic structures have venous origin and subsequent development is due to centrifugal growth and sprouting. Under this theory, vasculolymphatic malformations may coexist when the mesenchyma of the venous bud is not able to differentiate fully into a purely lymphatic structure. Vascular characteristics are maintained with the lymphatic malformations and both anomalies maintain their ability to grow during time. Therefore, it seems that the association between cystic hygroma and congenital venous malformation is not coincidental. In fact, previously reported cases (7, 8), in conjunction with the present case, support the coexistence of these malformations. In 1989, Joseph et al (7) reported that eight of 15 patients with mediastinal cystic hygroma were found to have abnormal enlargement of the superior vena cava. Three years later, Gorenstein et al (8) reported another two cases with cystic hygroma associated with venous malformations. It is noteworthy that all reported cases were associated with dilatations of the large veins adjacent to cystic hygromas (eg, superior vena cava) and the patients had no signs of venous dysfunction. To the best of our knowledge, ours is the first case to show a growing saccular venous aneurysm within one of the sacs of the cystic hygroma.

Cystic hygromas are congenital vasculolymphatic

malformations that are frequently present at birth. They have no predilection for sex or race, and they have no malignant potential. Typical cystic hygromas cause no symptoms unless they enlarge in size or surround or invade adjacent normal anatomic structures. In this situation, cystic hygromas may cause symptoms such as feeding problems or breathing difficulties (2). Cystic hygromas are multilobulated, thin-wall, lymph-containing sacs. The fluid within the sacs is usually clear or amber colored, although occasionally it could be turbid or hemorrhagic. After a clinical evaluation, radiologic assessment by using CT, sonography, and MR imaging is useful to confirm the diagnosis and define the extension of the cystic lesions and their relationship to adjacent structures (3–6). In most cases, there is no difficulty in the diagnosis of cystic hygroma. A diagnostic dilemma may occur, however, if a cystic hygroma containing a suspicious vascular anomaly is seen in the lower neck or upper mediastinum. In this case, the vascular malformation should be differentiated from a thoracic duct aneurysm. Excision is the treatment of choice and is recommended as soon as the diagnosis is established, because the incidence of infection, hemorrhage, and growth increases with time. Other methods of treatment such as aspiration, incision and drainage, irradiation, and chemical sclerosis have not produced acceptable results (9).

### Conclusion

The association of cystic hygromas and venous anomalies/aneurysms calls for extra attention in caring for these patients. Preoperative identification of the presence and exact origin of these vascular anomalies is very important. This information can help to delineate the vascular surgical map and avoid com-

plications during surgical exploration. Although we mainly use CT with reconstructed images to evaluate the neck lesions and analyze their relationship to adjacent anatomic structures, we believe that color Doppler sonography is a reliable and quick tool to evaluate any suspicious vascular anomaly associated with cystic hygromas. CT angiography in expert hands could be very helpful if more vascular detail is needed (10). It should be pointed out, however, that it is more invasive and needs iodinated contrast material and ionizing radiation.

### References

1. Zadvinskis DP, Benson MT, Kerr HH, et al. **Congenital malformations of the cervicothoracic lymphatic system: embryology and pathogenesis.** *Radiographics* 1992;12:1175–1189
2. Kostopoulos GK, Fessatidis JT, Hevas AL, Skordalaki AS, Spyrou PG. **Mediastinal cystic hygroma: report of a case with review of the literature.** *Eur J Cardiothorac Surg* 1993;7:166–167
3. Siegel MJ, Glazer HS, St Amour TE, Rosenthal DD. **Lymphangiomas in children: MR imaging.** *Radiology* 1989;170:467–470
4. Yuh WT, Buehner LS, Kao SC, Robinson RA, Dolan KD, Phillips JJ. **Magnetic resonance imaging of pediatric head and neck cystic hygromas.** *Ann Otol Rhinol Laryngol* 1991;100:737–742
5. Borecky N, Gudinchet F, Laurini R, Duvoisin B, Hohlfeld J, Schnyder P. **Imaging of cervico-thoracic lymphangiomas in children.** *Pediatr Radiol* 1995;25:127–130
6. Fung K, Poenaru D, Soboleski DA, Kamal IM. **Impact of magnetic resonance imaging on the surgical management of cystic hygromas.** *J Pediatric Surg* 1998;33:839–841
7. Joseph AE, Donaldson JS, Reynolds M. **Neck and thorax venous aneurysm: association with cystic hygroma.** *Radiology* 1989;170:109–112
8. Gorenstein A, Katz S, Rein A, Schiller M. **Giant cystic hygroma associated with venous aneurysm.** *J Pediatric Surg* 1992;27:1504–1506
9. Hancock BJ, St-Vil D, Luks FI, Di Lorenzo M, Blanchard H. **Complications of lymphangiomas in children.** *J Pediatr Surg* 1992;27:220–226
10. Stehling MK, Lawrence JA, Weintraub JL, Raptopoulos V. **CT angiography: expanded clinical applications.** *AJR Am J Roentgenol* 1994;163:947–955