



## Discover Generics

Cost-Effective CT & MRI Contrast Agents



FRESENIUS  
KABI

WATCH VIDEO

# AJNR

## Imaging Cerebrovascular Disease

*AJNR Am J Neuroradiol* 2003, 24 (10) 2117-2118  
<http://www.ajnr.org/content/24/10/2117>

This information is current as  
of June 2, 2025.

### Imaging Cerebrovascular Disease

V. L. Babikian, L. R. Wechsler, and R. T. Higashida, eds. Philadelphia: Butterworth Heinemann; 2003. 425 pages, 400 illustrations. \$149.00.

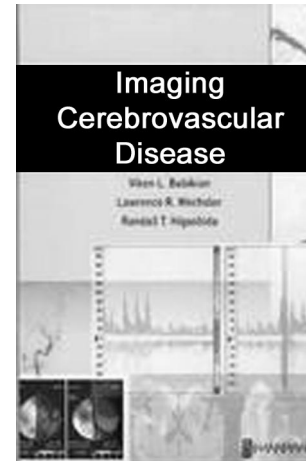
Contributors to this book include neurologists, neuroradiologists, neurosurgeons, and imaging scientists specializing in both ischemic and hemorrhagic stroke.

The book is divided into five sections: vascular imaging, cerebral blood flow, ischemic disease, hemorrhagic disease, and recent developments in the field. Although each could stand on its own, incongruities exist within the volume. For instance, the section dealing with cerebral infarction describes “hemorrhagic transformation” but neglects to include “petechiae.” By contrast, the section on bleeding mentions that up to 71% of infarctions have petechiae.

Sections dealing with sonography, MR angiography (MRA), and CT angiography (CTA) each could stand alone for technique, use, and limitations; however, the discussions do not clearly delineate recent from obsolete techniques. For example, multisection CT has advanced so that 16-section CTA is better than four-section and four-section is better than one-section, but in this volume CTA is just CTA. The discussion of the pitfalls of carotid sonography omits mention of problems in recognizing anatomic reversal where the internal carotid is medial and external lateral (which occurs in 10–15% of cases). This variation justifies that patients should always have confirmatory vascular imaging when duplex shows stenosis, although this pitfall is not mentioned.

The section on MRA gives an overview of various techniques explaining different approaches, and the section on CTA describes postprocessing techniques. Not stressed, however, is that for CTA multidirectional 2D reformats can easily be performed by technologists, adding just seconds of work, enabling CTA to be a quick technologist-driven procedure. The alternative used by many of physicians driving 3D workstations for 3D images is tedious, yet can be still be done when all answers cannot be worked out by 2D.

The authors declare angiography to be a “safe technique,” without mentioning any safety protocol; a lost opportunity to preach about safety and vigilance. There is also no discussion of 1.2% angiographic stroke from the Asymptomatic Carotid Artery Surgery Trial (ACAS) used to justify treatment with sonography alone. Differing stenosis methods are described, yet the “NASCET method” is misquoted. Before measuring stenosis, NASCET always sought cases with near occlusion, prescribing calculations only when no near occlusion was seen. A declared hazard here, that NASCET (North American Symptomatic Carotid Endarterectomy Trial) underestimates stenosis measurement for cases with near occlusion, is incorrect: NASCET never measured them, because it is fallacious to do so. ECST compared



stenosis diameter with the imagined bulb but did not measure the distal ICA as stated here. Thus, the authors display a lack of familiarity with how both NASCET and ECST measured stenosis.

Regional cerebral blood flow is expressed in milliliters per 100 g brain per minute. Neuroradiologists may forget this principle, the “holy grail” of CBF, yet volume of blood per unit of time or peak of contrast arrival are easy to measure with MR perfusion. The authors discussing MR perfusion give their own experience with CT perfusion. That there is no chapter on CT perfusion is an omission, especially from Ting Y. Lee, whose CT perfusion method includes real flow as ml/100 g/min. Lee’s method is easy to perform, can be added to CTA, and is offered as a “stroke package” by a major vendor.

“Luxury perfusion” of infarction is “relative hyperemia where blood flow exceeds metabolic requirements through tissue acidosis” and yet often refers to pial collaterals, enhancement, arteriovenous shunt surgery, and others. It would be best if the term could be restricted only to cases fitting a clear definition, although an imaging definition is still needed. Positron emission tomography goes further with “misery perfusion,” a “reaction of autoregulation stimulated by hypoperfusion.” There is nothing offered here to reconcile misery perfusion with luxury perfusion.

Physiologic studies adding information to stroke assessment are often accompanied by poor CT images. The authors may show how good the new examination is (eg, Fig 7 for single-photon emission tomography), but a CT image simply makes the point that promoters of one technique may not know the best of another.

The section on acute stroke management contains many pearls. For example, the 3-hour window for thrombolytic treatment is being extended. The chap-

ter on hypertensive hemorrhage quotes the 1961 work by Miller Fisher but does not refer to his 1980 sequel in which pathology material for lobar bleeds was identified as amyloid angiopathy. Miller Fisher concluded that lobar bleeding in elderly nontraumatic, nontumor patients should be considered amyloid angiopathy, even in hypertensive patients.

It is interesting that this book deals mainly with particular neurologists and interventional neuroradiologists and their own practices. Unfortunately, the

editors do not coordinate the chapters. It is uncertain why CT perfusion advances are not highlighted. Perhaps institutional and technique politics determined the book's content.

This book is intended as a thorough overview of stroke imaging, and it mostly succeeds. It is useful to summarize recent approaches for students, residents, and stroke practitioners. This is a fast-moving field, and readers are cautioned to confirm current practice before adopting specific technical protocols.