

Generic Contrast Agents

Our portfolio is growing to serve you better. Now you have a *choice*.



[VIEW CATALOG](#)

AJNR

Fluoroscopy Fade for Embolization of Vein of Galen Malformation

Curtis A. Given, Ike C. Thacker, Michael D. Baker and P. Pearse Morris

AJNR Am J Neuroradiol 2003, 24 (2) 267-270

<http://www.ajnr.org/content/24/2/267>

This information is current as of May 24, 2025.

Fluoroscopy Fade for Embolization of Vein of Galen Malformation

Curtis A. Given, Ike C. Thacker, Michael D. Baker, and P. Pearse Morris

Summary: A fluoroscopy fade technique in the embolization of a vein of Galen malformation in a 10-week-old infant is discussed herein. The availability of the fluoroscopy fade function eliminated the necessity of road mapping during the procedure and permitted minimal usage of contrast material and minimal radiation exposure for the patient. Techniques used during the embolization and the benefits of the fluoroscopy fade feature are also described.

Neurointerventional embolization procedures are relatively rare occurrences in the pediatric population. When encountered, they require special consideration regarding both radiation dosage and contrast material volume. We herein present the case of a 10-week-old, 3900-g infant in whom a vein of Galen malformation was successfully treated primarily by using a fluoroscopy fade technique. We discuss the beneficial effects of this technique in our anecdotal report. Fluoroscopy fade entails overlaying a referenced image from a digital subtraction angiogram onto the real-time fluoroscopic display. The fluoroscopy fade feature can substantially reduce the volume of contrast material required to perform an embolization procedure and can reduce radiation exposure for the patient. Fluoroscopy fade should be considered as an additional radiation dose reduction technique, along with dose spreading, low dose settings, and pulsed fluoroscopy (1, 2).

Technical Description

A 3.9-kg male neonate with a symptomatic vein of Galen malformation was treated successfully during a single embolization session that resulted in complete elimination of the malformation and immediate resolution of symptoms of cardiac failure. After prenatal sonographic diagnosis of the malformation, the patient was initially managed medically for symptoms of heart failure. By 10 weeks of age, however, his cardiovascular status became progressively unmanageable. Axial view images showed that the venous pouch had increased in size from a maximum diameter of 2.0 cm (at 1 week of age) to 3.5 cm and that hydrocephalus was developing.

Embolization was performed in a Siemens Neurostar Plus T.O.P. angiography suite with the patient under general anesthesia. The right common femoral artery was punctured and

dilated to accommodate a 4F vascular sheath. A 4F 0.038-inch inner diameter catheter was used to perform digital angiography of the left vertebral artery and was then used for coaxial introduction of a Renegade microcatheter (Target, Fremont, CA). Using the fluoroscopy fade feature that is available on the Siemens Neurostar angiography unit, an image from the digital subtraction angiography run was referenced and used as a fluoroscopy overlay image to guide the microcatheter over a 0.014-inch Synchro microwire (Precision Vascular, West Valley City, UT) into the feeding arterial pedicles without additional administration of contrast material or the need for dedicated road mapping (Figs 1–7). Fluoroscopy was pulsed at three frames per second in the fluoroscopy fade mode.

The transarterial route of venous packing of the vein of Galen soon appeared to be inadvisable as the venous pouch proved too capacious for the vein of Galen coils (Fig 1), which merely tumbled within the malformation and gathered at the venous outflow. Fear of premature obstruction of the venous outlet and resultant rupture of the malformation prompted embolization of the fistulous communication and arterial feeders. Packing of the arterial pedicles at the site of fistulous connection to the venous pouch was then performed in three locations by using 2- and 3-mm fibered VortX GDCs (Target). Heparinization was continued for 24 hours, and the patient was discharged 2 days later with all medications discontinued.

Total fluoroscopy times were 28.4 minutes in the anteroposterior plane and 30 minutes in the lateral plane. Three digital runs via the introducer catheter were performed by using 5 mL per run, left vertebral artery before and after treatment, and left internal carotid artery after treatment. Nine digital runs via the microcatheter were performed by using 1 mL per run, for a total dose of contrast material of 24 mL of Optiray 240. Based on the indirect method of monitoring patient skin entrance exposure used by the Neurostar angiography unit (ionization chamber located within the collimator), the estimated entrance skin doses for the anteroposterior and lateral projections were 320 and 160 mGy, respectively (combined entrance skin dose of 480 mGy). The duration of the entire procedure was approximately 4 hours.

Discussion

Neurointerventional procedures for the pediatric patient (especially the neonate) are a rare occurrence, and few published data are available regarding the radiation dosage encountered and its effect on this small subset of patients. Much like the stochastic effects of a neurointerventional procedure on any patient, the deterministic effects are equally difficult to estimate in the pediatric patient, with much information being extrapolated from adult counterparts. Deterministic effects that could be encountered during embolization procedures include cataracts, erythema, and epilation (1). Currently, no maximum dose limitations exist for fluoroscopy in the digital subtraction angiography and cine imaging modes (1). For routine fluoroscopy, the skin entrance exposure

Received June 6, 2002; accepted after revision June 18.

From the Department of Neuroradiology, Wake Forest University Baptist Medical Center, Winston-Salem, NC.

Address reprint requests to P. Pearse Morris, MB, BCh, Department of Neuroradiology, 2nd Floor, Meads Hall, Wake Forest University Baptist Medical Center, Medical Center Boulevard, Winston-Salem, NC 27157.



FIG 1. Anteroposterior projection left vertebral catheter injection digital subtraction angiogram shows hypertrophy of several posterior choroidal branches (*arrow*) arising from the right posterior cerebral artery and supplying a mural-type vein of Galen malformation. The malformation is also fed in a retrograde fashion from the left posterior communicating artery. Note wash-in of unopacified blood (*arrowhead*) retrograde from the P1 segment of the left posterior cerebral artery.

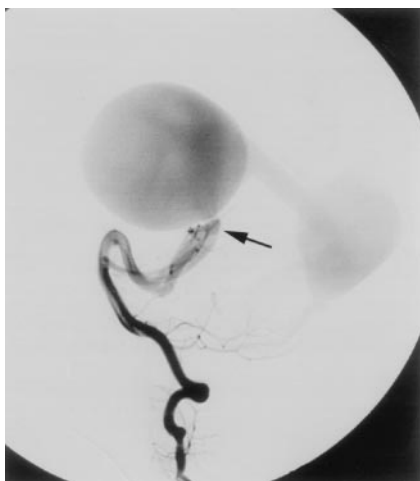


FIG 2. As in Figure 1, except lateral projection.

limitations are set at 10 R/min for normal fluoroscopy and 20 R/min for "high dose" fluoroscopy (1). Early (transient) erythema and epilation have been reported to occur in association with single dose threshold entrance skin doses of 2 and 3 Gy, respectively (1). Although the typical embolization procedure has been reported to result in a mean entrance skin dose of only 340 mGy (3), the deterministic threshold of 2 Gy is often easily reached (or even surpassed) during an embolization procedure (1, 2, 4, 5). Every attempt should be made during the procedure to minimize patient exposure, especially in the pediatric population.

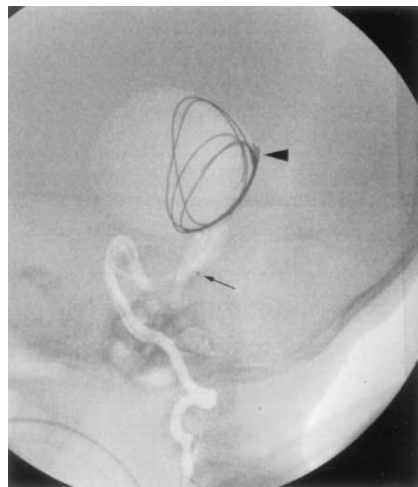


FIG 3. Lateral projection of the fluoroscopy fade image generated from the digital subtraction angiogram shown in Figure 2. The microcatheter (*arrow* on proximal marker) has passed through the fistulous communication into the venous pouch. Four vein of Galen coils have been deployed within the venous pouch but have migrated to cover the venous outflow (*arrowhead*).

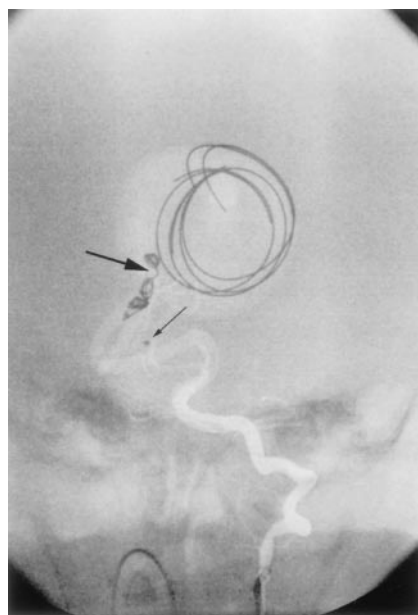


FIG 4. Anteroposterior projection of the fluoroscopy fade image generated from the digital subtraction angiogram shown in Figure 1. The microcatheter has been retracted (*small arrow* on proximal marker), with deployment of a coil partially within the venous pouch and partially within the feeding artery "bridging" the fistulous communication (*large arrow*).

Several advantages were afforded to us during the embolization procedure. The Siemens Neurostar Plus T.O.P. angiography unit permitted usage of the fluoroscopy fade feature and thus eliminated the need for road mapping during the case. This feature is particularly useful when working over the head, where there is essentially no perceivable vascular pulsation or respiratory motion. The variable pulse fluoroscopy settings enabled three frames per seconds of fluoroscopy without deterioration of image quality. Com-

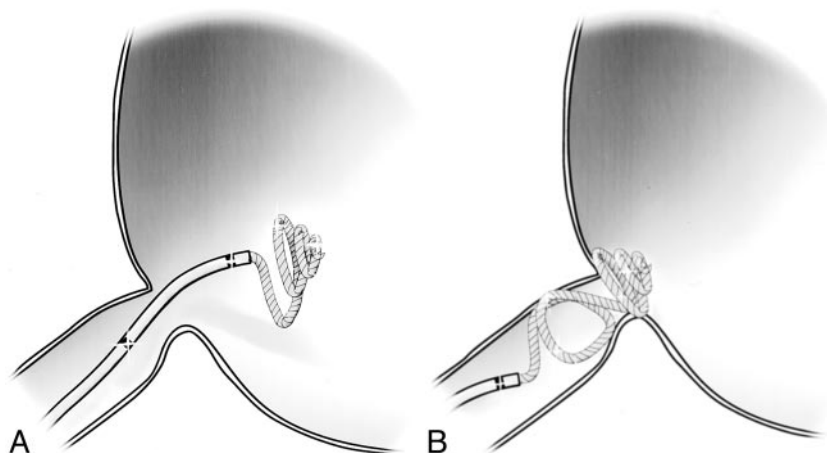


FIG 5. Illustrations of bridging technique used for coil embolization of the fistulous communication.

A, Several loops of coil were initially introduced into the venous pouch.

B, Microcatheter was then withdrawn into the arterial side of the fistula for deployment of the remaining coil.

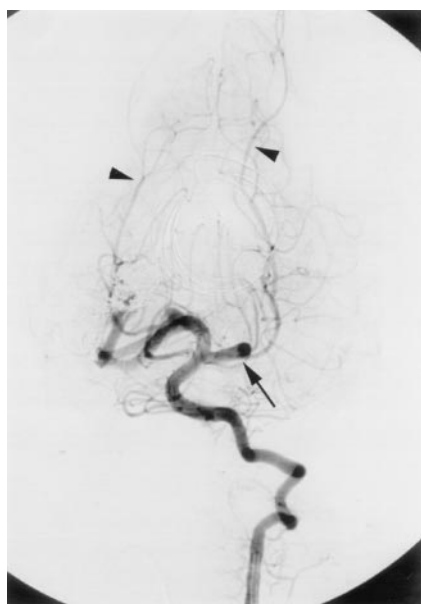

FIG 6. Anteroposterior projection left vertebral catheter injection digital subtraction angiogram shows obliteration of the vein of Galen malformation. Restoration of normal antegrade flow from the basilar artery to the distal posterior cerebral arterial territories has been achieved (arrowheads). Note the hypertrophied left P1 segment of the posterior cerebral artery and left posterior communicating artery (arrow), resulting from the previous hemodynamic alteration and vascular steal induced by the malformation (see Fig 1).

pared with our past experiences, the fluoroscopy fade image pulsed at three frames per seconds was of higher quality than a fresh roadmap image obtained at the same rate and it offered a substantial reduction in radiation compared with road mapping at seven or 15 frames per seconds (1). The estimated entrance skin dose of 480 mGy administered in our case was lower than the established adult deterministic thresholds for erythema and epilation, and the patient suffered no obvious adverse effects during several months of follow-up. More complex vein of Galen malformations often require several embolization procedures spread out over a period of a few weeks, during which time the patient's exposure could easily

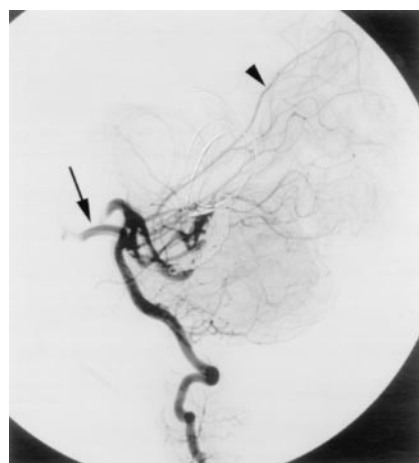


FIG 7. As in Figure 6, except lateral projection.

rise to levels well above the adult deterministic threshold.

Dosage of contrast material can quickly become an issue during pediatric embolization. Typically, one is restricted to 5 mL of 300 mgI/mL nonionic contrast material per kilogram of body weight (6). For these reasons, we were limited to using approximately 25 mL of contrast material during the procedure. The fluoroscopy fade technique eliminated the need for road mapping and thus limited the number of injections of contrast material required, permitting the entire procedure to be performed with only 24 mL of contrast material spread out over a period of several hours.

Conclusion

The technical innovations and design of modern fluoroscopy biplane units can have a pivotal influence on the feasibility and safety of difficult neurointerventional procedures. With reference to levels of radiation exposure and contrast use, the margin of safety in neonatal patients is very narrow. In this particular patient, the fluoroscopy fade function of our machine made a substantial contribution to the safe completion of the treatment.

References

1. Mahesh M. **Fluoroscopy: patient radiation exposure issues.** *Radio-graphics* 2001;21:1033–1045
2. Norbash AM, Busick D, Marks MP. **Techniques for reducing interventional neuroradiologic skin dose: tube position rotation and supplemental beam filtration.** *AJNR Am J Neuroradiol* 1996;17:41–49
3. McParland BJ. **Entrance skin dose estimates derived from dose-area product measurements in interventional radiological procedures.** *Br J Radiol* 1998;71:1288–1295
4. Huda W, Peters KR. **Radiation-induced temporary epilation after a neuroradiologically guided embolization procedure.** *Radiology* 1994;193:642–644
5. Gkanatsios NA, Huda W, Peters KR, Freeman JA. **Evaluation of an on-line patient exposure meter in neuroradiology.** *Radiology* 1997;203:837–842
6. Morris PP. *Practical Neuroangiography.* Philadelphia: Lippincott Williams & Wilkins; 1997:10