



Providing Choice & Value
Generic CT and MRI Contrast Agents



CONTACT REP

AJNR

Assessing Tissue Viability with MR Diffusion and Perfusion Imaging

Pamela W. Schaefer, Yelda Ozsunar, Julian He, Leena M. Hamberg, George J. Hunter, A. Gregory Sorensen, Walter J. Koroshetz and R. Gilberto Gonzalez

This information is current as of July 23, 2025.

AJNR Am J Neuroradiol 2003, 24 (3) 436-443
<http://www.ajnr.org/content/24/3/436>

Assessing Tissue Viability with MR Diffusion and Perfusion Imaging

Pamela W. Schaefer, Yelda Ozsunar, Julian He, Leena M. Hamberg, George J. Hunter, A. Gregory Sorensen, Walter J. Koroshetz, and R. Gilberto Gonzalez

BACKGROUND AND PURPOSE: Diffusion- (DW) and perfusion-weighted (PW) MR imaging reflect neurophysiologic changes during stroke evolution. We sought to determine parameters that distinguish regions of brain destined for infarction from those that will survive despite hypoperfusion.

METHODS: DW and PW images were obtained in 30 patients at 1–12 hours after symptom onset. Relative cerebral blood volume (rCBV), flow (rCBF), mean transit time (MTT), apparent diffusion coefficient (ADC), DW image signal intensity, and fractional anisotropy (FA) lesion-contralateral normal region ratios were obtained in the following regions: 1) infarct core with hyperintensity on DW image, abnormality on rCBF and MTT images, and follow-up abnormality; 2) infarcted penumbra with normal DW image, abnormal rCBF and MTT images, and follow-up abnormality; and 3) hypoperfused tissue that remained viable, with normal DW image, abnormal rCBF and MTT images, and normal follow-up.

RESULTS: rCBF ratios for regions 1, 2, and 3 were 0.32 ± 0.11 , 0.46 ± 0.13 , and 0.58 ± 0.12 , respectively, and were significantly different. DW image intensity and ADC ratios were significantly different among all regions, but were more similar than rCBF ratios. rCBV and FA ratios were not significantly different between regions 2 and 3. No MTT ratios were significantly different. No region of interest with an rCBF ratio less than 0.36, an rCBV ratio less than 0.53, an ADC ratio less than 0.85, a DW image intensity ratio greater than 1.23, or an FA ratio greater than 1.10 remained viable. No region of interest with an rCBF ratio greater than 0.79 infarcted.

CONCLUSIONS: Differences among mean ratios of three regions investigated were greatest for the rCBF ratio. The rCBF ratio may be the most useful parameter in differentiating viable tissue that is likely to infarct without intervention, from tissue that will survive despite hypoperfusion. ADC, DW intensity, FA, and rCBV ratios may provide adjunctive information.

New thrombolytic and neuroprotective therapies are being developed to treat acute ischemic infarction. Although these therapies may salvage ischemic but viable tissue, they are associated with risks such as intracranial hemorrhage. To use these therapies appropriately, it is important to distinguish between ischemic tissue that is likely to infarct without inter-

vention and tissue that is ischemic but will survive despite hypoperfusion.

Relatively new MR imaging techniques are improving our ability to evaluate acute stroke. Echo-planar diffusion-weighted (DW) imaging measures the restriction of water movement associated with cytotoxic edema and is sensitive to ischemia within minutes after onset. The lesion depicted on a DW image is associated with a decrease in Na^+K^+ -ATPase activity and energy failure and in most cases, in the absence of thrombolysis, is thought to represent the irreversible ischemic core (1–5).

Echo-planar perfusion-weighted (PW) imaging can demonstrate the altered physiologic state of the cerebral vasculature immediately after an occlusive or partially occlusive event. This physiologic state may be characterized by parameters of tissue perfusion such as relative cerebral blood volume (rCBV), relative cerebral blood flow (rCBF), and mean transit time (MTT) (5–9).

Received March 26, 2002; accepted after revision September 4. From the Departments of Radiology (P.W.S., Y.O., J.H., L.H., G.H., A.G.S., R.G.G.) and Neurology (W.K.), Massachusetts General Hospital, Harvard Medical School, Boston, MA.

W.K., Y.O., A.G.S. supported in part by NIH grant PHS R01NS8477

Presented in part at the annual meeting of the American Society of Neuroradiology, Boston, MA, April 2001, and the annual meeting of the Radiological Society of North America, Chicago, IL, 2001.

Address reprint requests to Pamela W. Schaefer, MD, Department of Radiology, Division of Neuroradiology, Gray B285, Massachusetts General Hospital, Fruit Street, Boston, MA 02114.

© American Society of Neuroradiology

With early stroke, there is frequently a region characterized by normal diffusion but abnormal perfusion that is thought to represent the operational ischemic penumbra (4, 10–13). Acute infarctions may grow into part, but not all, of the penumbra defined by PW MR imaging. The penumbra may be characterized by tissue that is destined to infarct without intervention and tissue that is hypoperfused but that will survive without intervention. Because new thrombolytic and neuroprotective therapies may salvage tissue characterized by reversible ischemia, but are associated with potential risks, it is important to characterize these two regions defined by PW MR imaging.

The purpose of this study was to distinguish between penumbral tissue that will or will not infarct in patients treated with conventional therapies, such as variable amounts of heparin, aspirin, and blood pressure management, without intervention with thrombolytic agents. We assessed differences in rCBF, rCBV, MTT, apparent diffusion coefficient (ADC), DW image signal intensity, and fractional anisotropy (FA) in three regions defined with DW and PW imaging: 1) infarct core, 2) ischemic penumbra that progressed to infarction, and 3) ischemic penumbra that did not progress to infarction.

Methods

Patient Selection

All patients who presented to the emergency department with signs and symptoms of acute stroke between January 1995 and December 2000 were reviewed. Inclusion criteria were as follows: imaging within 12 hours of stroke onset; availability of conventional MR images and DW and PW image data sets; abnormalities on rCBF and MTT images at least 20% larger than the DW image abnormality; proximal vessel occlusion documented with MR or CT angiography; availability of follow-up cross-sectional images (either CT or MR images); demonstration of an infarction on follow-up images; and triage to conventional treatments only.

During this time period, approximately 1600 patients presented to our hospital with acute stroke symptoms. Approximately 100 underwent DW and PW imaging, as well as follow-up imaging. Of these, 30 were imaged within 12 hours, had proximal occlusions with rCBF and MTT abnormalities at least 20% larger than the DW abnormality, and underwent conventional treatments only.

Imaging

MR imaging was performed with a 1.5-T whole-body imager (Signa; GE Medical Systems, Milwaukee, WI) with an echo-planar retrofit (Advanced NMR Systems, Wilmington, MA) (15 patients) or with a 1.5-T Signa Echospeed imager (GE Medical Systems) (15 patients).

DW images were obtained by using single-shot, echo-planar imaging with sampling of the entire diffusion tensor. Six high-b-value images corresponding to diffusion measurements in different gradient directions were acquired, followed by a single low-b-value image. The high b value was 1000–1221 s/mm² and the low b value was 3 s/mm². Imaging parameters were 6000–7500/100–118 (TR/TE), a field of view (FOV) of 20 × 20 cm, image matrix of 128 × 128 pixels, section thickness of 5 mm with a 1-mm gap. Three signal averages were obtained to increase signal-to-noise ratio of the images. Isotropic DW images were generated off-line on a network workstation (Sparcstation 20; Sun Microsystems, Milpitas, CA). ADC maps and

FA maps were also generated. This methodology has been previously described in detail (4, 5).

PW images were acquired with a spin-echo echo-planar technique during the injection of 0.2 mmol per kilogram of body weight gadodiamide (Omniscan; Nycomed, Oslo, Norway) or gadopentetate dimeglumine (Magnevist; Berlex Laboratories, Wayne, NJ). Forty-six to 51 single-shot echo-planar images were obtained in each of 10 sections, in 83 seconds. Imaging parameters were 1500–1520/65–75 (TR/TE), FOV of 20 × 20 cm, image matrix of 128 × 128 pixels, section thickness of 5 mm with a 1-mm gap. Parametric maps of vascular physiologic function were synthesized by using an arterial input deconvolution paradigm. In brief, for each voxel, the time-intensity curve observed during the passage of contrast material is converted to a curve of change in 1/T2 (ΔR_2), a parameter related to the concentration of gadolinium present in the voxel. An arterial input function (AIF) was identified from the middle cerebral artery on the abnormal side. We have found that in patients without carotid artery stenosis, images generated by deconvolution methods do not differ significantly with AIFs chosen from the ipsilateral compared with the contralateral middle cerebral artery. However, in patients with carotid artery stenosis or occlusion, images generated by deconvolution with the AIF from the ipsilateral middle cerebral artery provide a better depiction of the final infarct compared with images generated by deconvolution with the AIF chosen from the contralateral side. Under this circumstance, images generated by deconvolution with the AIF chosen from the contralateral side cause greater overestimation of the final infarct size (14). Then, for each target voxel, a combination of numerical integration of its ΔR_2 -time curve and deconvolution between the arterial input and the ΔR_2 curve is performed. This yields parameters of rCBV, rCBF, and MTT. Details of the theory and methodology of the perfusion map calculations are described in detail elsewhere (4, 5, 15).

Fast spin-echo T2-weighted images were acquired with 4200/102 (TR/effective TE), FOV of 20 × 20 cm, acquisition matrix of 256 × 256 pixels, section thickness of 5 mm with a 1-mm gap, and one signal average.

CT of the head was performed by using a helical scanner (Advantage, GE Medical Systems, Waukesha, WI), with 5-mm contiguous axial sections, 140 kVp, 340 mAs, 1-second scanning time.

Image Analysis

The DW images, calculated ADC maps, FA maps, perfusion (rCBV, rCBF, MTT) maps, and follow-up T2-weighted or CT images were transferred to a personal computer for analysis. Abnormalities on DW and PW images were outlined by using a commercially available image analysis program (ALICE; Hayden Image Processing Solutions, Denver, CO). Two research radiologists (J.H., Y.O.) drew outlines with a segmentation tool that suggests contours on the basis of local image intensity gradients. The contours were edited by an experienced neuroradiologist (P.W.S.).

For each case, outlines of the MTT abnormality were copied onto the coregistered rCBF images. Outlines of the DW image and final infarct were placed manually, by visual inspection, on the unaligned rCBF images. Then, we defined three regions, as shown in Fig 1: region 1, “infarct core” covering the area that had hyperintensity on the DW image, rCBF and MTT abnormality, and hyperintensity or hypoattenuation on follow-up T2-weighted or CT images, respectively; region 2, “penumbra that progressed to infarction” covering the area that had no abnormality on DW images, but that was abnormal on rCBF and MTT images and had hypoattenuation or hyperintensity on follow-up CT or MR images, respectively; region 3, “hypoperfused tissue that remained viable” covering the area that had rCBF and MTT abnormality but that was normal on DW images and was normal on follow-up CT or MR images. Re-

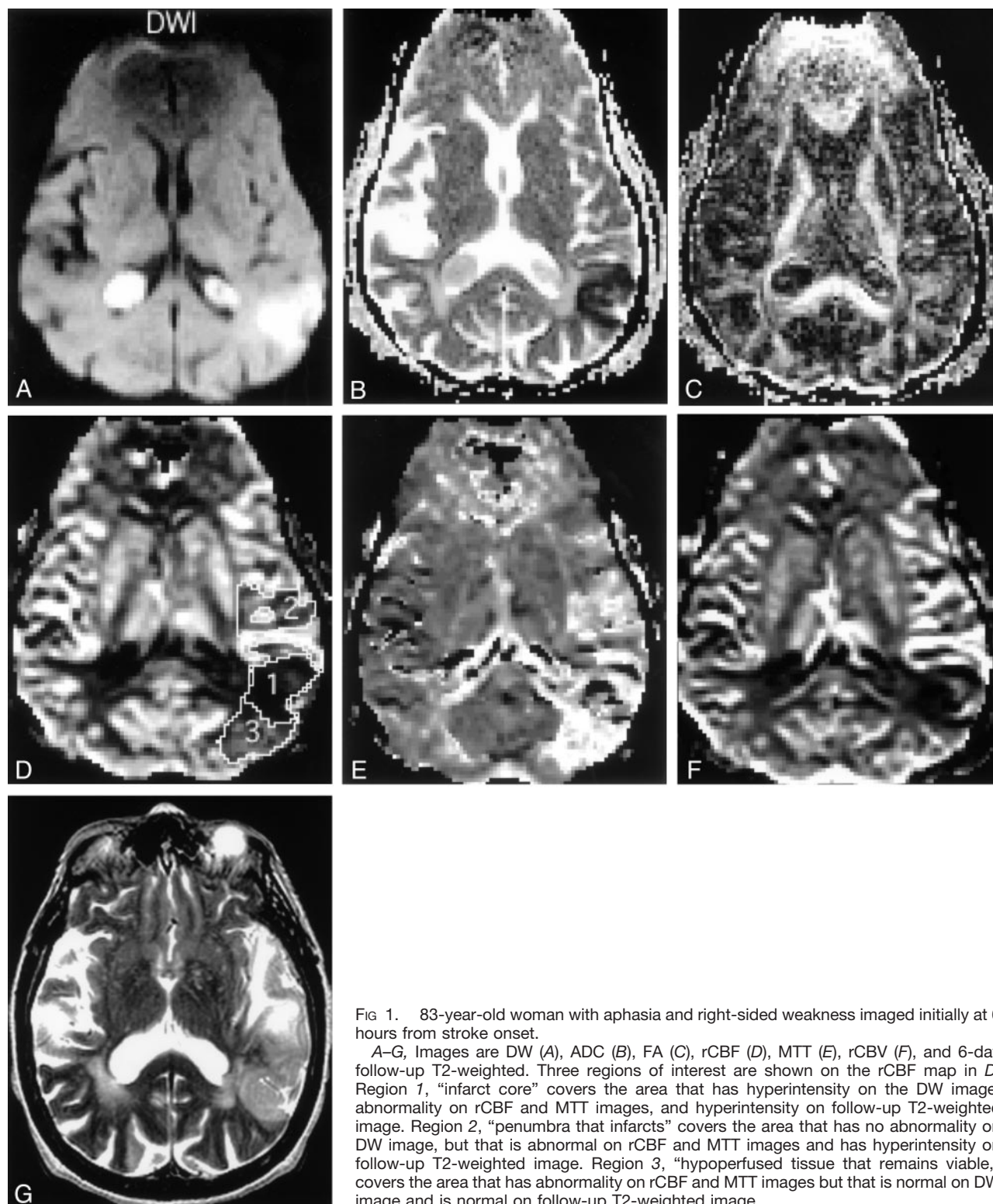


FIG 1. 83-year-old woman with aphasia and right-sided weakness imaged initially at 6 hours from stroke onset.

A–G, Images are DW (A), ADC (B), FA (C), rCBF (D), MTT (E), rCBV (F), and 6-day follow-up T2-weighted. Three regions of interest are shown on the rCBF map in D. Region 1, “infarct core” covers the area that has hyperintensity on the DW image, abnormality on rCBF and MTT images, and hyperintensity on follow-up T2-weighted image. Region 2, “penumbra that infarcts” covers the area that has no abnormality on DW image, but that is abnormal on rCBF and MTT images and has hyperintensity on follow-up T2-weighted image. Region 3, “hypoperfused tissue that remains viable,” covers the area that has abnormality on rCBF and MTT images but that is normal on DW image and is normal on follow-up T2-weighted image.

gions with normal diffusion, MTT, and rCBF but with hypoattenuation or hyperintensity on follow-up CT or MR images, respectively, were not evaluated.

Regions similar in size and shape to those for the core, penumbra that progressed to infarction, and hypoperfused tissue that remained viable were then obtained in normal contralateral brain on the rCBF images. The mean signal intensity value of each abnormal region was then divided by the mean

signal intensity value of the corresponding contralateral normal region to obtain rCBF ratios for each patient. These regions were then transferred onto the rCBV, MTT, ADC, DW, and FA images. rCBV, MTT, ADC, and DW image signal intensity ratios were similarly obtained for each evaluable region in each patient. FA images were not obtained in the first 15 patients. In the final 15 patients, FA values were similarly obtained for each evaluable region in each patient.

Perfusion and diffusion MR parameter ratios for infarct core (region 1), penumbra that infarcts (region 2), and hypoperfused tissue that recovers (region 3)

Parameter	Region 1	Region 2	Region 3	P Value*
Perfusion				
rCBF	0.32 ± 0.11 (0.16–0.61)	0.46 ± 0.13 (0.24–0.79)	0.58 ± 0.12 (0.36–0.84)	<.001
rCBV	0.56 ± 0.21 (0.16–0.88)	0.80 ± 0.25 (0.43–1.44)	0.91 ± 0.18 (0.53–1.21)	.056
MTT	1.70 ± 0.42 (0.93–2.70)	1.74 ± 0.42 (0.89–2.62)	1.65 ± 0.43 (0.65–2.70)	.484
Diffusion				
ADC	0.63 ± 0.12 (0.45–0.93)	0.90 ± 0.11 (0.69–1.12)	0.96 ± 0.05 (0.85–1.06)	.018
DWI	1.84 ± 0.41 (1.07–2.71)	1.13 ± 0.08 (1.02–1.34)	1.08 ± 0.07 (0.95–1.22)	.014
FA	1.13 ± 0.20 (0.83–1.64)	1.02 ± 0.10 (0.84–1.18)	1.02 ± 0.06 (0.92–1.10)	.862

Note.—DWI indicates DW image signal intensity. Data are mean ratios ± SD.

Numbers in parentheses are the range.

* P values are for the comparison between region 2 and region 3.

Statistical Analysis

Two-tailed *t* tests were performed to compare mean patient lesion ratios between region 1 and region 2, between region 1 and region 3, and between region 2 and region 3 for all diffusion and perfusion parameters. Differences were considered statistically significant at *P* less than .05.

Results

Thirty patients were eligible for entry into this study. There were 17 men and 13 women aged 34–95 years (mean age, 66 years). Time from stroke onset to imaging ranged from 1 to 12 hours (mean, 5.7 hours). Time from initial imaging to follow-up imaging was 1–17 days (mean, 5.7 days). Patients were treated as follows. For anticoagulation therapy, 21 patients received intravenous heparin alone, two received aspirin alone, two received intravenous heparin combined with aspirin, and one received subcutaneous heparin combined with aspirin. Because of the risk of hemorrhage, four did not receive anticoagulation therapy. Nineteen patients received hypertensive therapy. Three patients with severe swelling received mannitol. One patient underwent carotid endarterectomy. No other revascularization procedures were performed. No patients underwent craniectomy.

Lesion-contralateral normal region ratios for regions 1–3 determined for the three PW and three DW imaging maps are presented in Table 1. Graphs of rCBF, rCBV, MTT, ADC, DW image signal intensity, and FA mean lesion ratios for each patient are presented in Figure 2, respectively. Regions 1 and 3 could be defined in all 30 patients. Region 2 was present in 23 patients. For FA analysis, regions 1 and 3 could be defined in 15 patients, and region 2 was defined in 10 patients.

The mean of all the patients' rCBF ratios for infarct core (region 1) was 0.32, for penumbra that infarcted (region 2) was 0.46, and for hypoperfused tissue that

remained viable (region 3) was 0.58. Each of the regions was significantly different (*P* < .001). The highest mean rCBF ratio in regions 1 and 2 was 0.79. The lowest mean rCBF ratio in region 3 was 0.36.

The mean of all the patients' rCBV ratios for infarct core (region 1) was 0.56, for penumbra that infarcted (region 2) was 0.80, and for hypoperfused tissue that remained viable (region 3) was 0.91. Mean ratios were significantly lower for region 1 compared with both regions 2 and 3 (*P* < .001). Mean ratios for regions 2 and 3 were not significantly different (*P* = .056). The lowest mean rCBV ratio in region 3 was 0.53. Ratios greater than 1.0 were noted in both penumbral regions (regions 2 and 3): region 2 had a mean rCBV ratio greater than 1 in four (17%) of 23 patients, and region 3 had a mean rCBV ratio greater than 1 in 12 patients (40%). Neither stroke onset time nor rCBF value was significantly different in the regions with a mean rCBV ratio greater than 1.0 compared with regions with a mean rCBV ratio less than 1.0 (*P* > .05).

The mean of all the patients' MTT ratios for infarct core (region 1) was 1.70, for penumbra that infarcted (region 2) was 1.74, and for hypoperfused tissue that remained viable (region 3) was 1.65. None of the regions were significantly different (*P* > .05).

The mean of all the patients' ADC ratios for infarct core (region 1) was 0.63, for penumbra that infarcted (region 2) was 0.90, and for hypoperfused tissue that remained viable (region 3) was 0.96. Mean ADC ratios for all three regions were significantly different. The *P* values for region 1 versus region 3 and for region 1 versus region 2 were both less than .001, whereas the *P* value for region 2 versus region 3 was equal to .018. The lowest mean ADC value seen in region 3 was 0.85.

The mean of all the patients' DW image signal intensity ratios for infarct core (region 1) was 1.84, for penumbra that infarcted (region 2) was 1.13, and for penumbra that remained viable (region 3) was 1.08 ± 0.07. The respective 13% and 8% elevations of DW image intensity seen in the two penumbral regions were below the level of detection of the radiologists drawing the contours around the infarct core. Mean DW intensity ratios for all three regions were significantly different from each other. The *P* values for region 1 versus region 3 and for region 1 versus region 2 were both less than .001, whereas the *P* value for region 2 versus region 3 was equal to .014. The highest mean DW intensity ratio in region 3 was 1.23.

The mean of all the patients' (*n* = 15) FA ratios for infarct core (region 1) was 1.13, for penumbra that infarcted (region 2) was 1.02, and for penumbra that remained viable (region 3) was 1.02. The mean ratio was significantly higher for region 1 compared with those of both regions 2 and 3 (*P* < .001 for region 1 vs region 3, *P* < .02 for region 1 vs region 2). Mean ratios for regions 2 and 3 were not significantly different (*P* = .862). No region of interest with a mean ratio greater 1.10 was normal on follow-up images.

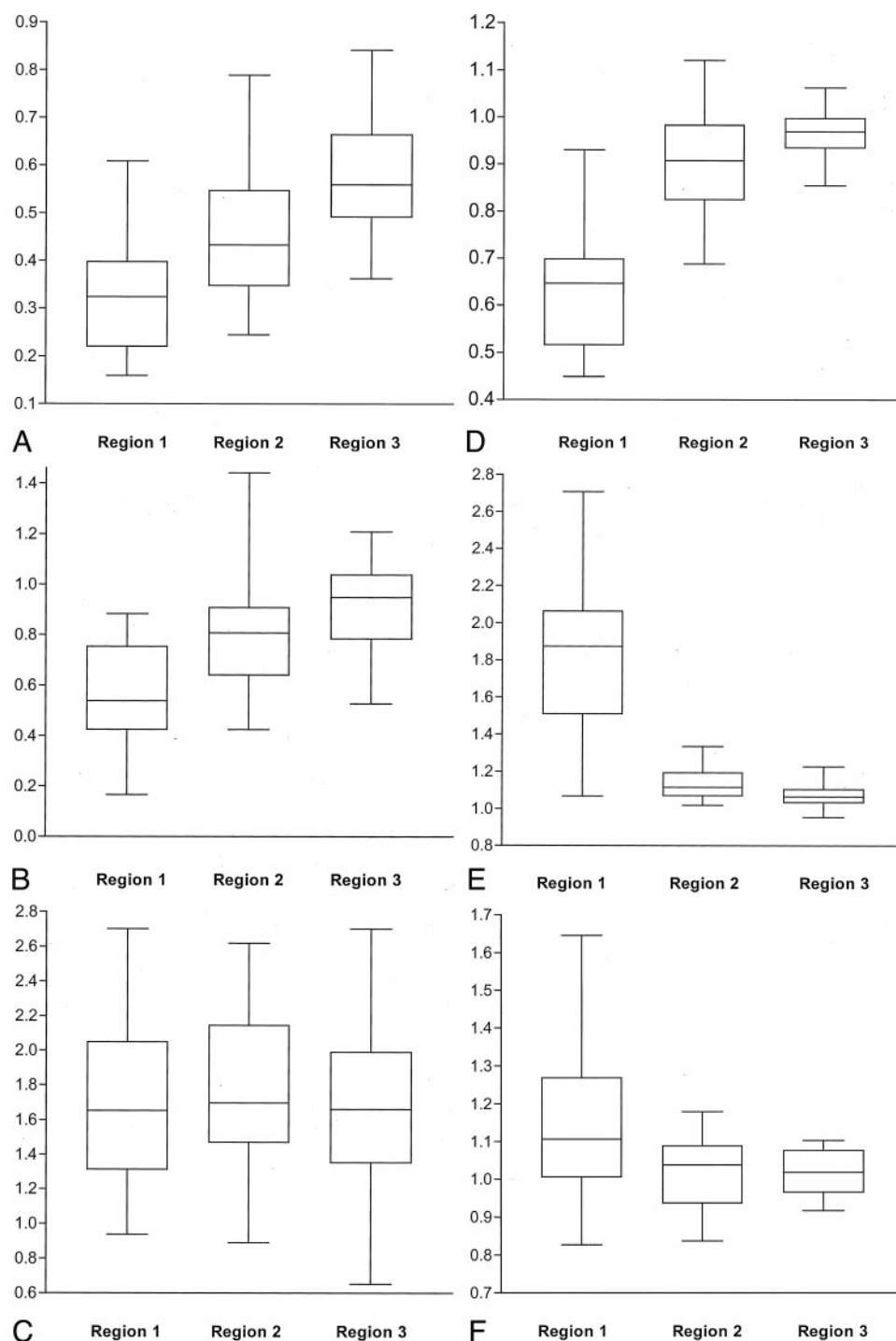


FIG 2. Box and whisker plots of mean values of lesion-contralateral normal region ratios in all patients. The line through the center of each box represents the median value. The box ends represent the 1st and 3rd quartiles. The end points of each graph represent the smallest and largest values.

- A, rCBF ratios.
- B, rCBV ratios.
- C, MTT ratios.
- D, ADC ratios.
- E, DW image signal intensity ratios.
- F, FA ratios.

Discussion

We found that rCBF was the most useful parameter in distinguishing hypoperfused tissue that progressed to infarction from hypoperfused tissue that remained viable in the operationally defined ischemic penumbra in patients not treated with thrombolysis. No penumbral region of interest with a mean rCBF less than 0.36 was normal at follow-up, and no penumbral tissue with a mean rCBF greater than 0.79 was abnormal at follow-up. Although the mean rCBV, DW image intensity, ADC, and FA ratios for hypoperfused tissue that progressed to infarction and hypoperfused tissue that remained viable have more overlap, they provide adjunctive information. No measured penumbral tissue with a mean rCBV ratio less than 0.53, a mean DW image intensity ratio greater than 1.23, a mean ADC ratio less than 0.85, or a mean FA ratio greater than 1.10 was normal on follow-up images.

Our results for rCBF ratios of 0.32 for core, 0.46 for operational penumbra that infarcted, and 0.58 for operational penumbra that remained viable are in agreement with results of prior human MR studies. In studies with similar designs and smaller patient numbers or later time points, reported rCBF ratios for core were 0.12–0.26, for penumbra that infarcted were 0.35–0.42, and for hypoperfused tissue that remained viable were 0.62–0.66 (13, 16, 17). Grandin et al (18), using the MTT abnormality alone to define the penumbra, reported higher rCBF ratios of 0.44, 0.56, and 0.78 for core, penumbra that infarcted, and hypoperfused tissue that recovered, respectively.

Our data compare well with the results of a number of single photon emission CT (SPECT) hemodynamic studies in humans that have addressed CBF rates in infarct core and penumbral tissue. Liu et al (17) demonstrated rCBF ratios of 0.27, 0.69, and 0.87 for infarct core, region of infarct growth, and hypoperfused tissue that recovered, respectively. Hatazawa et al (19) and Shimosegawa et al (20), in studies of patients imaged within 6 hours, demonstrated rCBF ratios of 0.39 and 0.48, respectively, for all tissue that progressed to infarction and 0.69 and 0.75, respectively, for tissue with an initial SPECT abnormality that remained viable. The rCBF values obtained from SPECT imaging may be higher in the penumbral regions compared with those values obtained with other modalities because as Liu et al suggested, it has been demonstrated that technetium-99m ethyl cysteinate dimer has moderate cerebral extraction rates in cortex with high flow rates (contralateral normal brain) and high cerebral extraction rates with low flow rates (ischemic tissue).

Furthermore, our MR data are in agreement with results of positron emission tomography (PET) hemodynamic studies in humans. The normal average CBF in human parenchyma varies depending on age and location in gray matter versus white matter. Reported mean normal values for gray and white matter are 26.4–50 mL/100 g/min (21, 22). Considering these values, our ratios translate to 8.5–16.2 mL/100 g/min

for core, 11.9–22.5 mL/100 g/min for penumbra that progressed to infarction, and 15.2–28.8 mL/100 g/min for hypoperfused tissue that remained viable. Powers et al (23) demonstrated a minimum CBF of 15 mL/100 g/min for viable tissue and a minimum CBF of 19 mL/100 g/min for functioning tissue in humans. Marchal et al (22) demonstrated that tissue with a cerebral metabolic rate of oxygen greater than 1.4 mL/100 g/min that infarcted, had a CBF range of 10 to 27 mL/100 g/min. Furlan et al (24) demonstrated mean CBF values of 6.92 mL/100 g/min for tissue with high oxygen extraction fraction (OEF) that was irreversibly damaged, 11.4 mL/100 g/min for tissue with high OEF that progressed to infarction (infarcted penumbra) but that had overlap values with tissue characterized by high OEF that did not progress to infarction (non-infarcted penumbra), and 18.11 mL/100 g/min for oligemic tissue with high OEF that had no overlap with infarcted penumbra values and recovered.

The variability in CBF ratios likely results from a number of different factors. Most important, the data obtained represents only a single time point in a dynamic process. One major factor is variability in timing of tissue reperfusion. Jones et al (25) demonstrated in monkeys that both severity and duration of CBF reduction up to 4 hours define an infarction threshold. The threshold for tissue infarction with reperfusion at 2–3 hours was 10–12 mL/100 g/min, whereas the threshold for tissue infarction with permanent occlusion was 17–18 mL/100 g/min. Ueda et al (26), in a study of patients treated with thrombolysis, demonstrated that duration of ischemia affected the threshold for tissue viability for up to 5 hours. Another factor is that normal average CBF in human parenchyma varies greatly, depending on age and location in gray matter versus white matter (10, 21, 22, 24, 27). Other factors include variability in methodologies, variability in initial and follow-up imaging times, and variability in postischemic tissue responses.

We found that rCBV was much less useful in distinguishing between the two regions of the operational ischemic penumbra as compared with rCBF. Low mean rCBV, however, did correspond with infarction on follow-up images (no region of interest with a mean rCBV ratio less than 0.53 was normal on follow-up images), and our mean rCBV ratios did rise in a step-wise manner (0.56, 0.80, and 0.91 for core, infarcted penumbra, and hypoperfused tissue that remained viable, respectively). However, the mean rCBV ratios for penumbra that progressed to infarction and hypoperfused tissue that remained viable were not statistically significantly different. Furthermore, we were unable to determine whether elevated rCBV was indicative of penumbral tissue infarction or tissue viability. Both regions 2 and 3 included individual mean rCBV ratios of greater than 1.0. In fact, the highest individual mean rCBV ratio in region 2 was higher than all mean rCBV ratios in region 3. Reported ratios for the three regions are highly variable and range from 0.25 to 0.89 for core, 0.69 to 1.44 for penumbra that progresses to infarction, and 0.94 to

1.29 for hypoperfused tissue that remains viable (13, 16–19).

The occasional finding of elevated rCBV in the ischemic penumbra is in accordance with PET studies demonstrating that in the early stages of ischemia, decreased cerebral perfusion pressure produces vasodilatation and an increase in the CBV that maintains constant CBF and OEF (28). With further decreases in cerebral perfusion pressure, the compensatory vasodilatation reaches a maximum and CBF begins to fall. As the CBF falls, the CBV initially continues to rise but then falls as capillary beds collapse and the OEF reaches its maximum. Further declines in CBF and CBV result in disruption of energy metabolism, and ischemic injury occurs. As $rCBV = rCBF \times MTT$, elevated rCBV ratios can be observed over a relatively wide range of CBF values if met by a rise in MTT. The fact that regions with elevated rCBV may go on to infarction combined with the fact that abnormal regions on DW images usually have depressed rCBV suggests that the stage of normal or elevated rCBV is not necessarily sustainable over time and may represent a very unstable situation.

Although MTT ratios were elevated in all three regions, we were unable to demonstrate statistically significant differences in the MTT values among any of the three regions and considered this variable the least useful in differentiating regions that infarcted from regions that were normal at follow-up. This finding is in agreement with results of a number of previous reports (13, 17). However, Grandin et al (18) found that hypoperfused tissue that recovered did have an MTT that was significantly lower than that of penumbra that progressed to infarction and that of infarct core. Rohl et al (16) also reported significantly different MTT values among all three regions, with more prolonged MTT being associated with more severe ischemia. The authors suggested that this correlated with the fact that MTT is inversely related to perfusion pressure.

Our ADC ratios of 0.63, 0.90, and 0.96 are similar to previously reported values of 0.56–0.80 for core, 0.89–0.94 for penumbra that infarcts, and 0.93–0.99 for hypoperfused tissue that remains viable (13, 16, 29). Although mean ADC ratios for regions 2 and 3 were significantly different, there was greater overlap between values compared with rCBF ratios. However, no region of interest with a mean ADC ratio of less than 0.85 was normal on follow-up images. This value is similar to threshold values reported in animal experiments. Hoehn-Berlage et al (30) and Olah et al (31) both demonstrated a threshold ADC ratio of 0.77 for energy failure in rats subject to middle cerebral artery occlusion. Hoehn-Berlage et al, in a separate experiment (32), demonstrated good agreement between tissue with an initial ADC ratio of less than 0.80 and histologic infarction.

Our mean DW image signal intensity ratio for infarct core (1.84) was similar to the ratio of 1.9 reported at 1 day by Lansberg et al (33). Mean DW image intensity ratios in both regions 2 (1.13) and 3 (1.08) were similar, and although they were statisti-

cally significantly different, there was greater overlap between values compared with rCBF ratios. However, no region of interest with a DW image intensity ratio greater than 1.23 remained viable. This value may be close to a DW image intensity threshold ratio for tissue viability. Minematsu et al (34), in a rat model of cerebral ischemia, reported a DW image intensity ratio of 1.186 in tissue that initially had an abnormality on DW images after transient middle cerebral artery occlusion for 1 hour but did not progress to infarction. The DW image intensity ratio was 1.397 in tissue that did progress to infarction.

Mean FA ratios were not significantly different from unity in either penumbral region. However, no tissue with a mean FA ratio of greater than 1.10 was normal on follow-up images. In the setting of acute stroke, FA corresponds with time of stroke onset. In general, FA is elevated in the hyperacute and early acute stages, progressively decreases over time, and becomes reduced at 12–24 hours (35, 36). Elevated FA in the hyperacute stage is thought to represent shift of water from the extracellular space to the intracellular space, with cell membranes remaining intact. The degree of FA elevation may be important in differentiating tissue destined to infarct from tissue that may remain viable.

The limitations of our study relate to the observational study design. Although our patients received conventional treatments only, there was heterogeneity in their treatment regimens. For example, they received variable amounts of heparin, aspirin, and blood pressure management. Routine clinical management including decisions on timing of imaging studies was not altered for the purposes of this investigation. Thus, time of initial and follow-up imaging was variable, and follow-up imaging was with CT or MR imaging. Edema enlarging the volume of the infarct may also make it difficult to know whether stroke injury has spread into previously normal tissue or simply compressed and distorted it. Furthermore, the initial abnormality on DW images may overestimate the ischemic core. Kidwell et al (37) demonstrated that the final infarct may be smaller than the initial DW imaging abnormality in patients treated with thrombolysis. Finally, we compared heterogeneous regions of tissue rather than voxels of tissue. It is unclear how accurate our ratios will be to predict tissue viability in smaller tissue samples.

Conclusion

Of all perfusion and diffusion parameters evaluated, rCBF demonstrated the most difference between penumbral tissue that progressed to infarction and hypoperfused tissue that remained viable in the absence of thrombolysis. No penumbral region of interest with a mean rCBF less than 0.36 was normal at follow-up and no penumbral tissue with a mean rCBF greater than 0.79 was abnormal at follow-up. Although the mean rCBV, DW image intensity, ADC, and FA ratios for penumbra that progressed to infarction and hypoperfused tissue that remained vi-

able have more overlap, they provide adjunctive information. No penumbral region of interest with a mean rCBV ratio less than 0.53, an ADC ratio less than 0.85, a DW image intensity ratio greater than 1.23, or a FA ratio greater than 1.10 was normal at follow-up. This information may be useful in identifying tissue that may be salvaged but is likely to infarct without intervention and may be useful in the selection of patients for thrombolytic or neuroprotective therapy.

Acknowledgments

The authors would like to thank the following people who are integral members of the team caring for patients with acute stroke at our hospital: Lee Schwamm, Ferdinand Buonanno, Colin McDonald, Guy Rordoff, David Greer, Jonathan Rosand, Igor Ougurets, Kim En Lee, and Joannie O'Donnell.

References

- Kucharczyk J, Mintorovich J, Asgari H, Moseley M. Diffusion/perfusion MR imaging of acute cerebral ischemia. *Magn Reson Med* 1991;19:311–315
- Moseley M, Kucharczyk J, Mintorovich J, et al. Diffusion-weighted MR imaging of acute stroke: correlation with T2-weighted and magnetic susceptibility-enhanced MR imaging in cats. *AJNR Am J Neuroradiol* 1990;11:423–429
- Mintorovich J, Yang GY, Shimizu H, Kucharczyk J, Chan PH, Weinstein PR. Diffusion-weighted magnetic resonance imaging of acute focal cerebral ischemia: comparison of signal intensity with changes in brain water and Na^+ , K^+ -ATPase activity. *J Cereb Blood Flow Metab* 1994;14:332–336
- Sorensen AG, Buonanno FS, Gonzalez RG, et al. Hyperacute stroke: evaluation with combined multisection diffusion-weighted and hemodynamically weighted echo-planar MR imaging. *Radiology* 1996;199:391–401
- Sorensen A, Copen W, Ostergaard L, et al. Hyperacute stroke: simultaneous measurement of relative cerebral blood volume, relative cerebral blood flow, and mean tissue transit time. *Radiology* 1999;210:519–527
- Belliveau J, Rosen B, Kantor H. Functional cerebral imaging by susceptibility contrast NMR. *Magn Reson Med* 1990;14:538–546
- Ostergaard L, Sorensen AG, Kwong KK, Weisskoff RM, Gyldensted C, Rosen BR. High resolution measurement of cerebral blood flow using intravascular tracer bolus passages, II: experimental comparison and preliminary results. *Magn Reson Med* 1996;36:726–736
- Rosen BR, Belliveau JW, Aronen HJ, et al. Susceptibility contrast imaging of cerebral blood volume: human experience. *Magn Reson Med* 1991;22:293–299
- Rempp K, Brix G, Wenz F, Becker C, Guckel F, Lorenz W. Quantification of region cerebral blood flow and volume with dynamic susceptibility contrast-enhanced MR imaging. *Radiology* 1994;193:637–641
- Barber P, Darby D, Desmond P, et al. Prediction of stroke outcome with echoplanar perfusion- and diffusion-weighted MRI. *Neurology* 1998;51:418–456
- Neuman-Haefelin T, Wittsack HJ, Wenserski F, et al. Diffusion- and perfusion-weighted MRI: the DWI/PWI mismatch region in acute stroke. *Stroke* 1999;30:1591–1597
- Karonen J, Liu Y, Vanninen R, et al. Combined perfusion- and diffusion-weighted MR imaging in acute ischemic stroke during the first week: a longitudinal study. *Radiology* 2000;217:668–694
- Schlaug G, Benfield A, Baird A, et al. The ischemic penumbra: operationally defined by diffusion and perfusion MRI. *Neurology* 1999;53:1528–1537
- Yamada K, Wu O, Gonzalez R, et al. Magnetic resonance perfusion-weighted imaging of acute cerebral infarction: effect of the calculation methods and underlying vasculopathy. *Stroke* 2002;33:87–94
- Rosen BR, Belliveau JW, Vevea JM, Brady TJ. Perfusion imaging with NMR contrast agents. *Magn Reson Med* 1990;14:249–265
- Rohr L, Ostergaard L, Simonsen C, et al. Viability thresholds of ischemic penumbra of hyperacute stroke defined by perfusion-weighted MRI and apparent diffusion coefficient. *Stroke* 2001;32:1140–1146
- Liu Y, Karonen J, Vanninen R, Ostergaard L, et al. Cerebral hemodynamics in human acute ischemic stroke: a study with diffusion- and perfusion-weighted magnetic resonance imaging and SPECT. *J Cereb Blood Flow Metab* 2000;20:910–920
- Grandin C, Duprez T, Smith A, et al. Usefulness of magnetic resonance derived quantitative measurements of cerebral blood flow and volume prediction of infarct growth in hyperacute stroke. *Stroke* 2001;32:1147–1153
- Hatazawa J, Shimosegawa E, Toyoshima H, et al. Cerebral blood volume in acute brain infarction: a combined study with dynamic susceptibility contrast MRI and $^{99\text{m}}\text{Tc}$ -HMPAO-SPECT. *Stroke* 1999;30:800–806
- Shimosegawa E, Hatazawa J, Inugami A, et al. Cerebral infarction within six hours of onset: prediction of completed infarction with technetium- $^{99\text{m}}$ -HMPAO SPECT. *J Nucl Med* 1994;36:2392–2394
- Lassen N. Normal average cerebral blood flow in younger adults is 50 ml/100 g/min. *J Cereb Blood Flow Metab* 1985;5:347–349
- Marchal G, Beaudouin V, Rioux P, et al. Prolonged persistence of substantial volumes of potentially viable brain tissue after stroke: a correlative PET-CT study with voxel-based data analysis. *Stroke* 1996;27:599–606
- Powers W, Grubb R, Darriet D, Raichle M. Cerebral blood flow and cerebral metabolic rate of oxygen requirements for cerebral function and viability in humans. *J Cereb Blood Flow Metab* 1985;5:600–608
- Furlan M, Marchal G, Viader F, Derlon J, Baron J. Spontaneous neurological recovery after stroke and the fate of the ischemic penumbra. *Ann Neurol* 1996;40:216–226
- Jones T, Morawetz R, Crowell R, et al. Thresholds of focal cerebral ischemia in awake monkeys. *J Neurosurg* 1981;54:773–782
- Ueda T, Sakaki S, Yuh W, Nochi I, Ohta S. Outcome in acute stroke with successful intra-arterial thrombolysis and predictive value of initial single-photon emission-computed tomography. *J Cereb Blood Flow Metab* 1999;19:99–108
- Frackowiak R, Lenzi G, Jones T, Heather J. Quantitative measurement of regional cerebral blood flow and oxygen metabolism in man using ^{15}O and positron emission tomography: theory, procedure and normal values. *J Comput Assist Tomogr* 1980;4:727–736
- Powers W. Cerebral hemodynamics in ischemic cerebrovascular disease. *Ann Neurol* 1991;29:231–240
- Oppenheim C, Grandin C, Samson Y, et al. Is there an apparent diffusion coefficient threshold in predicting tissue viability in hyperacute stroke? *Stroke* 2001;32:2486–2491
- Hoehn-Berlage M, Norris D, Kohno K, Mies G, Liebfritz D, Hossman K. Evolution of regional changes in apparent diffusion coefficient during focal ischemia of rat brain: the relationship of quantitative diffusion NMR imaging to reduction in cerebral blood flow and metabolic disturbances. *J Cereb Blood Flow Metab* 1995;15:1002–1011
- Olah L, Wecker S, Hoehn M. Relation of apparent diffusion coefficient changes and metabolic disturbances after one hour of focal cerebral ischemia and at different reperfusion rates in rats. *J Cereb Blood Flow Metab* 2001;21:430–439
- Hoehn-Berlage M, Eis M, Back T, Kohno K, Yamashita K. Changes of relaxation times (T_1 , T_2) and apparent diffusion coefficient after permanent middle cerebral artery occlusion in the rat: temporal evolution, regional extent and comparison with histology. *Magn Reson Med* 1995;34:824–834
- Lansberg M, Thijs V, O'Brien M, et al. Evolution of apparent diffusion coefficient, diffusion-weighted and T2-weighted signal intensity of acute stroke. *AJNR Am J Neuroradiol* 2001;22:637–644
- Minematsu K, Li L, Sotak C, Davis M, Fisher M. Reversible focal ischemic injury demonstrated by diffusion-weighted magnetic resonance imaging. *Stroke* 1992;23:1304–1310
- Zelaya F, Flood N, Chalk J, et al. An evaluation of the time dependence of the anisotropy of the water diffusion tensor in acute human ischemia. *Magn Reson Imaging* 1999;17:331–348
- Yang Q, Tress B, Barber P, et al. Serial study of apparent diffusion coefficient and anisotropy in patients with acute stroke. *Stroke* 1999;30:2382–2390
- Kidwell C, Saver J, Mattiello J, et al. Thrombolytic reversal of acute human cerebral ischemic injury shown by diffusion/perfusion magnetic resonance imaging. *Ann Neurol* 2000;47:462–469