



Providing Choice & Value
Generic CT and MRI Contrast Agents



CONTACT REP

AJNR

Absence of the Common Carotid Artery: A Rare Vascular Anomaly

Majid Maybody, Martin Uszynski, Evan Morton and Jiri J. Vitek

AJNR Am J Neuroradiol 2003, 24 (4) 711-713
<http://www.ajnr.org/content/24/4/711>

This information is current as
of July 16, 2025.

Absence of the Common Carotid Artery: A Rare Vascular Anomaly

Majid Maybody, Martin Uszynski, Evan Morton, and Jiri J. Vitek

Summary: Although absence of the common carotid artery (CCA) is a rare anomaly, the specific configuration in our case makes it extremely rare. Clinical, angiographic, ultrasonographic, and embryologic correlations of this anomaly are discussed after the case report.

Absence of the CCA is rare. Fewer than 25 cases have been reported in the literature, with only five angiographically proved cases. Only one case had ultrasonographic correlation (1). To the best of our knowledge, in all reported cases, the ECA originated proximal to the ICA, which makes our case an extremely rare occurrence (2–15). Absence of the CCA has no side or sex preferences (5), can occur bilaterally (5, 9), and is asymptomatic unless associated with other conditions. Among reported associations are cervical aortic arch, double aortic arch, right-sided aortic arch with aberrant left subclavian artery, and persistent trigeminal artery (5). Although in our case, the right ICA had no significant stenosis, symptomatic stenoses have been reported in association with this anomaly (11).

Case Report

Bilateral cerebral angiography was performed on a 72-year-old female patient with a medical history of hypertension, hypercholesterolemia, recent silent myocardial infarction, left hemispheric transient ischemic attacks, and a family history of stroke and coronary artery disease. The CCA was absent on the right side, but unlike the usual configuration of separate internal carotid artery (ICA) and external carotid artery (ECA), in our case, the right ICA originated proximal to the right ECA (Figs 1 and 2). No significant stenoses were found on the right side. Other findings were tortuosity of the right ICA at the level of C3–C4 (Fig 2) and hypoplasia of the A1 segment of the right anterior cerebral artery. High grade, short segment ostial stenosis of the ICA was found on the left side. The results of the examination were otherwise unremarkable. The patient then underwent stent placement of the stenotic left ICA. As part of post-stent placement workup, a bilateral carotid Doppler examination was performed, which showed satisfactory peak systolic velocities of the stented left ICA and normal pattern of spectral waveforms for the right ICA and ECA.

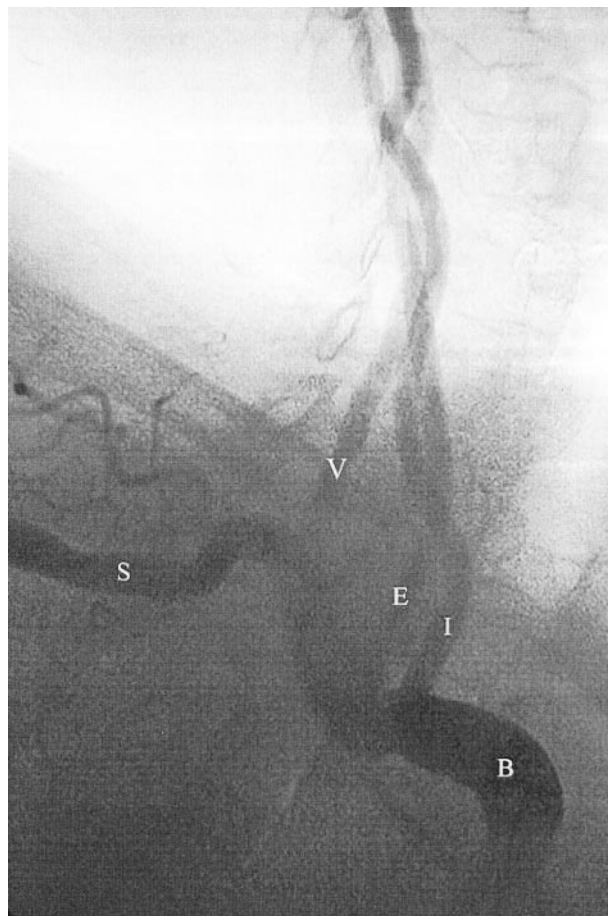


FIG 1. Right brachiocephalic angiogram. Digital subtraction angiogram obtained in a right anterior oblique projection. The ICA (I) arises proximally from the right brachiocephalic artery (B). The ECA (E) arises distal to the ICA. The right vertebral artery (V) and right subclavian artery (S) are also seen.

Discussion

Angiography

When absence of the CCA occurs on the right side, the ECA usually arises proximally from brachiocephalic artery and the ICA arises distally from the subclavian artery proximal to the origin of the vertebral artery (5). In the presence of subclavian artery stenosis between the ICA and vertebral artery, steal syndrome can occur. When the anomaly occurs on the left side, both the ECA and the ICA arise from the aortic arch, with the ECA proximal to the ICA (5). Practical consequences of this anomaly are technical difficulties in performing brachiocephalic angiogra-

Received April 28, 2002; accepted after revision May 4.

From the Department of Radiology (M.M., M.U., E.M.), Lenox Hill Hospital, and the Lenox Hill Heart and Vascular Institute of New York (J.J.V.), New York, NY.

Address reprint requests to Majid Maybody, MD, Lenox Hill Hospital, Department of Radiology, 100 East 77th Street, New York, NY 10021.

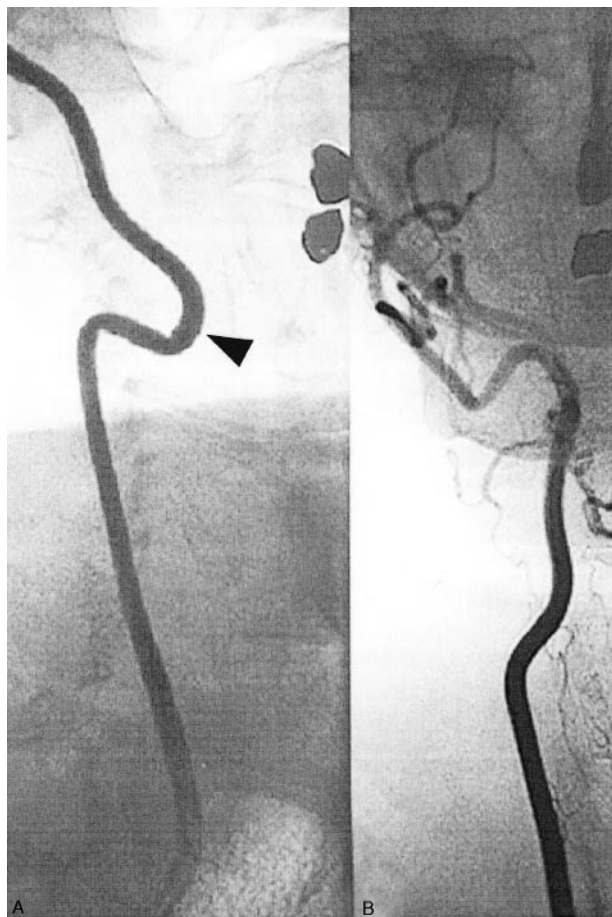

FIG 2. Frontal view digital subtraction angiogram.

A, Course of the right ICA in the neck. Note the tortuosity at the C3–C4 level (arrowhead).

B, Course of the right ECA in the neck.

phy. This anomaly can be missed during selective ICA angiography when it is presumed that the catheter tip is introduced into the ICA above the presumed level of CCA bifurcation. Unlike all reported cases, in our case, the ICA arose proximal to the ECA.

Ultrasonography

Ultrasonography is usually the first test with which to detect the possibility of an absent CCA when the sonographer cannot find normal carotid bifurcation in the neck. Intrathoracic bifurcation of the CCA also can cause the same problem. No significant difference has been reported in resistive indices of ICA and ECA in this anomaly and in normal cases, indicating that the resistive indices and spectral waveforms of the ICA and ECA are mainly determined by their supplied organs and not the CCA (1, 16).

Embryology

In a 12- to 14-mm embryo, the ductus caroticus, which connects the third and fourth branchial arches, dorsally involutes and the proximal portion of ECA forms the CCA, the third branchial arch forms the

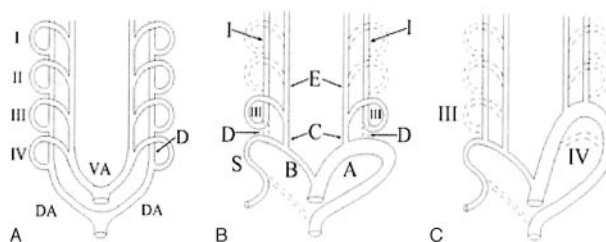


FIG 3.

A, Simplified diagram shows the ventral aorta (VA) and dorsal aorta (DA), with four pairs of branchial arches (I, II, III, and IV) in a 2- to 4-mm embryo. The fifth and sixth arches are not shown. The part of dorsal aorta between the third and fourth branchial arches is called the *ductus caroticus* (D).

B, In a normal 12- to 14-mm embryo, the ductus caroticus (D) and most of the first, second, fifth, and sixth arches involute. The proximal portion of the ECA (E) forms the CCA (C). The third arch (III) forms the carotid sinus and proximal portion of the ICA (I). On the left side, the fourth arch forms the aortic arch (A), and on the right side, it forms the brachiocephalic artery (B) and subclavian artery (S).

C, Absence of the CCA may occur if the third branchial arch (III) involutes and the ductus caroticus persists (*right*) or, alternatively, if the fourth branchial arch (IV) involutes and the persistent third branchial arch forms a cervical aortic arch (*left*).

carotid sinus and the proximal portion of the ICA, and the fourth branchial arch forms a portion of the main aortic arch on the left side and a portion of SCA on the right side (Fig 3A and B) (17). The usual form of absent CCA with the ECA proximal to the ICA occurs either because of persistence of the ductus caroticus and regression of the third branchial arch or because of regression of the fourth branchial arch with resultant cervical aortic arch (Fig 3C). In our case, however, it is likely that an extra twisting of the separate ICA and ECA occurred, causing the ECA to be distal to the ICA.

Conclusion

Absence of the CCA is rare. It is usually incidentally found at autopsy or during workup for other clinical problems; however, it may cause significant practical diagnostic and therapeutic challenges. Unlike other reported cases of an absent CCA with the ECA arising proximal to the ICA, in this case, the ICA arose proximal to the ECA. Reviewing the reported cases of absence of the CCA reveals that the supplied organs of the ICA and ECA and not the presence of the CCA are the main determinants for the shape of resistive indices and frequency of plaque formation and stenosis in these arteries.

References

1. Woodruff WW III, Strunsky VP, Brown NJ. Separate origins of the left internal and external carotid arteries directly from the aortic arch: duplex sonographic findings. *J Ultrasound Med* 1995;14:867–869
2. Fife CD. Absence of the common carotid. *Anat Rec* 1921;22:115
3. Boyd JD. Absence of the right common carotid artery. *J Anat* 1934;68:551

4. Harley HR. **Development and anomalies of the aortic arch and its branches with the report of a right cervical arch and intrathoracic ring.** *Br J Surg* 1959;46:561-573
5. Lie TA. *Congenital Anomalies of the Carotid Arteries.* Amsterdam: Excerpta Medica Foundation; 1968
6. Andrews ET, Howard JM. **Congenital anomalies of the carotid artery: a case report.** *J Am Geriatr Soc* 1963;11:642-646
7. Haughton VM, Rosenbaum AE. **The normal and anomalous aortic arch and brachiocephalic arteries.** In: Newton TH, Potts DG, eds. *Radiology of the Skull and Brain.* vol 2. St. Louis: Mosby; 1974:1145-1163
8. Bryan RN, Drewyer RG, Gee W. **Separate origins of the left internal and external carotid arteries from the aorta.** *AJR Am J Roentgenol* 1978;130:362-365
9. Roberts LK, Gerald B. **Absence of both common carotid arteries.** *AJR Am J Roentgenol* 1978;130:981-982
10. Moore TS, Morris JL. **Aortic arch vessel anomalies associated with persistent trigeminal artery.** *AJR Am J Roentgenol* 1979;133:309-311
11. Halstuk KS, Littooy FN, Baker WH. **Absent common carotid artery associated with amaurosis fugax: a case report.** *Surgery* 1985;97:502-506
12. Jerius JT, Stevens SL, Freeman MB, Goldman, MH. **Vertebrobasilar syndrome associated with subclavian origin of the right internal carotid artery.** *J Vasc Surg* 1995;21:855-861
13. John CE, Johnson SP. **Common origin of left vertebral and left internal carotid artery.** *AJR Am J Roentgenol* 1998;170:514
14. Dahn MS, Kaurich JD, Brown FR. **Independent origins of the internal and external carotid arteries: a case report.** *Angiology* 1999;50:755-760
15. Rossitti S, Raininko R. **Absence of the common carotid artery in a patient with a persistent trigeminal artery variant.** *Clin Radiol* 2001;56:79-81
16. Beach KW, Strandness DE Jr. **Carotid artery velocity waveform analysis.** In: Bernstein EF, ed. *Noninvasive Diagnostic Techniques in Vascular Disease.* St. Louis: CV Mosby; 1985:410.3
17. Sadler TW. *Langman's Medical Embryology.* 8th ed. Baltimore: Lippincott Williams & Wilkins; 2000