

Generic Contrast Agents

Our portfolio is growing to serve you better. Now you have a *choice*.



[VIEW CATALOG](#)

AJNR

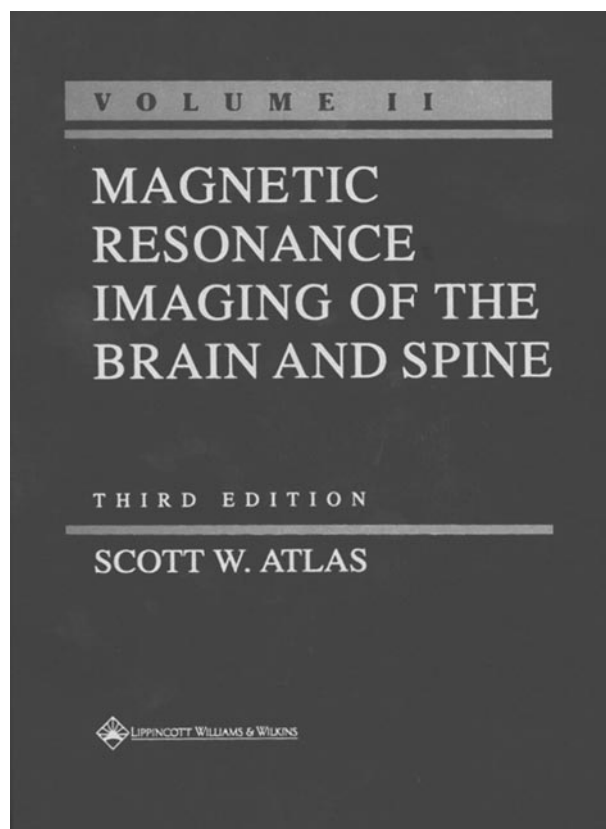
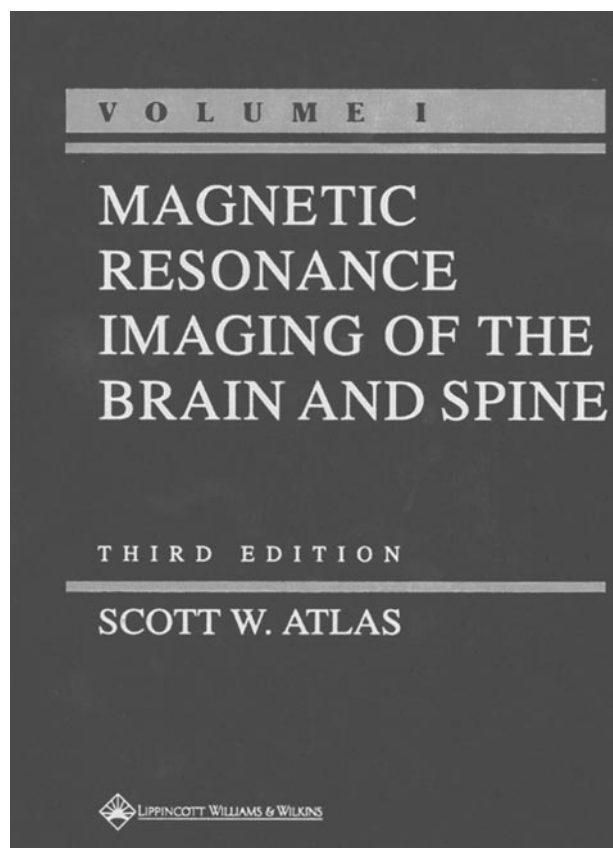
Magnetic Resonance Imaging of the Brain and Spine. Vols. 1 and 2.

AJNR Am J Neuroradiol 2003, 24 (7) 1478-1479
<http://www.ajnr.org/content/24/7/1478>

This information is current as
of May 8, 2025.

Magnetic Resonance Imaging of the Brain and Spine. Vols. 1 and 2.

Scott W. Atlas, ed. 3rd ed. Baltimore: Lippincott Williams & Wilkins; 2001. 2256 pages, 4752 illustrations. \$299.00.



Any neuroradiologist who has recently read the second edition of *MR Imaging of the Brain and Spine* and noted the lack of fluid-attenuated inversion recovery (FLAIR), magnetization transfer, diffusion, and perfusion MR images, as well as the absence of proton spectra, in the clinical case material will agree with Dr. Atlas's preface to his third edition: "It was evident that a new edition was warranted." Atlas and a stellar list of contributors have produced an updated and improved textbook that continues to be the "best-in-the-business" at combining depth of coverage in the basics of MR physical principles with breadth of coverage for clinical neurodiagnostic case material.

The organization of the third edition is new and divided into five parts: (1) principles, (2) brain, (3) skull base, (4) spine and spinal cord, and (5) advanced applications. Four chapters with new titles and material have been written: "Diffusion and Diffusion Tensor MR Imaging" (P. J. Basser), "Perfusion MR Imaging" (D. C. Alsop), "Epilepsy" (R. A. Bronen and V. Gupta), and "Psychiatric Disease" (P. F. Renshaw). These chapters contribute about 150 pages to the overall increase of approximately 400 pages in the third edition (almost 2,050 pages total) from the sec-

ond edition. Other chapters, which have titles similar to those used in the second edition but that are authored by new contributors, differ markedly from the earlier edition with respect to text, images, and diagrams: "Contrast Development and Manipulation in MR Imaging" (I. R. Young and G. M. Bydder), "Fast Imaging Principles" (R. V. Mulkern), "White Matter Diseases and Inherited Metabolic Disorders" (A. O. Nusbaum, K.-M. Fung, and S. W. Atlas), "Cerebral Ischemia and Infarction" (M. Marks), "Spinal Infection and Inflammatory Disorders" (R. A. Mendonca), and "Clinical Functional MR Imaging" (K. R. Thulborn). These new chapters provide many of the book's highlights and some of the best reading. My favorites were "Perfusion MR Imaging," "Cerebral Ischemia and Infarction," and "Clinical Functional MR Imaging," because the MR principles, their clinical application, and the interpretation of results were explained in well-reasoned, amply illustrated, and understandable presentations.

What about the remaining, "old" chapters? They have undergone the obligatory revisions, with positive outcomes for the reader. In Part 2 (Brain), the chapters "Intraaxial Brain Tumors," "Extraaxial Brain Tu-

mors,” and “Intracranial Hemorrhage” have many new cases, and these include FLAIR images in addition to the T1-weighted (plus or minus gadolinium contrast) and T2-weighted images that dominated the second edition. The many advantages of FLAIR, from characterization of “cystic” lesions to the detection of subarachnoid space disease, are emphasized. Unfortunately, there is a relative paucity of diffusion-weighted and dynamic susceptibility-weighted MR images in the chapters on tumors, and the effect that hemorrhage has on diffusion-weighted images is addressed only briefly in the chapter “Intracranial Hemorrhage” (and not at all in the chapter “Cerebral Ischemia and Infarction”). The chapters “Intracranial Vascular Malformations and Aneurysms” and “MR Angiography” provide thorough reviews of the literature from about 1990 to 2000 and abundant case material for the reader’s edification, although there are only two figures demonstrating the application of dynamic contrast-enhanced three-dimensional MR angiography—improved delineation of bilateral giant cavernous carotid aneurysms and improved depiction of the carotid bifurcation in a postendarterectomy patient. The final chapter in part 2, “Normal Aging, Dementia, and Neurodegenerative Disease” (C. R. Jack et al), has a newly added section that gives the reader a concise and authoritative discussion of an important area of quantitative neuroimaging—MR-based imaging measurements (eg, hippocampal formation volumes) for the diagnosis of Alzheimer disease.

Most of the chapters in the third edition have new “key concept” boxes or tables that provide focus to the material being discussed, as well as “pearls” and guidelines that the reader can apply when confronting challenging cases in daily practice. These features make the book more user friendly, but they seem to be less evident or accessible than similar boxes populating the shorter, “quick reference” texts of Grossman and Youssem (*Neuroradiology: The Requisites*, augmented by the Case Review Series for Head and Neck, Brain, Spine) and Osborne (*Neuroradiology*). Many readers, especially residents and fellows who use Osborne’s text to learn neuropathology, likely will continue to prefer her description of histopathologic findings in various diseases.

The chapters in parts 3 and 4 of the third edition have undergone the least change from the second edition, except for the chapter “Spinal Infection and Inflammatory Disorders,” which is double its previous length and has become the second longest chapter (118 pages) in the book behind “Intraaxial Brain Tumors.” The spectrum of infectious and inflammatory disorders that is presented is as complete as a

reader could ever want, although you may conclude, as I did after finishing this chapter, that less would have been better—the pertinent MR findings in spinal neurocysticercosis, for example, could have been demonstrated in less than the eight pages of 52 images. The chapter “The Sella Turcica and Parasellar Region,” more than other “old” chapters in parts 3 and 4, has benefited from the addition of several new cases with higher quality, high-resolution spin-echo images, especially the section on normal anatomy. Not to be outdone, the revised chapter “Temporal Bone” now features new maximum-intensity projection images and shaded, surface-rendered images of the fluid-filled intralabyrinthine spaces, generated from thin, heavily T2-weighted, three-dimensional FT CISS (constructive interference in the steady state) images. The authors argue convincingly that these images combined with gadolinium-enhanced T1-weighted spin-echo images represent the gold standard for temporal bone MR.

What about clinical MR spectroscopy? It is presented to the reader in two formats, probably in an attempt by the editor to ensure adequate coverage of the method and its clinical applications. First, MR spectroscopy is included in a few of the cases presented in the chapters “Epilepsy,” “White Matter Diseases and Inherited Metabolic Disorders,” and “Intracranial Infection” (nice example of a PRESS TE 135 spectrum from a brain abscess); however, MR spectroscopy is conspicuously absent from case material in the chapters “Brain Tumors” and “Neurodegenerative Disease.” Thus, the second format, which is a dedicated chapter on MR spectroscopy and the biochemical basis of neurologic disease, is incorporated into part 5. This approach works for the third edition, but raises the question of how MR neurodiagnostic cases would be presented in a possible fourth edition of Atlas’s lengthy textbook. My guess is that in the parts on brain, skull base, and spine, Atlas and collaborators would have to discard many of the current cases and include new ones illustrated with the full complement of available MR diagnostic “tools” (reflecting current neuroradiological practice)—qualitative findings, and sometimes quantitative results, from spin-echo, gradient-echo, diffusion tensor, dynamic susceptibility, functional activation, and magnetization transfer MR images, as well as metabolite ratios, concentrations, and maps, contrast-enhanced MR angiography, and even MR microscopy. Although a daunting task, the authors and the editor would in all likelihood be up to the challenge, based on their overall success with the third edition.