



## Get Clarity On Generics

Cost-Effective CT & MRI Contrast Agents



FRESENIUS  
KABI

WATCH VIDEO

# AJNR

## Cerebral MR Perfusion Imaging. Principles and Current Applications

*AJNR Am J Neuroradiol* 2003, 24 (7) 1481-1482  
<http://www.ajnr.org/content/24/7/1481>

This information is current as  
of August 7, 2025.

**Cerebral MR Perfusion Imaging. Principles and Current Applications**

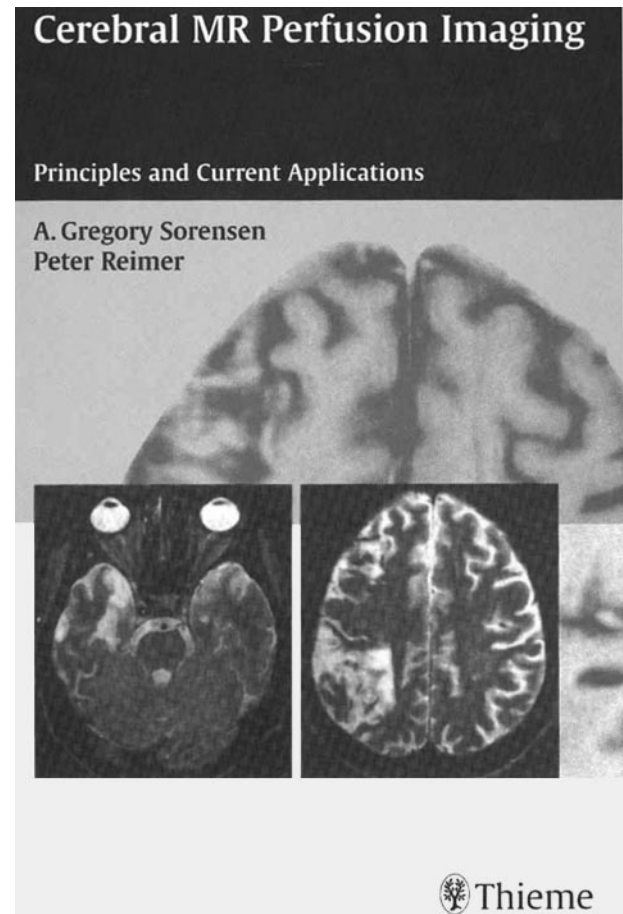
A.G. Sorensen and P. Reimer. Stuttgart, New York; Georg Thieme Verlag; 2001. 160 pages, 235 illustrations. Includes CD-ROM. \$119

MR hemodynamic ("perfusion") imaging is generally considered one of the most important advances in MR imaging over the past few decades. This MR imaging technique has already come to play an important role in assessment of cerebral ischemia and is developing into a valuable tool for evaluation of brain neoplasms. Yet this technique remains substantially underutilized in the clinical setting for a number of reasons, including, to some extent, lack of understanding of technical details and physiologic principles underlying the technique as well as need for postprocessing of hemodynamic data on an independent workstation (which requires operator time and expertise). *Cerebral MR Perfusion Imaging: Principles and Current Applications* does an excellent job of addressing the first issue. Asking a book to deal fully with the second issue is to place unnecessarily high expectations on it. To their credit, however, the authors of this book have done what they can to address the second issue. The authors deserve very high marks for both endeavors.

The book is short but compact and loaded with valuable information that is presented in an easy-to-read conversational style that will allow even those readers who tend to withdraw from technological information to enjoy and understand the text. Most readers will be able to read the book in the course of a week. Those readers who are already familiar with MR hemodynamic imaging will be able to read it in a few nights. The authors recognize that the information inherent in hemodynamic imaging is, in many cases, best illustrated in a dynamic (rather than static) manner. For that reason, the case examples are shown not only as images on the printed page but also by using movie clips on a CD-ROM that accompanies the book.

The book will satisfy interests of readers with varying levels of proficiency with advanced MR imaging techniques. The book is divided into two parts. The first part is concerned with technical considerations, and the second part deals with clinical applications. In the preface, the authors point out a method of reading the book that will help novices in hemodynamic MR imaging—reading the second half of the book first, to gain familiarity with the ways in which MR perfusion imaging can be used.

Part 2 is centered on various applications such as generally well-accepted uses of MR hemodynamic imaging in various stages of cerebral ischemia (acute ischemia, reperfusion after spontaneous thrombolysis, and chronic infarction) and tumor imaging (used for diagnosis, therapeutic assessment, and a guide for biopsy). In addition, a number of topics in which MR perfusion imaging may play a role in diagnosis and



therapy are discussed, such as dementia, head trauma, vasospasm, migraine, and epilepsy.

In part 1, the authors explain MR hemodynamic imaging principles with a great deal of clarity and with explanations of not only why certain techniques are favored but also why others are not favored. This approach naturally has the benefit of providing a true understanding of the principles rather than simply a recipe for performance of the techniques. The clarity of the approach mirrors that shown in public presentations by Dr. Sorensen, in which advanced ideas are explained in basic language in a manner that allows beginners to understand, and experienced users to have increased appreciation for, fundamental material. Part 1 attempts to answer questions that any user of MR perfusion imaging is likely to ask, such as "what is the influence of rapidity of bolus infusion on image quality?" "what are the relative advantages of spin-echo technique as compared with gradient echo technique?" and "how does MR scanner field strength affect image quality." In

addition, a number of technical issues are addressed, such as the range of acceptable doses of contrast material, importance of bolus infusion and rapid imaging techniques, effect of a leaky blood-brain barrier on image quality, and use of noncontrast techniques to obtain hemodynamic data. Finally, a detailed description of how to postprocess MR hemodynamic data, which is as important an issue as obtaining the data (and which is a practical topic that can dampen enthusiasm of individual users), is presented. As one can see from this description, the reader can use this book to satisfy a number of needs, ranging from a wish to obtain the information needed to simply start MR perfusion imaging to a wish to gain a good understanding of the fundamental principles operative in use of these techniques.

The CD-ROM that accompanies the book contains the entire text and images of the book as well as additional images and movies clips that illustrate the data that underlay the static images in the book. In addition, the CD-ROM contains postprocessing software that can be used to process the reader's own imaging data. The authors issue a caveat that they cannot provide technical support for this software,

and it would be indeed be unreasonable to expect so. In principle, this software should be a valuable tool for readers who wish to use this software to begin processing data. The practical reality, however, is that this software will not be easily used by most readers, because it must be installed on either a PC operating LINUX software or on a Sun workstation and presupposes familiarity with the UNIX environment, which will not likely be the case for most readers.

This book is indeed unique because (to this reviewer's knowledge) there are no other books that set out to explain the subject matter contained herein. This book will prove very valuable to the those who wish to learn about MR perfusion imaging because of the straightforward explanations of imaging techniques and the excellent illustrations. It is true that novices in this field will find the most value in this book. Even those who already have some knowledge of MR perfusion imaging, however, will likely gain valuable insights from reading it. The authors are to be congratulated for writing a short and inexpensive book that informs the reader about a relatively complex (but increasingly important topic) in a succinct and clear manner.