



Discover Generics

Cost-Effective CT & MRI Contrast Agents



FRESENIUS
KABI

[VIEW CATALOG](#)

AJNR

Gadolinium Diskography

Andrew L. Wagner

AJNR Am J Neuroradiol 2004, 25 (10) 1824-1827

<http://www.ajnr.org/content/25/10/1824>

This information is current as
of September 16, 2025.

Technical Note

Gadolinium Diskography

Andrew L. Wagner

Summary: Gadolinium can be used to perform diskography in patients with a documented allergy to iodinated contrast material. MR images can be obtained in multiple planes with excellent delineation of disk architecture. Dilute gadolinium leaves the disk space within a few days of injection.

Diskography has traditionally been performed by using iodinated contrast materials, typically with post-diskography CT to document the number and nature of annular tears. This approach, however, is a problem in patients with an allergy to contrast medium, because even with premedication, the risk of life-threatening anaphylactoid reaction remains. Gadolinium diskography can be performed in these patients by using a dilute gadolinium mixture and postdiskography MR imaging; however, the long-term effects of intradiskal gadolinium are unknown, and although it has been used safely in other joint spaces, the length of time needed for gadolinium to leave the disk is likely different because of the lack of blood supply to the nucleus. This is a report of nine cases of gadolinium diskography with MR imaging; follow-up MR images were obtained from most patients to evaluate the time needed for the contrast material to leave the disk space.

Description of Technique

The study consisted of 26 injected disks in nine patients. All patients included in the study underwent preoperative planning diskography ordered by a spine surgeon and had a known history of an anaphylactoid reaction to iodinated contrast medium. The patients were examined before the preoperatively to customize the procedure on the basis of MR imaging findings, pain pattern, and the presurgical question or questions to be answered. All patients were informed of the risks and benefits of diskography, which included a discussion of the off-label use of gadolinium within the disk space, and provided informed consent. Institutional review board approval had been previously granted for injection of gadolinium into joint spaces within the body, and it was confirmed that this procedure was covered by the approval.

Diskography was performed by using a coaxial needle system with a mobile C-arm for fluoroscopic guidance. Twenty-two gauge spinal needles were used to puncture the disks and were

maneuvered into the center of the disk spaces. Following confirmation of appropriate needle placement in two planes, the disks were injected with a dilute gadolinium and antibiotic mixture made by diluting 1 mL Magnavist in 140 mL of normal saline and diluting 9 mL of this mixture with 200 mg of cefazolin in 2 mL of sterile water (Table). This solution was then placed into 3-mL syringes for individual disk injections, and diskography was performed. The patients were then transported to a 1.5-T MR imaging unit and underwent MR imaging of the lumbar spine by using axial, coronal, and sagittal T1-weighted, fat-saturated sequences as well as an axial T2-weighted, fat-saturated sequence (Fig 1A, -B). The axial images were acquired with multiple angulations to allow true transverse images through each disk. Eight patients returned at variable intervals over the next 7 days following their procedure for a single sagittal T1-weighted, fat-saturated sequence, and the images were reviewed to evaluate whether there was any detectable residual gadolinium in the disk spaces or the paravertebral soft tissues (Fig 1C).

Results

Diskography was successful in all cases, with no annular injections detected on MR images. Evoked pain response was appropriate with no false-positive control disks and variable responses at the abnormal disk spaces. There was one control disk that resulted in exact reproduction of the patient's pain during diskography despite a normal MR imaging appearance, but postdiskography MR imaging subsequently demonstrated this disk space to have a small radial annular tear extending into the neural foramen (Fig 2A and B). During injection of two levels, there was no resistance felt during injection, resulting in uncertainty whether this was due to a patulous nucleus or extravasation. These injections were terminated after 3–4 mL had been injected.

MR images clearly demonstrated disk morphology at all levels. The number, type, and extent of annular tears were clearly visible at all abnormal levels, and the multiplanar capabilities of MR imaging allowed quantification of the direction and extent of oblique annular tears, which were difficult to fully evaluate on the basis axial image findings alone (Fig 1B). There was minor extravasation of contrast medium at two levels, with one instance of major extravasation into the paravertebral tissues through a large annular tear.

Four of five patients imaged 3–7 days after diskography had no visible residual gadolinium, and the other had only faint increased signal intensity remaining in the disk spaces at 3 days. In the patient who returned 1 day after the procedure, contrast medium was noted to have spread throughout the annular fibers in the relatively normal disks and was completely gone from a severely degenerated disk (Fig 3).

Received March 16, 2004; accepted after revision April 22.

From the Department of Radiology, Rockingham Memorial Hospital, Harrisonburg, FL; and the Department of Radiology, University of Virginia School of Medicine, Charlottesville, VA.

Presented at the 41st annual meeting of the American Society of Neuroradiology, Washington, DC, April 27–May 2, 2003.

Address correspondence to Andrew L. Wagner, MD, Department of Radiology, Rockingham Memorial Hospital, 235 Cantrell Avenue, Harrisonburg, FL 22801.

Formula for gadolinium discography

1. Mix 1 cc Magnavist in 140 cc Sterile saline (use 250-cc bag and remove 110 cc).
2. Dilute 1 g Ancef powder in 10 cc sterile water.
3. Mix 9 cc dilute gadolinium mixture with 1 cc (100 mg) Ancef for every 10 cc of contrast needed.

Discussion

Diskography, while still a controversial topic in terms of clinical value, remains widely practiced and is considered to be a useful diagnostic and preoperative tool by many spinal surgeons. Typically, fluoroscopic images, CT images, or both are obtained during diskography, and to visualize the disk abnormalities iodinated contrast agents must be used. Patients with a known history of allergy to iodinated contrast, however, are not uncommon in light of the reported incidence of 0.7%, and although most reactions are minor, 0.05% will have life-threatening anaphylactic reactions (1). Even when patients with a history of contrast medium-induced anaphylaxis are premedicated with steroids and antihistamines, there is still a risk of recurrent anaphylaxis, and the risk of such an event is also increased in patients with a history of prior minor allergy, such as hives. MR diskography will allow the same evoked response as that of conventional diskography while avoiding administration of iodinated contrast medium.

Dilute gadolinium has been used as a contrast agent with great effectiveness in multiple joints throughout the body, including the shoulder, knee, wrist, elbow, temporomandibular joint, and facet joints (2–4). Huang et al (5) compared postdiskography CT and MR images by using patients who had been injected with a mixture of iodinated contrast and gadolinium, and found a high degree of interimage and interobserver correlation, which indicates that postgadolinium MR diskography would be likely to give equivalent anatomic information as that with conventional postdiskography CT.

A similar technique was used in this study, although the disks were injected only with gadolinium, in light of the patient's allergies, and found to be effective in visualizing and quantifying annular tears, disk protrusions, and the relationship to the adjacent nerve roots. The multiplanar capabilities of MR imaging were useful in obtaining a 3D understanding of the annular tears, particularly those that were oriented obliquely, although multiplanar CT scanners also allow multiplanar reconstructions of the spine and have been used effectively in postdiskography CT. One advantage of postdiskography MR imaging compared with CT is, whereas iodinated contrast medium can be difficult to differentiate from vertebral body endplates on CT, because of similarity in Hounsfield units, gadolinium is clearly distinguishable with the use of fat-saturated T1-weighted sequences. In addition, the use of MR imaging avoids the considerable radiation dose associated with CT, particularly because most patients who undergo diskography are relatively young.

One factor that has never been addressed in the literature, however, is the natural history of gadolinium within the disk space. Gadolinium is known to leave synovial joints easily, following intra-articular injection because of the abundant blood supply, so much so that epinephrine is sometimes injected during arthrograms to slow the absorption. Because the composition of the nucleus pulposus is similar to articular cartilage, it would be expected that gadolinium would be safe to use within the disk space. The disk space, however, although technically a joint, does not have the same blood supply of the synovial joints, and indeed there are no blood vessels within the nucleus pulposus at all. Iodinated contrast medium within the disk is known to slowly diffuse through the annular fibers, and it would seem likely that gadolinium would have the same effect. If gadolinium were to persist within the avascular nucleus pulposus, however, it could be problematic, because the long-term effect of gadolinium in the disk space is unknown. Certainly, the presence of persistent gadolinium within the disk space could limit future MR imaging studies.

As demonstrated by this admittedly small study, gadolinium appears to leave the normal disk space over 2–3 days, and even more rapidly in severely deranged disks (Figs 2C and 3). The patient who returned over the first 3 days showed a pattern of slow diffusion through the annular fibers similar to that seen with iodinated contrast material, and as with such contrast material, it is likely absorbed by the peripheral vessels. The disk signal intensity returned to normal following gadolinium diskography with no MR imaging evidence of residual gadolinium in any of the cases that were followed past 3 days. Disk levels that were demonstrated to have more severe annular derangement also showed the quickest loss of gadolinium, which is likely due to increased peripheral blood supply and less distance for the contrast to travel because of thinning and breakage of the annulus.

Gadolinium diskography, however, is not without its drawbacks. Diluting the gadolinium prevents visualization under fluoroscopy during the procedure, and annular injections cannot be seen at the time of injection. This can be prevented by careful attention to needle placement, ensuring that the needle tip is as close to the center of the disk as possible, as well as experience in typical resistance felt when injecting the nucleus pulposus. Another unavoidable drawback of gadolinium diskography is the inability to recognize major extravasation, which is typically an end point in diskography, although a marked lack of pressure during an injection of 2–3 mL should prompt consideration of this possibility. In addition, because MR imaging is more expensive than CT scanning, gadolinium diskography increases the cost to the patient, a point that cannot be easily dismissed.

Full-strength gadolinium cannot be used in MR diskography, because it will actually be dark on

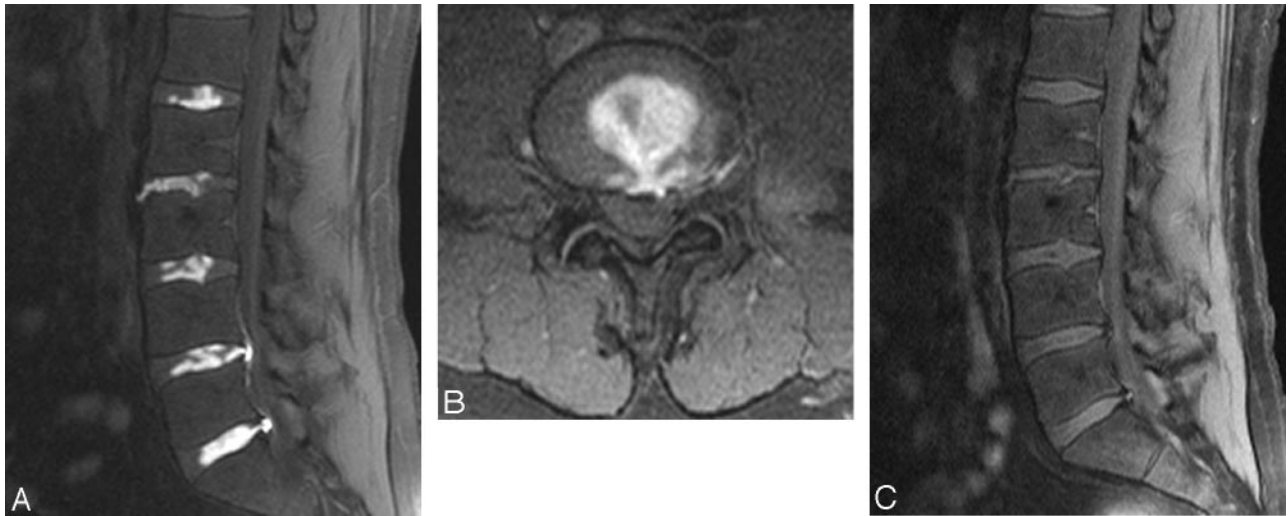


FIG 1. Gadolinium diskogram obtained in a 42-year-old man with back pain.

A, Sagittal fat-saturated T1-weighted image (TR 758, TE 10) demonstrates the excellent contrast between the gadolinium and adjacent tissues. The distinction between normal and abnormal disks is clearly evident. Note the contrast medium extending posteriorly through radial annular tears at L4-L5 and L5-S1, filling posterior disk protrusions. The L3-L4 nucleus pulposus appears relatively normal.

B, Axial T1-weighted, fat-sat (TR 760, TE 16) image from L4-L5 demonstrates a posterior annular tear with some contrast medium extravasation in the left foramen. There is also filling of a small left paracentral posterior disk protrusion.

C, Seven-day postdiskography image from the same patient demonstrates no detectable residual disk space gadolinium.

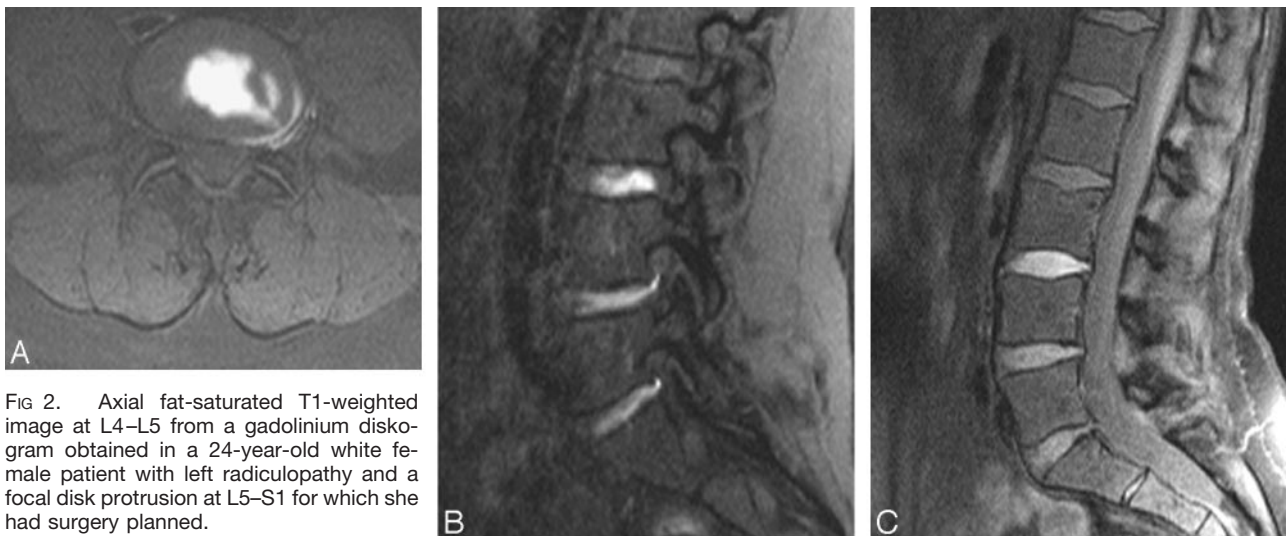


FIG 2. Axial fat-saturated T1-weighted image at L4-L5 from a gadolinium diskogram obtained in a 24-year-old white female patient with left radiculopathy and a focal disk protrusion at L5-S1 for which she had surgery planned.

A, Axial T1-weighted, fat-saturated (TR 829, TE 16) reveals an annular tear ending directly adjacent to the left L4 root.

B, Sagittal image again demonstrates the posterolateral annular tear directly adjacent to the intraforaminal nerve root.

C, Sagittal image obtained 2 days after diskography demonstrates significantly diminished gadolinium in the L4-L5 and L5-S1 disk spaces, whereas the L3-L4 disk space demonstrates diffusion of contrast medium throughout the annular fibers.

T1-weighted sequences. It has been shown that full-strength gadolinium could be used with a post-diskography CT (6), because gadolinium has been successfully used by angiographers in patients with contrast media allergies and is visible with both fluoroscopy and CT. It is nonetheless uncertain what effect, if any, full-strength gadolinium would have on the disk itself, although it seems unlikely there would be any deleterious response. It is intuitive that a markedly dilute gadolinium mixture, such as in this study, would be inherently safer than full strength.

Conclusion

This study shows the feasibility of gadolinium-enhanced diskography in patients with a history of allergy to iodinated contrast material. Dilute gadolinium results in a good provocative response, and postprocedural MR imaging clearly demonstrates disk morphology and localizes annular tears. Gadolinium leaves the disk space over 2-3 days and will not limit any further MR imaging. Gadolinium diskography is an alternative to conventional diskography in patients with a history of allergy to iodinated contrast

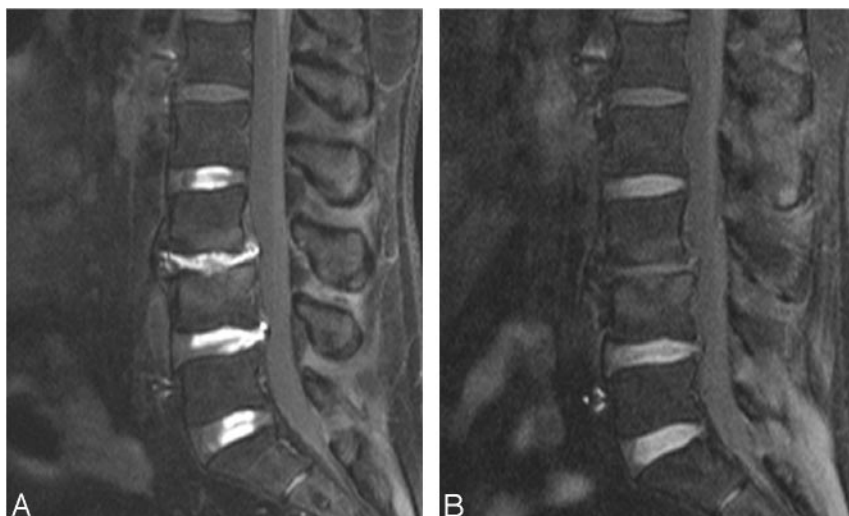


FIG 3. Images obtained in a 47-year-old man with back pain.

A, Sagittal T1-weighted, fat-saturated (TR 954, TE 15) from an initial postgadolinium diskogram again shows the excellent delineation of disk architecture with normal-appearing disk spaces at L2–L3 and L5–S1, whereas the L3–L4 level is severely narrowed, with no recognizable disk architecture remaining. Both the L3–L4 and L4–L5 levels have contrast filling subligamentous disk extrusions.

B, The same patient, 1 day after discography. Gadolinium has begun to diffuse across the annulus and is now seen in the outer annular fibers at all levels. At L3–L4, the most severely deranged level, the amount of residual gadolinium is markedly less than at the other levels.

medium or in those who wish to reduce radiation exposure.

References

1. Cochran ST, Bomyea K, Sayre JW. Trends in adverse events after IV administration of contrast media. *AJR Am J Roentgenol* 2001;176:1385–1388
2. Hodler J, Kursunoglu-Brahme S, Snyder SJ, et al. Rotator cuff disease: assessment with MR arthrography versus standard MR imaging in 36 patients with arthroscopic confirmation. *Radiology* 1992;182:431–436
3. Cotten A, Jacobson J, Brossmann J, et al. MR arthrography of the elbow: normal anatomy and diagnostic pitfalls. *J Comput Assist Tomogr* 1997;21:516–522
4. Toyama M, Kurita K, Koga K, Rivera G. Magnetic resonance arthrography of the temporomandibular joint. *J Oral Maxillofac Surg* 2000;58:978–983
5. Huang TS, Zucherman JF, Hsu KY, et al. Gadopentetate dimeglumine as an intradiscal contrast agent. *Spine* 2002;27:839–843
6. Falco FJ, Moran JG. Lumbar discography using gadolinium in patients with iodine contrast allergy followed by postdiscography computed tomography scan. *Spine* 2003;28:E1–E4