

# Generic Contrast Agents

Our portfolio is growing to serve you better. Now you have a choice.



FRESENIUS  
KABI

[VIEW CATALOG](#)

## Erratum

# AJNR

*AJNR Am J Neuroradiol* 2004, 25 (4) 666  
<http://www.ajnr.org/content/25/4/666>

This information is current as  
of May 12, 2025.

---

## Erratum

In the article **Spontaneous Superficial Parenchymal and Leptomeningeal Hemorrhage in Term Neonates**, Huang HA and Robertson RL, AJNR 25:469–475, March 2004, the figure orientation for figures 5A and 5B was incorrectly printed. The correct figure orientation is shown below:

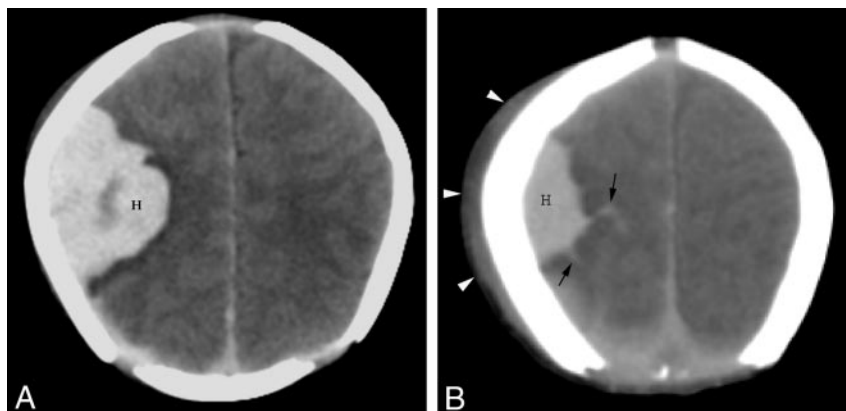


FIG 5. Unenhanced CT scans of a neonate (patient 6) with focal seizures at 18 hr of life.  
A, CT scan shows a right parietal parenchymal hematoma (*H*).  
B, CT scan obtained at a slightly higher anatomic section reveals additional hemorrhage (*H*) with extension into the sulci, indicating leptomeningeal bleeding (*arrows*). A large overlying cephalohematoma (*arrowheads*) is also present.