

Generic Contrast Agents

Our portfolio is growing to serve you better. Now you have a *choice*.



[VIEW CATALOG](#)

AJNR

Multiple Cerebral Aneurysms in Factor VII Deficiency

Andreas M. Schilling, Jens O. Heidenreich, Anja C. Oldenburg, Terttu Pietilä, Rüdiger Stendel and Karl-Jürgen Wolf

This information is current as of May 10, 2025.

AJNR Am J Neuroradiol 2004, 25 (5) 784-786
<http://www.ajnr.org/content/25/5/784>

Case Report

Multiple Cerebral Aneurysms in Factor VII Deficiency

Andreas M. Schilling, Jens O. Heidenreich, Anja C. Oldenburg, Terttu Pietilä, Rüdiger Stendel, and Karl-Jürgen Wolf

Summary: A rare case of multiple cerebral aneurysms and factor VII deficiency is presented. The authors hypothesize a possible combined genetic defect similar to that of other conditions with clotting disorders. Different treatment options are discussed for factor VII deficiency in particular and multiple cerebral aneurysms in general. The authors advise treatment of all detected aneurysms in case of a subarachnoid hemorrhage rather than only treatment of the ruptured aneurysms in order to immediately start the so-called triple-H therapy.

The etiology of cerebral aneurysms has not yet been fully clarified. The reported incidence is 6–16/100 (1). Striking is the familial and regional clustering, especially in Finland and Japan, with still unknown underlying genetic factors. Moreover, cerebral aneurysms are significantly more frequent in conjunction with certain diseases and syndromes, including Ehlers-Danlos syndrome, Marfan syndrome, von Recklinghausen neurofibromatosis type 1, autosomal dominant polycystic kidney disease, and coarctation of the aortic arch (2). These disorders are also associated with a higher incidence of multiple cerebral aneurysms. We describe a patient with multiple aneurysms and factor VII deficiency and discuss different treatment options as well as the possibility of a combined genetic defect.

Case Report

A 41-year-old female patient complained of sudden leg pain and lost consciousness shortly thereafter. Cranial CT (CCT) showed a subarachnoid hemorrhage (SAH), Fisher grade 4 (Fig 1A) (3). Subsequent digital subtraction angiography (DSA) disclosed a 2-mm aneurysm in the left posterior communicating artery (PCoM) and another, 3-mm, aneurysm in the middle cerebral artery (MCA) on the left (Fig 1B). Infundibular dilatation of the right MCA was also seen. The source of bleeding could not be definitely determined. The blood distribution pointed to the PCoM aneurysm as the source of bleeding. Both aneurysms were completely embolized with platinum Guglielmi detachable coils (GDCs; Fig 1C). No further aneurysms were detected. A loop hanging from the MCA aneurysm

into the left M1 segment necessitated infarction prophylaxis, which was performed by initiating temporary heparinization for a week.

A reported factor VII deficiency was confirmed with blood serum levels of around 20%. The calcium antagonist nimodipine and hypervolemic hydration were used for prophylaxis of cerebral vasospasms. The systolic arterial pressure thresholds were set at 120–160 mm Hg.

The patient recovered within the first few days (Glasgow coma scale 15), but then developed an elevated intracerebral pressure of 45 mm Hg accompanied by strong headache and right-sided hemiparesis. The CCT check disclosed fresh prepontine bleeding as well as internal hydrocephalus. Repeat DSA revealed a new, smoothly shaped 3-mm aneurysm at the origin of the left posterior inferior cerebellar artery (PICA) (Fig 2A), which showed an extravasation from the dome while adjusting for the optimal working position (Fig 2B). Uncomplicated embolization of the aneurysm was achieved with GDCs in the same session (Fig 2C).

Ventricular drainage was performed for decompression. Recombinant factor VII substitution was used to treat the factor VII deficiency with an average Quick of 40–60% and a factor VII value of 20%. The cerebral vasospasms and increasing brain pressure could not be controlled despite drainage and drug therapy. The patient died of malignant brain edema with multiple cerebral infarctions and terminal cardiac failure.

Discussion

The etiology of cerebral aneurysms has yet to be clarified. A congenital origin is thought to be probable. Striking is the familial and regional clustering. Diseases frequently associated with cerebral aneurysms—including Ehlers-Danlos syndrome type IV, Marfan syndrome, von Recklinghausen neurofibromatosis type 1, autosomal dominant polycystic kidney disease, and aortic coarctation—are in part the expression of genetic abnormalities. There is also a high incidence of multiple cerebral aneurysms.

The patient described had an isolated, probably hereditary, factor VII deficiency with decreased Quick values. The hereditary factor VII deficiency is autosomal recessive and the decrease in blood serum levels less pronounced in the heterozygous than in the homozygous form.

Both the congenital and acquired factor VII deficiency is known to be associated with an increased intracranial bleeding tendency (4). To our knowledge, the extent to which clotting disorders influence the development of cerebral aneurysms has not yet been investigated. The coexistence of multiple aneurysms and an infundibular dilatation in the anterior circulation and the development of another aneurysm in the posterior circulation within a few days at least suggest

Received July 2, 2003; accepted after revision September 16.

From the Departments of Radiology and Nuclear Medicine (A.M.S., J.O.H., A.C.O., K.-J.W.) and Neurosurgery (T.P., R.S.), University Hospital Benjamin Franklin, Free University of Berlin, Germany.

Address correspondence to Jens O. Heidenreich, MD, Klinik und Poliklinik für Radiologie und Nuklearmedizin, Universitätsklinikum Benjamin Franklin, Freie Universität Berlin, Hindenburgdamm 30, 12200 Berlin, Germany.

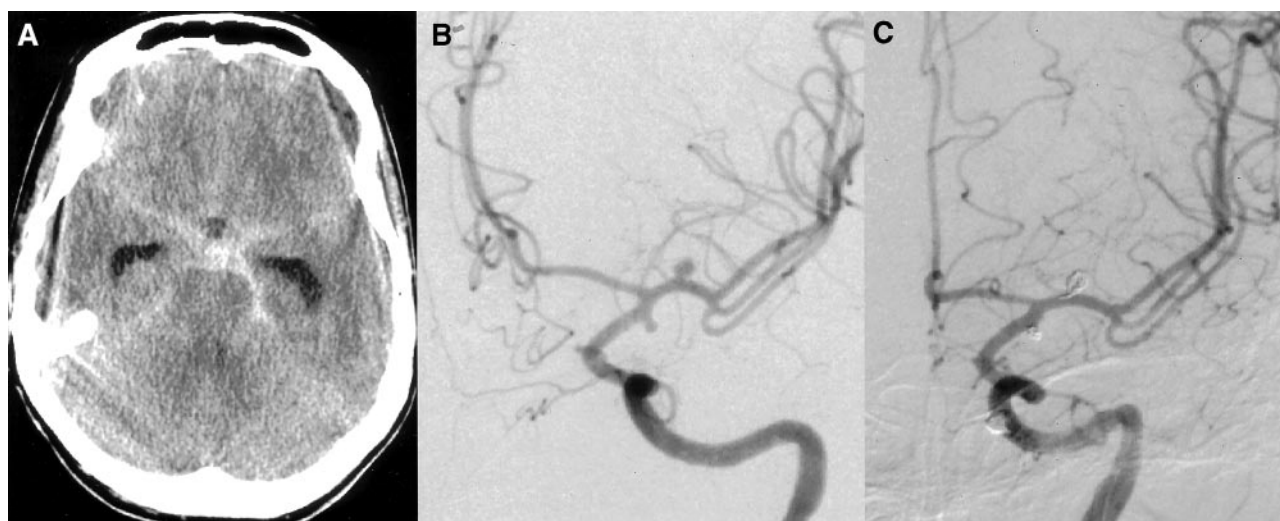


FIG 1. CT on admission (A). SAH Fisher grade 4. Angiograms before (B) and after (C) embolization with platinum coils.

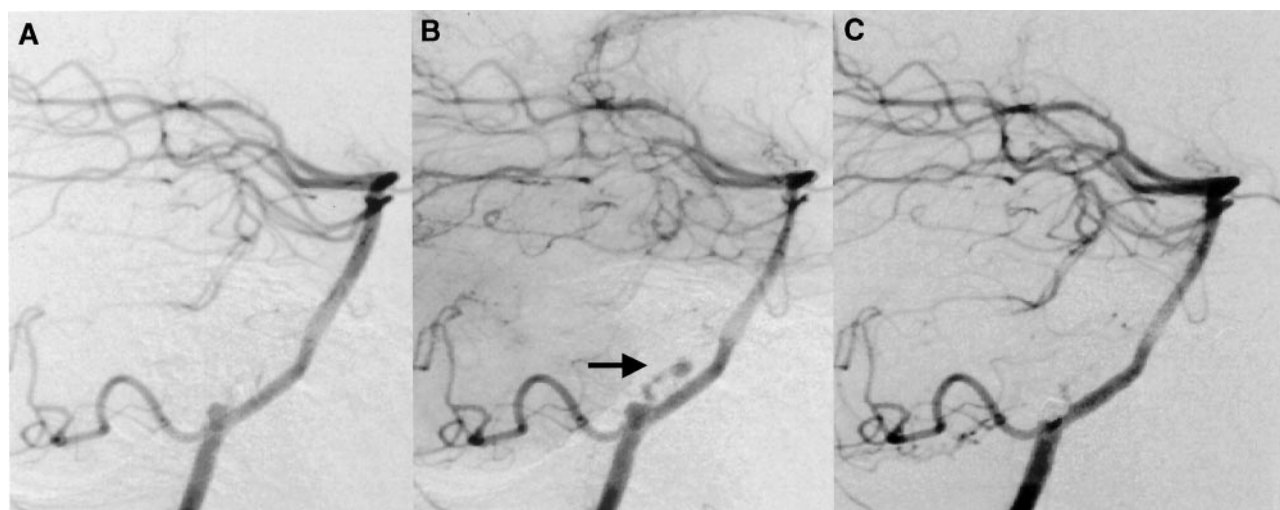


FIG 2. PICA aneurysm before (A) and after (C) embolization. Extravasation during angiography (B, arrow).

a relation beyond the incidental concurrence of two genetically determined diseases. One possibility would be a direct rheological or hemodynamic influence on the integrity of the vessel wall, as also discussed for *de novo* aneurysm development (2). The embolization or the bleeding itself could be a strong enough stimulus for recurrence of the PICA aneurysm. Another possibility is a direct influence of clotting factors upon the vessel wall. However, the impact of these probable additional factors on treatment, especially in the acute phase of SAH, is unclear.

Aneurysms are treated by a neurosurgical intervention or the less invasive procedure of endovascular embolization. A comparison (5) of the two methods carried out by the ISAT study shows that endovascular interventions carry a 22.6% lower relative risk and a 6.9% lower absolute risk of death or serious disability than neurosurgical management. Recurrent bleeding is rare with both treatment options after an observation period of 1 year. Detection of the bleeding source is fairly reliable in cases revealing only one aneurysm, and therapy can be initiated without delay.

There is still controversy about whether to treat further aneurysms in a different vascular territory in cases with multiple aneurysms and a localized source of bleeding. The study performed by Wiebers et al (6) reported an annual rupture risk ranging from 0.05% (<10 mm) to 1% (>10 mm), depending on the size and localization of the aneurysm. A history of SAH increased the rupture probability for aneurysms with maximum diameter <10 mm. Only giant aneurysms exceeding 25 mm in diameter ruptured in 6.5% per year. The observation period was 7.5 years (7). These study results, however, are not assessed uncritically. Various studies report a mortality of 45–83% after the first SAH (1).

In this particular case, all aneurysms demonstrated by initial angiography were treated. The PICA aneurysm responsible for the subsequent recurrent bleeding could not be detected at the first examination. It was either not yet present at that time or thrombosed and thus escaped angiographic detection; however, the increased bleeding tendency associated with fac-

tor VII deficiency must definitely be assessed here as a risk factor for the renewed SAH.

Despite immediate intervention with clipping or coiling, recurrent bleeding in the first 14 days with all its consequences is the greatest problem besides vasospasms. An unfavorable clinical course and irreversible damage are three times more frequent in patients with cerebral vasospasms. Vasospasm prophylaxis is thus advisable and typically consists of the so-called triple-H therapy. Vessel-relaxing calcium antagonists have also proved useful.

In summary, this case description should illustrate several points. There is a known connection between cerebral aneurysms and genetic diseases. This could also apply to hereditary factor VII deficiency, but further documented cases are required for confirmation. Moreover, clotting disorders in cases of cerebral aneurysms with SAH are associated with an increased intracranial rebleeding risk and a poorer clinical course. Thus, a very careful search for further aneurysms is imperative to avoid recurrent bleeding in patients with SAH and factor VII deficiency.

References

1. Bederson JB, Awad IA, Wiebers DO, et al. **Recommendations for the management of patients with unruptured intracranial aneurysms: a statement for healthcare professionals from the Stroke Council of the American Heart Association.** *Stroke* 2000;31:2742–50
2. Tonn J, Hoffmann O, Hofmann E, et al. **“De novo” formation of intracranial aneurysms: who is at risk?** *Neuroradiology* 1999;41:674–679
3. Fisher CM, Kistler JP, Davis JM. **Relation of cerebral vasospasm to subarachnoid hemorrhage visualized by computerized tomographic scanning.** *Neurosurgery* 1980;6:1–9
4. Erduran E, Mocan H, Aslan Y, et al. **Multiple intracranial hemorrhages at the time of a transiently prolonged activated partial thromboplastin time in an infant with congenital factor VII deficiency.** *Haemostasis* 1998;28:14–16
5. Molyneux A, Kerr R, Stratton I, et al. **International Subarachnoid Aneurysm Trial (ISAT) Collaborative Group. International Subarachnoid Aneurysm Trial (ISAT) of neurosurgical clipping versus endovascular coiling in 2143 patients with ruptured intracranial aneurysms: a randomised trial.** *Lancet* 2002;360:267–274
6. Wiebers DO, Piegras DG, Brown RD Jr, et al. **Unruptured aneurysms.** *J Neurosurg* 2002;96:50–51; discussion 58–60
7. The International Study of Unruptured Intracranial Aneurysms Investigators. **Unruptured intracranial aneurysms: risk of rupture and risks of surgical intervention.** *N Engl J Med* 1998;339:1725–1733