

# Generic Contrast Agents

Our portfolio is growing to serve you better. Now you have a *choice*.



[VIEW CATALOG](#)

# AJNR

## **Technical Modification in the Intracarotid Chemotherapy and Osmotic Blood-Brain Barrier Disruption Procedure to Prevent the Relapse of Carboplatin-Induced Orbital Pseudotumor**

This information is current as of May 12, 2025.

David Fortin, Joseph A. Salamé, Annick Desjardins and Andrew Benko

*AJNR Am J Neuroradiol* 2004, 25 (5) 830-834  
<http://www.ajnr.org/content/25/5/830>

## Technical Modification in the Intracarotid Chemotherapy and Osmotic Blood-Brain Barrier Disruption Procedure to Prevent the Relapse of Carboplatin-Induced Orbital Pseudotumor

David Fortin, Joseph A. Salamé, Annick Desjardins, and Andrew Benko

**Summary:** The blood-brain barrier disruption (BBBD) procedure is an established strategy to enhance drug delivery to brain tumors. Complication rates associated with this procedure are usually low, but when complications do occur, they usually mandate discontinuation of treatment. Orbital pseudotumor is an inflammatory condition of one or more extraocular muscles that produces limitation of ocular motility. Patients usually experience sudden diplopia associated with orbital pain, conjunctival chemosis and injection, and proptosis. Imaging of the orbit shows diffuse enlargement of the extraocular muscles, exophthalmia, and, rarely, sinusal or intracranial infiltration. On pathologic examinations, the soft tissues of the orbit are infiltrated with a mixture of eosinophils, lymphocytes, and plasma cells. Many etiologies can induce this syndrome, including the intracarotid infusion of platinum molecules. As part of a phase II study, a total of 110 patients were treated for malignant brain tumors with intra-arterial carboplatin, enhanced by the BBBD procedure, at the Sherbrooke University Hospital. Here we report on three patients who developed orbital pseudotumor ipsilateral to the carotid infused a few hours to days after the procedure. After the occurrence of this syndrome in the first patient, we developed a technical modification to the procedure that enabled uninterrupted treatment in the other two patients. This modification was as follows: after the mannitol infusion, and before carboplatin, the catheter was changed for a 3.5 tracker and was repositioned just above the emergence of the ophthalmic artery.

Birch-Hirschfeld first described the syndrome of orbital pseudotumor in 1905. Orbital pseudotumor is an inflammatory condition of one or more extraocular muscles that produces limitation of ocular motility; it may be bilateral and recurrent. Patients usually experience painful eye movements, lid edema, conjunctival hyperemia and chemosis, poor extraocular motility, diplopia due to restriction of extraocular muscle movement, and proptosis (1–3). Many diseases are

associated with orbital myositis, including Crohn disease, Lyme disease, Wegener granulomatosis, paraneoplastic syndrome in non-Hodgkin lymphoma, psoriatic arthropathy, systemic lupus erythematosus, and rheumatoid arthritis (4, 5). The major differential diagnosis includes thyroid ophthalmopathy, orbital cellulitis, metastasis, Tolosa-Hunt syndrome, trochleitis, and infectious myositis due to trichinosis (4).

Imaging of the orbit typically shows diffuse enlargement of the extraocular muscles, exophthalmia, and, rarely, sinusal or intracranial infiltration. Pathologic examination depicts orbital soft tissues (fat, muscles, lacrimal glands, and optic nerve) infiltration with a mixture of eosinophils, lymphocytes, and plasma cells. Proliferating fibrous tissue is also seen (5). Typically, a rapid clinical response to steroids is observed. Cases resistant to steroids can be treated with radiation therapy and chemotherapy.

To date, five cases of orbital myositis related to chemotherapy have been described in the literature: one case each related to nimustine/carmustine, and a combination of carboplatin and etoposide, and two cases related to cisplatin (6–8).

Platinum salts are broad-spectrum alkylating agents composed of a central platinum atom attached to two ammonia groups and one or more leaving groups, which confer their properties to the molecule (9–11). The antineoplastic effects of platinum compounds are exerted through induction of DNA and RNA alkylation and cytoplasmic proteins modifications. Carboplatin has been shown to have activity in the treatment of malignant gliomas in numerous clinical studies (12–18). The effectiveness of carboplatin is dose-dependent, however, and this drug does not cross the intact blood-brain barrier (BBB) well when administered intravenously.

The BBB disruption (BBBD) procedure is an established strategy to enhance transport of a drug across the BBB. Williams et al have shown that intra-arterial administration with BBBD increases delivery of carboplatin to the tumor, brain around tumor, and brain distant to tumor (19). Moreover, Doolittle et al have reported on the safety of this approach in a multi-institutional setting (20).

We use carboplatin as part of a tridrug regimen in a phase II study on BBBD to enhance delivery of chemotherapy. In this regimen, the carboplatin is administered intra-arterially after osmotic opening of

Received September 23, 2003; accepted after revision January 10, 2004.

From the Departments of Neurosurgery and Neurooncology (D.F., J.S., A.D.) and Radiology (A.D.), CHUS, Sherbrooke, Quebec, Canada.

Address correspondence to David Fortin, MD, CHUS, 3001 12e avenue nord, Sherbrooke, Quebec J1H 5N4.

© American Society of Neuroradiology

the BBB, with the goal of significantly increasing its regional area under the curve, while minimizing streaming (21, 22). In the context of this phase II study, a total of 110 patients with different histologic malignant brain tumors subtypes were exposed to this treatment technique at our institution (23).

In this technical note, we report ocular toxicity in the form of orbital pseudotumor in three patients treated with BBBD and intra-arterial carboplatin. Although treatment was discontinued in the first patient, we designed a simple modification to the procedure that allowed treatment continuation in the two subsequent patients.

### *BBBD Technique and Carboplatin Infusion*

The procedure has been described extensively elsewhere and is conducted in the angiography suite (24). In brief, the patient is placed under general anesthesia. A 5F transfemoral intra-arterial catheter is placed in the parent vessel responsible for most the tumor irrigation (right or left internal carotid artery, dominant vertebral artery). The catheter is placed at the level of C1–C2 for the carotid circulation, and at the level of C5–C6 for the vertebral circulation. Via this catheter, BBBD is performed by the infusion of warmed mannitol (25%) administered at a predetermined flow rate to completely fill the vascular tree for 30 seconds. Five minutes after the completion of the mannitol infusion, intracarotid carboplatin (400 mg/m<sup>2</sup>) is infused at a rate of 0.2 mL/s to limit streaming. The other chemotherapy agents are infused intravenously.

## **Case Reports and Technical Modification**

### *Patient 1*

A 41-year-old white male patient was referred to our center 10 years after having been diagnosed with a temporal low-grade astrocytoma and after undergoing partial resection. The patient was reoperated in August 2000, and a diagnosis of right-sided anaplastic oligodendroglioma was reported. The samples from the first surgery were requested and reanalyzed, and the diagnosis was changed to that of an oligodendroglioma. The patient qualified for BBBD and intra-arterial carboplatin administration and, after giving consent, was enrolled in the phase II study.

The first cycle was well tolerated. Approximately 36–48 hours after the second treatment, upon awakening, he presented a painful swelling of the right orbit, with blurred vision, ptosis, chemosis, and limitation of ocular motility. The examination depicted a visual acuity of 20/200, lid swelling with a complete ptosis, exophthalmia, relative afferent papillary defect, and complete paresis of outward and upward movements of the right eye (Fig 1). Imaging of the orbit with CT demonstrated a right-sided exophthalmia, fat infiltration, swelling of intraorbital muscles and lacrimal gland, confirming the diagnosis of orbital myositis (Fig 2). The patient was treated with a 3-day course of 1 g intravenous solumedrol followed by 100 mg prednisone for 14 days and then gradual weaning. Conjunctival biopsy at day 2 revealed inflammatory changes. Intra-arterial carboplatin was discontinued, and the patient was offered oral temozolomide. On 5-week follow-up, the patient had recovered well. His right eye vision improved to 20/40, color vision was 10/10, and no proptosis or ophthalmoplegia was observed. The patient has discontinued temozolomide after three cycles because of

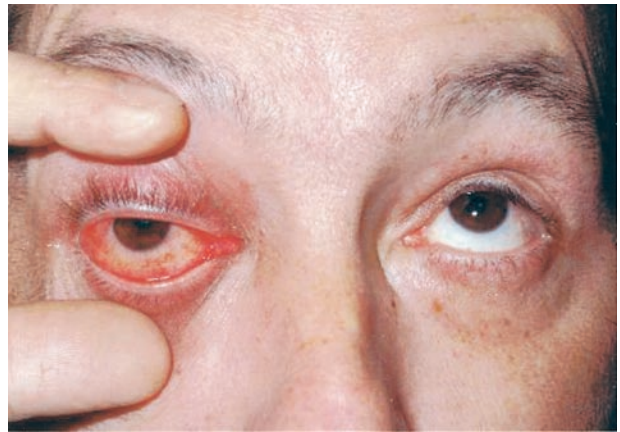

FIG 1. Photograph of patient 1, taken 12 hours after he presented with the first stigmata of the pseudotumor syndrome. Note the exophthalmia, hyperemia, and chemosis of the right eye.

poorly tolerated side effects. The patient is still alive but presents a gradual decline in his neurologic condition.

### *Patient 2 and Technical Modification*

A 67-year-old white female patient with a left frontal metastasis of a B-cell systemic lymphoma was referred to our institution after not responding to radiation therapy and high-dose systemic methotrexate. This patient showed excellent response throughout nine cycles of BBBD and intra-arterial carboplatin. Forty-eight hours after administration of the 9th cycle, she observed a slight swelling of the left eye that eventually progressed to a painful swelling and ptosis. The neurologic examination demonstrated, in addition to the ptosis and swelling of the eyelid, a visual acuity of 20/200 (20/30 right eye), a complete downward paresis, and moderate abduction paresis of the left eye. Brain MR imaging obtained 12 hours after the onset of this syndrome demonstrated a left-sided exophthalmia with swelling and enhancement of all left extraocular muscles (Fig 3). She was treated with steroids and responded equally well.

The excellent response of the frontal metastasis to our therapeutic regimen (Fig 4), combined with the lack of alternatives, prompted us to continue therapy and attempt supraorbital infusion of carboplatin to bypass the emergence of the ophthalmic artery. To do so, the BBBD procedure was performed as described above. After mannitol infusion, and before carboplatin, however, the catheter was changed for a 3.5 tracker and was repositioned just above the emergence of the ophthalmic artery (Fig 5). The patient underwent her 10th and 11th cycles without any ocular adverse events. Two weeks after the 11th cycle, she was admitted in another institution for a sudden onset of severe dyspnea and died of a massive pulmonary embolism.

### *Patient 3*

A 59-year-old female patient, known for a bronchogenic adenocarcinoma, presented with gradual onset of right hemiparesis and hemihypesthesia. Investigation demonstrated the presence of a unique left parietal metastasis. She refused surgery and was enrolled and began treatment with intra-arterial carboplatin and BBBD in May 2002. Two days after the second cycle, she developed orbital swelling and pain. Decadron dosage was increased for 2 weeks, and we observed complete resolution of the symptomatology.

By the same technique of supraorbital catheterization post BBBD, the 3rd–5th cycles were performed without recur-



FIG 2. Axial (A) and coronal (B) CT images, demonstrating the right-sided exophthalmia, fat infiltration, and swelling of intraorbital muscles and lacrimal gland in patient 1. CT was performed 14 hours after the initiation of the pseudotumor syndrome.

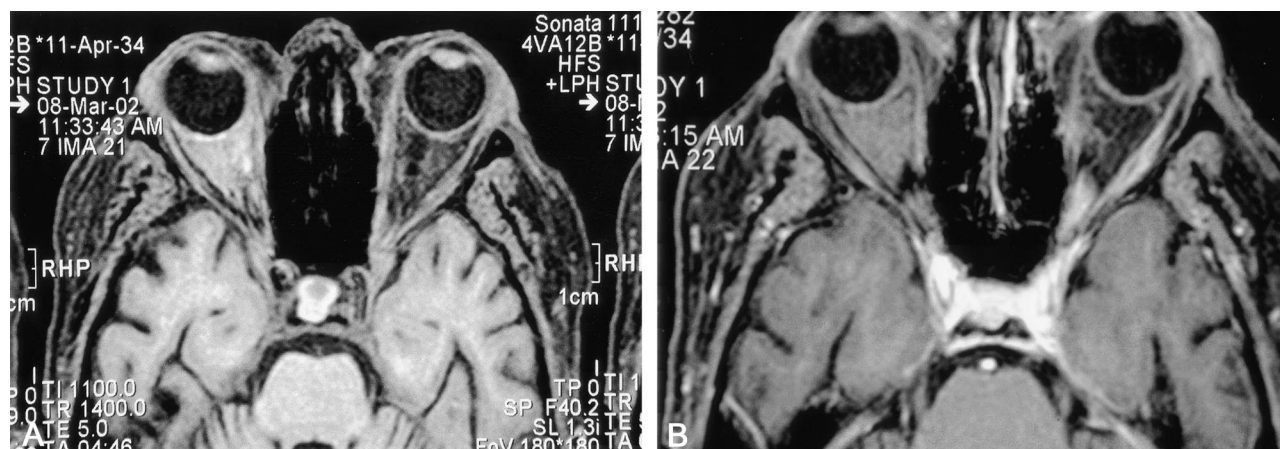
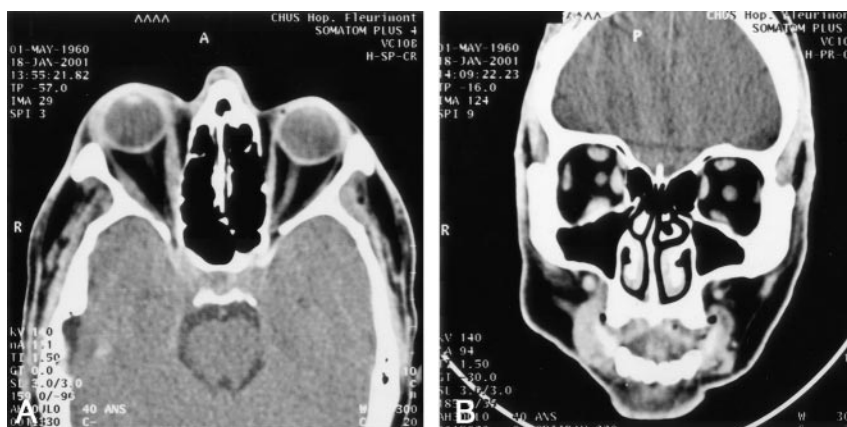


FIG 3. MR characteristics of the pseudotumor syndrome as displayed in patient 2. A, Axial T1-weighted brain MR imaging highlighting the left-sided exophthalmia and swelling of the extraocular muscles. B, Contrast-enhanced T1-weighted MR study in the same patient depicting enhancement of the extraocular muscles of the left orbital cavity.

rence of the orbital myositis. Two days after her 6th cycle, however, signs of ocular toxicity recurred despite the supraorbital injection of carboplatin. The position of the catheter was borderline, and it is presumed that the catheter slipped back below the origin of the ophthalmic artery, although this was not controlled. Treatments were discontinued. The patient presented in the following months a progression of her primary disease and died of respiratory insufficiency in July 2002.

## Discussion

Orbital pseudotumor is an inflammatory condition of one or more extraocular muscles and produces limitation of ocular motility. Many etiologies are responsible for orbital myositis, but rarely has it been associated with chemotherapy. The rapid response of orbital myositis to corticosteroids is almost diagnostic (4). The three patients reported in our series demonstrated significant improvement in the first few days on corticosteroids and almost complete resolution of their symptomatology after 4–9 weeks of treatment.

Intracarotid platinum compounds are widely used to treat a variety of malignant tumors. Numerous studies have established the activity of these molecules in the treatment of malignant brain tumors (12–18). The antineoplastic effects of platinum compounds are exerted through induction of DNA and

RNA alkylation and cytoplasmic proteins modifications.

Intra-arterial administration following BBBB improves delivery of antitumoral drugs to the tumor and the hemisphere involved and allows higher efficiency with less systemic toxicity. Intracarotid administration, however, might be associated with higher ocular and neural toxicity because of the infusion of highly concentrated drugs. Ocular, retinal, and neural toxicity have been described with cisplatin administration and, less commonly, with carboplatin. Supraselective catheterization distal to the ophthalmic artery has been shown to reduce retinal and ocular toxicity associated with cisplatin infusion. Kupersmith et al (6) demonstrated a decrease in ocular toxicity associated with cisplatin or carmustine with supraorbital infusion; however, reports of severe ocular toxicity ipsilateral to a supraorbital infusion of cisplatin with or without nimustine have been outlined by several authors (7, 8).

To conserve its theoretical advantage, the BBBB procedure should be accomplished in a parent vessel, not in a supraselective way. Malignant gliomas are infiltrative lesions, and tumor cells have been identified at a distance from the radiologic abnormalities on MR images and isolated from areas appearing

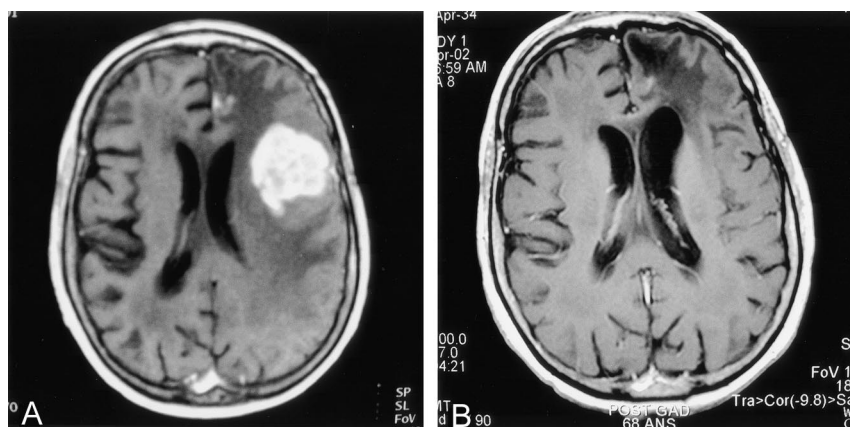


FIG 4. Response obtained in the treatment of a 67-year-old patient with a primary CNS lymphoma (patient 2). Before study accrual, the patient had been treated with high-dose intravenous methotrexate and radiation and had not responded to these modalities. A, Axial T1-weighted brain MR image obtained at study accrual in April 2001. The highly and homogeneously left frontal enhancing lesion is obvious, as well as the surrounding vasogenic edema. A mass effect is produced on the ipsilateral ventricle, as well as on the gyri. B, Axial T1-weighted brain MR image obtained before the 10th cycle, in April 2002. The tumoral nodule has completely receded, and presence of left frontal encephalomalacia and a vacuum effect on the left frontal horn translate the decrease in mass effect.

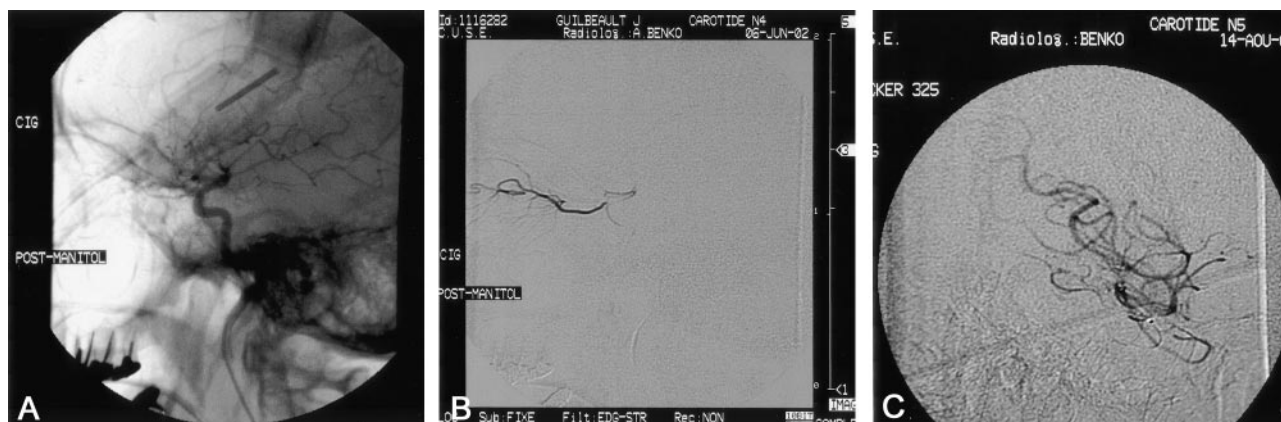


FIG 5. The modified BBBD technique applied in patient 2. The patient had just undergone mannitol infusion. A, The catheter has been changed for a 3.5 microcatheter tracker and a first infusion is accomplished. B, The catheter is moved caudally until the identification of the origin of the ophthalmic artery. C, The catheter is positioned just above the origin of the ophthalmic artery to bypass it. Chemotherapy is infused in a supraorbital setting after the BBB has been disrupted by using the standard infraorbital carotid mannitol infusion.

normal at pathologic examination in brain tumor patients (25). As for metastatic disease, the presence of multiple lesions is not unusual. Thus, the procedure should cover the greatest vascular distribution feasible. The orbital pseudotumor syndrome has never been observed in patients treated with BBBD and intra-arterial methotrexate infusion (26). We therefore concluded that the intra-arterial infusion of mannitol was not directly responsible for the syndrome and that repeated mannitol infusion could safely be accomplished even in patients who presented with the condition. After disruption, the position of a catheter just above the origin of the ophthalmic artery required to change the 5F catheter for a 3.5 tracker, a catheter that would be inappropriate for the infusion of high-flow mannitol, but that is ideal for slow delivery of chemotherapy. Thus, it appeared logical to accomplish disruption and change the catheter for the chemotherapy infusion in a supraorbital fashion. The theoretical risk of using a smaller catheter to infuse chemotherapy involves the possibility of increasing streaming that could, in turn, increase neurotoxicity (22). Nonetheless, by modifying the rate of administration, this risk can be minimized (22).

Patient 3 presented a relapse in her condition after

uneventfully having undergone three additional cycles with supraorbital infusion. Although this is pure speculation, we believe that the catheter, having been placed just above the ophthalmic artery and twice slipping back below before chemotherapy infusion, moved and again fell below during the infusion. The catheter was checked just before the initiation of chemotherapy infusion, but, unfortunately, not thereafter.

Before this report, the occurrence of orbital myositis had always been considered an absolute contraindication to treatment continuation in centers performing intra-arterial chemotherapy and BBBD (20). We believe that this should no longer be considered the case and that the modification to the technique of BBBD described in this report should be considered in these circumstances.

## References

1. Miller NR, Newman NJ. *Walsh & Hoyt's clinical neuro-ophthalmology: the essentials*. 5th edition. Philadelphia: Lippincott, Williams and Wilkins; 1998:677-679
2. Lee MS, Lessell S. **Orbital myositis posing as cluster headache.** *Arch Neurol* 2002;59:635-636

3. Maurer I, Zierz SJ. **Recurrent orbital myositis: report of a familial incidence.** *Arch Neurol* 1999;56:1407-1409
4. Nabili S, McCarey DW, Browne B, Capell HA. **A case of orbital myositis associated with rheumatoid arthritis.** *Ann Rheum Dis* 2002;61:938-939
5. Pollard Z. **Acute rectus muscle palsy in children as a result of orbital myositis.** *J Pediatr* 1996;128:230-233
6. Kupersmith MJ, Frohman LP, Choi IS, et al. **Visual system toxicity following intra-arterial chemotherapy.** *Neurology* 1988;38:284-289
7. Margo CE, Murtagh FR. **Ocular and orbital toxicity after intracranial cisplatin therapy.** *Am J Ophthalmol* 1993;116:508-509
8. Wu HM, Lee AG, Lehane DE et al. **Ocular and orbital complications of intraarterial cisplatin.** *J Neuroophthalmol* 1997;17:195-198
9. O'Dwyer PJ, Stevenson JP, Johnson SW. **Clinical pharmacokinetics and administration of established platinum drugs.** *Drugs* 2000;59(Suppl 4):S19-S27
10. Selvaratnam G, Philips RH, Mohamed AK, Radzi A. **Adverse effects of cytotoxic-platinum agents.** *Adverse Drug React Toxicol Rev* 1997;16:171-197
11. Go RS, Adjei AA. **Review of the comparative pharmacology and clinical activity of cisplatin and carboplatin.** *J Clin Oncol* 1999;17:409-422
12. Yung WKA, Mechtler Laszlo, Gleason MJ. **Intravenous carboplatin for recurrent malignant glioma: a phase II study.** *J Clin Oncol* 1991;9:860-864
13. Twelves CJ, Ash CM, Miles DW, et al. **Activity and toxicity of carboplatin and iproplatin in relapsed high-grade glioma.** *Cancer Chemother Pharmacol* 1991;27:481-483
14. Warnick RE, Prados MD, Mack EE, et al. **A phase II study of intravenous carboplatin for the treatment of recurrent gliomas.** *J Neuro-Oncol* 1994;19:69-74
15. Lunardi P, Farah JO, Mastronardi L, et al. **Intravenous administration of high doses of carboplatin in multimodal treatment of high grade gliomas: a phase II study.** *Acta Neurochirurgica* 1996;138:215-220
16. Prados MD, Warnick RE, Mack EE, et al. **Intravenous carboplatin for recurrent gliomas.** *Am J Clin Oncol* 1996;19:609-612
17. Friedman HS, Shelley L, Rasheed K, Friedman AH. **Treatment of adults with progressive oligodendroglioma with carboplatin (CB-DCA): preliminary results.** *Med Pediatr Oncol* 1998;31:16-18
18. Huncharek M, Kupelnick B, Bishop D. **Platinum analogues in the treatment of recurrent high grade astrocytoma.** *Cancer Treat Rev* 1998;24:307-316
19. Williams PC, Henner WD, Roman-Goldstein S, et al. **Toxicity and efficacy of carboplatin and etoposide in conjunction with disruption of the blood-brain tumor barrier in the treatment of intracranial neoplasms.** *Neurosurgery* 1995;37:17-27
20. Doolittle ND, Miner ME, Hall WA, et al. **Safety and efficacy of a multicenter study using intraarterial chemotherapy in conjunction with osmotic opening of the blood-brain barrier for the treatment of patients with malignant brain tumors.** *Cancer* 2000;88:637-647
21. Kroll RA, Neuwelt EA. **Outwitting the blood-brain barrier for therapeutic purposes: osmotic opening and other means.** *Neurosurgery* 1998;42:1083-1100
22. Fortin D, McAllister LD, Nesbit G, et al. **Unusual cervical spine cord toxicity associated with intra-arterial carboplatin, intra-arterial or intravenous etoposide phosphate, and intravenous cyclophosphamide with osmotic blood brain-barrier disruption in the vertebral artery.** *AJNR Am J Neuroradiol* 1999;20:1794-1802
23. Desjardins A, Boudrias M, Fortin D. **Osmotic blood-brain barrier disruption to enhance chemotherapy delivery in the treatment of brain tumors: the Sherbrooke experience. A-07.** *Can J Neurol Sci* 2002;(Suppl 1):S9
24. Fortin D, Neuwelt EA. *Therapeutic Manipulation of the Blood-Brain Barrier: Neurobase-Neurosurgery.* 1st ed. San Diego: Medlink Neurology; 2002
25. Silbergeld DL, Chicoine MR. **Isolation and characterization of human malignant glioma cells from histologically normal brain.** *J Neurosurg* 1997;86:525-531
26. McAllister LD, Doolittle ND, Guastadisegni PE, et al. **Cognitive outcomes and long-term follow-up results after enhanced chemotherapy delivery for primary central nervous system lymphoma.** *Neurosurgery* 2000;46:51-61