



Get Clarity On Generics

Cost-Effective CT & MRI Contrast Agents



FRESENIUS
KABI

WATCH VIDEO

AJNR

Efficacy of Endovascular Surgery for the Treatment of Acute Epidural Hematomas

Sachio Suzuki, Masataka Endo, Akira Kurata, Taketomo Ohmomo, Hidehiro Oka, Takao Kitahara, Takashi Ohwada, Satoshi Utsuki and Kiyotaka Fujii

This information is current as of August 8, 2025.

AJNR Am J Neuroradiol 2004, 25 (7) 1177-1180

<http://www.ajnr.org/content/25/7/1177>

Efficacy of Endovascular Surgery for the Treatment of Acute Epidural Hematomas

Sachio Suzuki, Masataka Endo, Akira Kurata, Taketomo Ohmomo, Hidehiro Oka, Takao Kitahara, Takashi Ohwada, Satoshi Utsuki, and Kiyotaka Fujii

BACKGROUND AND PURPOSE: Recent advances in the equipment and technology for endovascular surgery have led to an increasing number of patients undergoing this procedure to treat various lesions. The purpose of this study was to investigate the efficacy of early-stage endovascular surgery to treat growing acute epidural hematomas (AEDHs).

METHODS: Over a period of 2.5 years, endovascular intervention was performed in nine patients with AEDHs, as shown by the extravasation of contrast medium and the recognition of growing hematomas on CT scans. Embolization was performed by using catheters superselectively advanced with a microguidewire until it reached the area just before the bleeding point.

RESULTS: In all nine cases, bleeding from the middle meningeal artery ceased immediately after treatment, and further surgical intervention was avoided. In three of five patients with additional lesions, surgical intervention was also conducted to treat an acute subdural hematoma (two patients) or a contusion hematoma (one patient); in two cases, these lesions were located on the contralateral side.

CONCLUSION: In patients with thin AEDHs in the early stage, angiography followed by endovascular intervention allows for conservative treatment. Notable clinical benefits can be achieved in patients with complicated, multiple lesions.

Recent advances in the equipment and technology for endovascular surgery have led to an increasing number of patients undergoing this procedure to treat various lesions. However, few published reports have described its use in trauma involving craniofacial lesions (1). Treatment is used to stop intractable bleeding (except in cases of traumatic carotid cavernous fistulas and pseudoaneurysms) (2–5). The purpose of our study was to evaluate the efficacy of endovascular surgery for patients with acute epidural hematomas (AEDHs).

Methods

Between May 1999 and December 2001, nine patients with AEDHs underwent endovascular surgery at our institution. The Table summarizes details in the nine patients, who included eight men and one woman (age range, 18–62 years; mean, 37.7 years). None of the patients had local neurologic deficits. In seven, contrast-enhanced CT demonstrated persis-

tent bleeding. In four patients who were referred from local clinics, repeat CT scans showed remarkable hematoma growth. In all cases, active bleeding from the middle meningeal artery (MMA), as defined by angiography, was treated by means of embolization of the bleeding point. In five cases, traumatic subarachnoid hemorrhage, brain contusions, and acute subdural hematomas were also present. The mean time from trauma to the patients' admission to our emergency center was 94 minutes (range, 40–240 minutes). The mean time from trauma to embolization was 2.1 hours (range, 1.5–2.8 hours). Embolization was performed by using Microferret catheters (Cook, Inc, Bloomington, IN) that were superselectively advanced with a microguidewire until they reached an area just before the bleeding point. Platinum balls (150–200 μ m in diameter) and microfibrillary collagen (Aviten, Davol Inc., Cranston, RI) were used as embolic materials. The mean time for embolization was 39.3 minutes (range, 25–53 minutes).

Results

In all nine patients, embolization was successful, without complications, and bleeding was stopped immediately. Follow-up CT scans obtained after treatment did not show any increase in the hematomas (Fig 1). All of the lesions were followed conservatively without surgical intervention and disappeared within an average of 18 days (range, 4–29 days). Surgical intervention was performed in three of five patients with other lesions. This involved removal of acute subdural hematomas in two and a persistent contusion hematoma in one; two of these lesions were

Received May 6, 2002; accepted after revision April 29, 2004.

From the Departments of Neurosurgery (S.S., A.K., T.O., H.O., S.U., K.F.) and Critical Care Medicine (M.E., T.K., T.O.), Kitasato University School of Medicine, Kanagawa, Japan.

Supported by the Marine and Fire Insurance Association of Japan, Inc., Tokyo, Japan.

Address reprint requests to Sachio Suzuki, MD, Department of Neurosurgery, Kitasato University School of Medicine, 1-15-1 Kitasato, Sagami-hara, Kanagawa, 228-8555, Japan.

Summary details for the nine patients

Patient/Age (years)/Sex	Intracranial Injury on CT	Hematoma Enhancement	Hematoma Thickness (mm)	Time to Treatment End (hours)
1/32/M	AEDH	NA	20	3
2/18/M	AEDH, ASDH, tICH, tSAH	Yes	11	2.5
3/62/M*	AEDH, tSAH	Yes	9.8	2.3
4/28/M	AEDH, ASDH, tSAH	Yes	9.3	2.8
5/54/M	AEDH	NA	16	2.1
6/34/M	AEDH	Yes	16	2.7
7/33/F	AEDH, tICH, tSAH	Yes	8.5	1.5
8/18/M	AEDH, contusion	Yes	15	1.5
9/60/M	AEDH	Yes	16	1.75

Note.—In all patients, images showed extravasation and no enlargement of the hematoma after embolization. ASDH indicates acute subdural hematoma; tICH, traumatic intracerebral hematoma; NA, not applicable; and tSAH, traumatic subarachnoid hemorrhage.

* Patient 3 also had a fracture of the legs and a lung contusion.

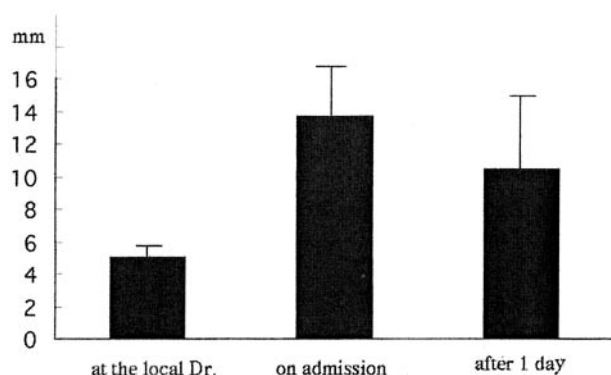


FIG 1. Plot shows changes in hematoma thickness in nine patients, as determined during CT at admission and postembolization follow-up.

located on the contralateral side. The average period until discharge was 27.9 days (range, 5–70 days) for all patients and 6.7 days (range, 5–8 days) for the four patients with only AEDHs.

Representative Cases

Case 5

A 54-year-old man was injured in a traffic accident and immediately transported from a local doctor's facility to our emergency center. On admission, the patient was free of neurologic symptoms. Radiographs showed a linear fracture of the right temporal bone, and nonenhanced CT scans revealed growth of an AEDH adjacent to the fracture (Fig 2A and B).

Emergency angiography demonstrated active extravasation from the MMA (Fig 2C), which was stopped immediately with embolization. CT scans acquired after treatment showed no change in the hematoma, and follow-up CT performed 20 days after treatment showed that the lesion completely disappeared (Fig 2D).

Case 7

A 33-year-old woman was injured in a traffic accident and immediately transported to our emergency center. On admission, she had mildly disturbed con-

sciousness without local neurologic symptoms. Radiographs showed a linear fracture of the left temporal bone, and nonenhanced CT scans revealed a thin AEDH adjacent to the fracture (Fig 3A). Contrast-enhanced CT scans showed extravasation of contrast medium (Fig 3B); this was confirmed by findings on emergency angiograms (Fig 3C and D). The bleeding stopped immediately after embolization (Fig 3E); however, surgical intervention was needed to treat a contralateral subdural hematoma and a contusional hematoma (Fig 3F). Follow-up CT scans obtained 1 day after the surgical intervention showed no change in the epidural hematoma.

Discussion

Endovascular surgery has been widely used for the treatment of various craniofacial lesions. In patients with trauma, this surgery has been applied to treat mainly traumatic carotid cavernous fistulas, pseudoaneurysms, and intractable bleeding (1–5). To our knowledge, no reports of the efficacy of endovascular surgery for AEDHs have been published.

Emergency surgical intervention is always the first-choice strategy for patients with AEDH (6–8). However, it may be avoided in those without local neurologic deficits in the very early stage of the lesion. Knuckey et al (7) reported that six (43%) of 14 patients undergoing CT within 6 hours of trauma subsequently required evacuation of the epidural hematoma. Five (83%) underwent hematoma removal within 24 hours, and one (17%) was treated within 3 days after trauma. In contrast, only one (13%) of eight patients undergoing CT after more than 6 hours subsequently required evacuation of the epidural hematoma.

Sakai et al (9) reported that small epidural hematomas became enlarged in 24 (65%) of 37 patients within 22 hours after trauma; the lesions attained a maximum thickness of 25 mm or greater in 19 patients (51%). Subsequently, 68% of these patients had a disturbance in consciousness.

According to these reports, surgical evacuation of the hematoma is needed in many cases involving small hematomas in the early stages. In all of our patients, extravasation of contrast medium was evi-

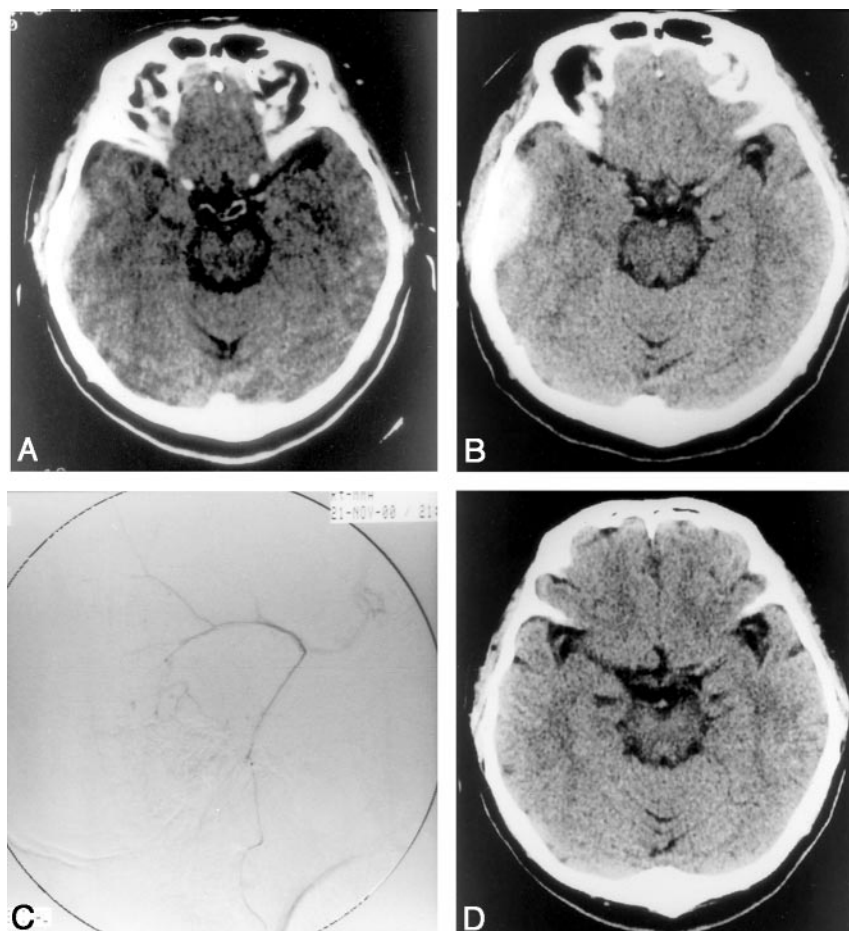


FIG 2. Case 5.

A, First CT scan obtained outside our institution shows an epidural hematoma in the right hemisphere.

B, Second CT scan, obtained at admission, shows that the hematoma has grown.

C, Superselective arteriogram of the right MMA demonstrates extravasation of contrast medium.

D, Follow-up CT scan obtained 20 days after embolization shows disappearance of the hematoma.

dent at angiography. Hematomas depicted on contrast-enhanced CT scans represent bleeding in real time, and this study is therefore effective for identifying which patients need embolization. In the present series, bleeding from the MMA immediately ceased after endovascular surgery, and no complications occurred; all patients had an uneventful clinical course. Therefore, emergency embolization to manage bleeding from the MMA was a useful technique for these patients with AEDH.

The advantage of this technique was especially apparent with bilateral brain injuries, as in Case 7, or whole-body injuries, as in Case 3. However, surgical intervention to AEDH might adversely affect a contralateral hematoma and might aggravate cardiopulmonary dysfunction. Still, endovascular surgery is noninvasive and can be performed quickly. With our patients, embolization required an average of only 39.3 minutes. Therefore, it is an effective and appropriate choice for a case of AEDH with multiple injuries, in the early stages. The main disadvantage was lag time before the patients' arrival at our medical center. The period from injury to the completion of treatment was an average of 2.5 hours in our series (range, 1.5–4 hours). The time to discharge was 6.7 days on average for the four patients with only AEDH. As an additional benefit, this treatment also has cost benefits compared with conventional surgical intervention.

Conclusion

Angiography followed by endovascular intervention may be an effective treatment for patients with early-stage AEDH, when CT scans show extravasation of contrast medium suggestive of hematoma growth.

References

1. Kurata A, Kitahara T, Miyasaka Y, et al. **Superselective embolization for severe traumatic epistaxis caused by fracture of the skull base.** *AJNR Am J Neuroradiol* 1993;14:343–345
2. Hemphill JC III, Gress DR, Halbach VV. **Endovascular therapy of traumatic injuries of the intracranial cerebral arteries.** *Crit Care Clin* 1999;15:811–829
3. Horowitz MB, Kopitnik TA, Landreneau F, et al. **Multidisciplinary approach to traumatic intracranial aneurysms secondary to shotgun and handgun wounds.** *Surg Neurol* 1999;51:31–41
4. Ng SH, Wan YL, Ko SF, et al. **Bilateral traumatic carotid-cavernous fistulas successfully treated by detachable balloon technique.** *J Trauma Inj Infect Crit Care* 1999;47:1156–1159
5. Wadlington VR, Terry JB. **Endovascular therapy of traumatic carotid-cavernous fistulas.** *Crit Care Clin* 1999;15:831–854
6. Cucciniello B, Martellotta N, Nigro D, et al. **Conservative management of extradural hematomas.** *Acta Neurochir (Wien)* 1993;120:47–52
7. Kunckey NW, Gelbard S, Epstein MH. **The management of asymptomatic epidural hematoma.** *J Neurosurg* 1989;70:392–396
8. Sagher O, Ribas GC, Jane JA. **Nonoperative management of acute epidural hematoma diagnosed by CT: the neuroradiologist's role.** *AJNR Am J Neuroradiol* 1992;13:860–862
9. Sakai H, Takagi H, Yada K, et al. **Serial changes in acute extradural hematoma size and associated changes in level of consciousness and intracranial pressure.** *J Neurosurg* 1988;68:566–570

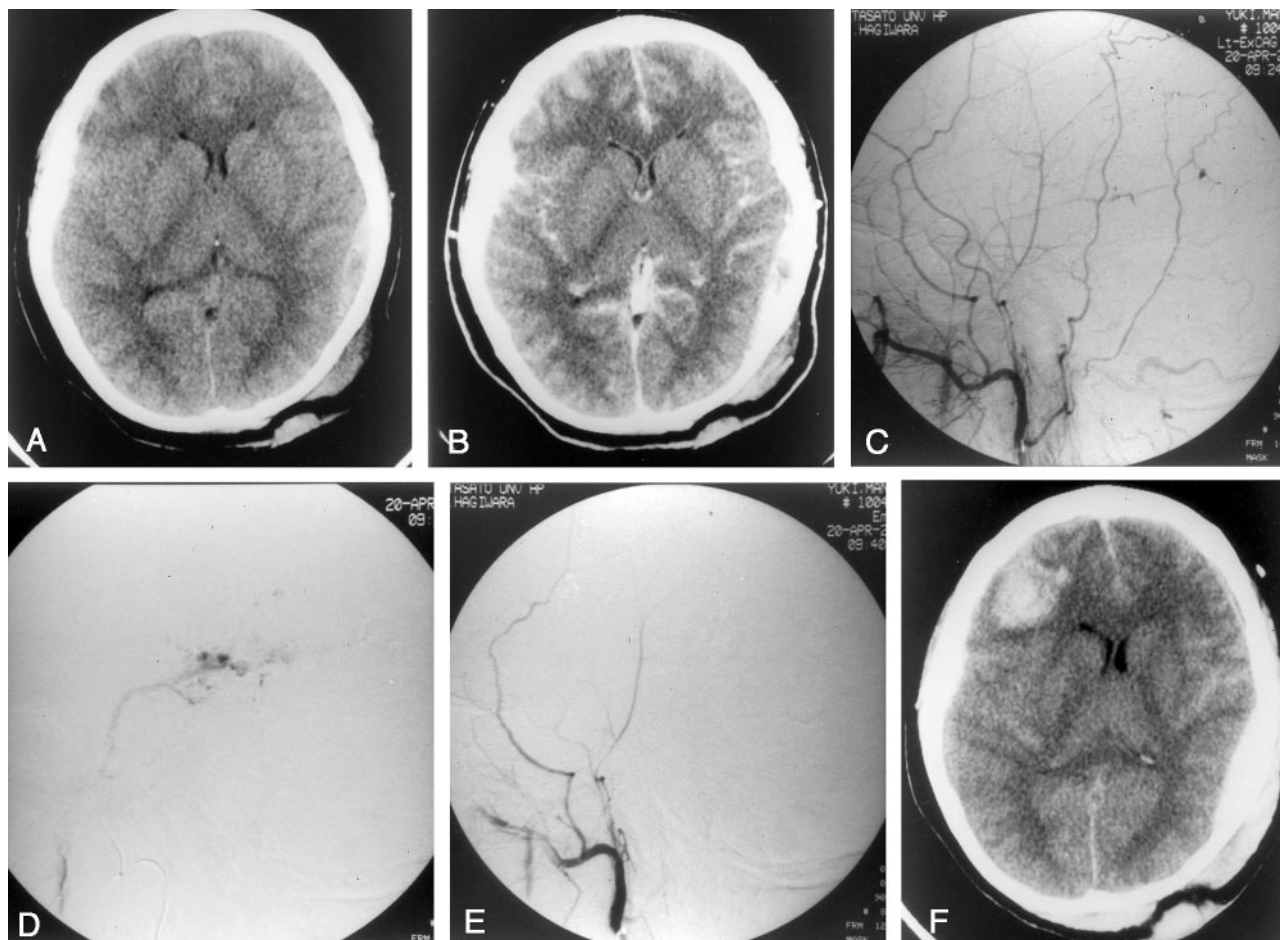


FIG 3. Case 7.

A, CT scan demonstrates an epidural hematoma on the left side and a contusion of the right frontal lobe.

B, Enhanced CT scan shows extravasation of contrast medium.

C-E, Superselective angiograms of the left external carotid artery and left MMA before (C, D) and after (E) embolization.

F, CT scan obtained immediately after embolization shows enlargement of the contusion hematoma of the right frontal lobe and no change in the epidural hematoma on the left side.