



## Get Clarity On Generics

Cost-Effective CT & MRI Contrast Agents



FRESENIUS  
KABI

WATCH VIDEO

# AJNR

## Giant Cell Reparative Granuloma of the Nasal Cavity

Jonathan M. Morris, John I. Lane, Robert J. Witte and Dana M. Thompson

*AJNR Am J Neuroradiol* 2004, 25 (7) 1263-1265

<http://www.ajnr.org/content/25/7/1263>

This information is current as of August 13, 2025.

# Giant Cell Reparative Granuloma of the Nasal Cavity

Jonathan M. Morris, John I. Lane, Robert J. Witte, and Dana M. Thompson

**Summary:** We report an unusual case of giant cell reparative granuloma (GCRG) arising in the nasal cavity of a 7-year-old girl. GCRG is an uncommon benign lesion that is most commonly found in the mandible and maxilla. The MR imaging and CT findings of this lesion, as well as GCRGs in other craniofacial bones and extragnathic sites, will be reviewed. Although rare, the imaging characteristics of GCRGs should be recognized, and this entity should be suggested when the clinical information, CT, and MR features suggest a fibrous-osseous lesion in the nasal cavity.

In 1953, Jaffe (1) first described giant cell reparative granuloma (GCRG) as a benign lesion affecting the mandible and maxilla, which was a reactive response to intraosseous hemorrhage. The term *giant cell granuloma* (GCG) has also been introduced to account for the lack of pre-existing trauma or reparative tissue in some of these lesions (2–4). Although this lesion is most frequently seen in the mandible and maxilla, it has rarely been described to involve other extragnathic sites: the small bones of the hands and feet (5), the long tubular bones (6), the paranasal sinuses (7, 8), the orbit (9), and the cranial vault (10). In the English-language literature, there is a paucity of documented advanced imaging characteristics of GCRGs involving the cranial facial bones or paranasal sinuses, and to the best of our knowledge GCRG of the nasal cavity has not been reported. We report an unusual case of GCRG arising in the nasal cavity of a 7-year-old girl in which imaging (CT and MR) and pathologic correlation was made.

## Case Reports

A 7-year-old girl presented to the Mayo Clinic (Rochester, MN) with a chief complaint of new-onset diplopia, right-sided clear nasal discharge, right-sided epiphora, and bizarre and increasingly violent behavior toward her parents. On further questioning, the parents noted that she also had a 1-year history of daytime somnolence, apneic episodes at night, and loud snoring. Of note, a CT scan from an outside institution showed a nasal mass.

Received October 14, 2003; accepted after revision December 19.

From the Departments of Radiology (J.M.M.), Neuroradiology (J.I.L., R.J.W.), and Otorhinolaryngology (D.M.T.), Mayo Clinic, Rochester, MN.

Address correspondence to Jonathan M. Morris, M.D., Department of Radiology, The Mayo Clinic, 200 First Street SW, Rochester, MN 55905.

© American Society of Neuroradiology

On physical examination, anterior rhinoscopy, and flexible nasopharyngoscopy, a pale obstructing mass abutting the nasal septum was seen in the right nares, with a profuse clear watery discharge. She underwent CT and MR imaging studies of the brain and sinuses to determine the extent of the lesion and to see whether the mass extended intracranially. An axial CT scan with coronal reformats showed fluid-fluid levels in a heterogeneous mass centered at the inferior turbinate and extending from the nares to the choanae with no intracranial communication (Fig 1A). There was medial displacement of the nasal septum and lateral displacement of the medial wall of the maxillary sinus without any associated cortical destruction, findings that suggest a longstanding benign lesion. B-2 transferrin studies of the nasal discharge were negative for CSF leak, which further supported the lack of intracranial extension. The MR imaging study showed heterogeneous signal intensity on coronal T1- and coronal and axial T2-weighted images with cystic components and fluid-fluid levels (Fig 1B-D). The soft tissue component and the septa of the lesion enhanced on axial T1-weighted images after gadolinium administration (Fig 1E). None of the more ominous diagnoses that one would consider in a child with a nasal mass such as an encephalocele, nasal glioma, hemangioma, or a dermoid cyst was supported by the imaging characteristics.

Endoscopic biopsy and excision of the mass was performed by using a Takahashi forceps and sinus shaver. To completely excise the mass from the nasal cavity, the middle turbinate and posterior aspect of the inferior turbinate had to be removed.

Histopathologic examination revealed a granulomatous lesion with reactive giant cells on a background stroma of plump spindle-shaped fibroblasts. The pathologic diagnosis was GCRG of the nasal cavity. The patient was free of recurrence at 6-month follow-up, and her sleep disturbances had been relieved.

## Discussion

GCRGs are classified in bone as either central or peripheral. Central lesions have a bony covering, and peripheral lesions are those with a soft tissue component and bony resorption, such as those involving the soft tissues of the jaw and gingiva. These are rare benign lesions of controversial pathogenesis, although the most commonly accepted theory is that there is a reactive response to intraosseous hemorrhage secondary to either trauma or, as is possible in our case, chronic inflammation (1, 7, 8, 11).

Clinically, GCTs are usually seen in the 3rd and 4th decade of life but are rarely seen in patients younger than 20 years. In GCRGs, there is a slight female predominance, and although they have been reported in all ages, they typically occur before the age of 30 years (2). The giant cells in GCT are uniformly distributed, more rounded, and are larger, as opposed to the giant cells in GCRGs, which are gathered around hemorrhagic foci, irregularly shaped, and smaller

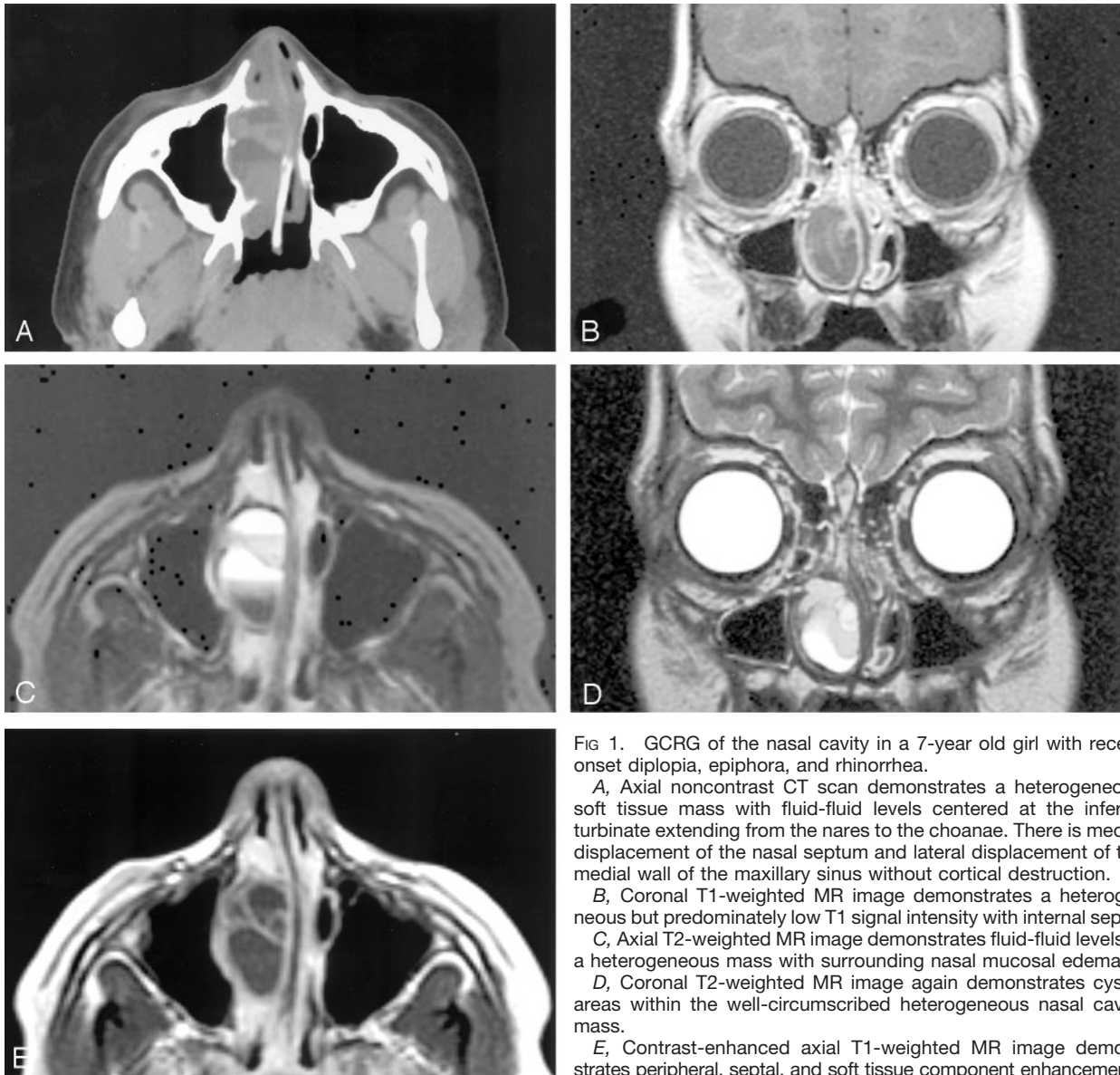


FIG 1. GCRG of the nasal cavity in a 7-year old girl with recent onset diplopia, epiphora, and rhinorrhea.

A, Axial noncontrast CT scan demonstrates a heterogeneous soft tissue mass with fluid-fluid levels centered at the inferior turbinate extending from the nares to the choanae. There is medial displacement of the nasal septum and lateral displacement of the medial wall of the maxillary sinus without cortical destruction.

B, Coronal T1-weighted MR image demonstrates a heterogeneous but predominately low T1 signal intensity with internal septa.

C, Axial T2-weighted MR image demonstrates fluid-fluid levels in a heterogeneous mass with surrounding nasal mucosal edema.

D, Coronal T2-weighted MR image again demonstrates cystic areas within the well-circumscribed heterogeneous nasal cavity mass.

E, Contrast-enhanced axial T1-weighted MR image demonstrates peripheral, septal, and soft tissue component enhancement.

(12). There is evidence of recent and remote hemorrhage in GCRGs with new osteoid formation, whereas in GCT there is limited fresh hemorrhage despite its rich vascularity and no osteoid formation (5, 12). GCRG has a benign clinical course, although it can be locally aggressive, whereas GCT has a more malignant course, higher rate of recurrence, and is reported to metastasize (4).

Radiographic manifestations of GCRGs are non-specific. Gnathic GCRGs demonstrate expansile remodeling of the bone and multilocular appearance (2). The radiographic appearance is indistinguishable from that of an odontogenic cyst, aneurysmal bone cysts (ABC), brown tumor of hyperparathyroidism, ameloblastoma, odontogenic myxoma, and odontogenic fibroma. ABCs are non-neoplastic primary or secondary lesions that most commonly occur in the long bones and vertebral column with involvement of the facial bones being quite rare. Radiographically they are eccentric, expansile lucencies commonly seen

with fluid-fluid levels. The brown tumor of hyperparathyroidism has no pathognomic radiographic or histologic features and is differentiated clinically by elevated calcium and depressed serum phosphate.

GCRGs in the small bones of the hand and feet most commonly appear as lysis with expansile remodeling and no periosteal reaction (5). MR imaging shows these lesions to be heterogeneous on T1- and T2-weighted images with marrow replacement, expansile remodeling, and enhancement of the soft tissue component (4). The cortex in both of these locations is thin but usually intact.

There is a paucity of advanced imaging characteristics of GCRG in the paranasal sinuses and orbit. In the paranasal sinuses, radiographs and CT scans suggest a longstanding process with expansion of the bone and cortical thinning (7). There is usually opacification of the affected sinus due to the soft tissue component of the mass. On CT scans, they appear as heterogeneous soft tissue masses with occasional

hemorrhagic or cystic foci (7, 8), as our case did. In this location, GCRGs can also appear quite aggressive with bony destruction through either the ethmoid or sphenoid bone, involving the clivus or cribriform plate, and extending intracranially (7, 8). CT findings in the orbit have been described as a heterogeneous soft tissue mass with bowing and thinning of the adjacent sphenoid bone and lateral orbital walls. MR imaging in this location demonstrates a well-circumscribed intraosseous cystic mass with internal hemorrhage and fluid-fluid levels (9) as was also seen in our case. The skull base and temporal bone GCRG MR imaging findings are similar to those in our case; namely, a heterogeneous but overall low T1 signal intensity and low to increased T2 signal intensity (depending on the amount of hemosiderin deposition in the lesion) with enhancement of the soft tissue and septal components (10).

Pathologically, the differential diagnoses for giant cell lesions in bone include giant cell tumor, brown tumor of hyperparathyroidism (osteitis fibrosa cystica), and ABCs. The histologic differentiation between GCTs and GCRGs is not always obvious, and when differentiating between the giant cell fibrous-osseous lesions, one must consider the clinical data, lesion location, and histopathologic, radiographic, and surgical data together. Because there is a lack of distinguishing radiographic characteristics for GCRGs, biopsies are usually necessary to confirm the diagnosis.

Most physicians are in agreement that surgical excision and debulking are the standard treatment, with radiation being reserved for inoperable or recurrent cases. Surgical excision is recommended over simple curettage because of the higher risk of recurrence without complete excision (4, 12).

### Conclusion

GCRG is an uncommon benign lesion that has been reported in many extragnathic sites but is most commonly found in the mandible and maxilla. We present an unusual case involving the nasal cavity without in-

volvement of the adjacent sinuses. Although the imaging findings of GCRG are varied and nonspecific in the head and neck, the diagnosis should be considered when a heterogeneous mass with fluid-fluid levels is seen in the craniofacial bones of a younger patient. This case again demonstrates that the diagnosis of fibrous-osseous lesions in this and other locations is reached only through the combined clinical, radiographic, surgical, and histologic data.

### References

1. Jaffe HL. Giant-cell reparative granuloma, traumatic bone cyst, and fibrous (fibro-osseous) dysplasia of the jawbones. *J Oral Surg (Chicago)* 1953;6:159-175
2. Waldron CA, Shafer WG. The central giant cell reparative granuloma of the jaws: an analysis of 38 cases. *Am J Clin Pathol* 1966;45:437-447
3. Ackerman LV, Fechtner RE. *Atlas of Tumor Pathology: Tumors of Bone and Cartilage, Fascicle 5, Section 2*. Washington, DC: Armed Forces Institute of Pathology; 1962:293-314
4. Murphey MD, Nomikos GC, Flemming DJ, et al. From the archives of AFIP: imaging of giant cell tumor and giant cell reparative granuloma of bone: radiologic-pathologic correlation. *Radiographics* 2001;21:1283-1309
5. Lorenzo JC, Dorfman HD. Giant-cell reparative granuloma of short tubular bones of the hands and feet. *Am J Surg Pathol* 1980;4:551-563
6. Wold LE, Dobyns JH, Sweet RG, Dahlin DC. Giant cell reaction (giant cell reparative granuloma) of the small bones of the hands and feet. *Am J Surg Pathol* 1986;10:491-496
7. Oda Y, Tsuneyoshi M, Shinohara N. "Solid" variant of aneurysmal bone cyst (extragnathic giant cell reparative granuloma) in the axial skeleton and long bones: a study of its morphologic spectrum and distinction from allied giant cell lesions. *Cancer* 1992;70:2642-2649
8. Ilaslan H, Sundaram M, Unni KK. Solid variant of aneurysmal bone cysts in long tubular bones: giant cell reparative granuloma. *AJR Am J Roentgenol* 2003;180:1681-1687
9. Rhea JT, Weber AL. Giant-cell granuloma of the sinuses. *Radiology* 1983;147:135-137
10. Wiatrak BJ, Gluckman JL, Fabian RL, et al. Giant cell reparative granuloma of the ethmoid sinus. *Otolaryngol Head Neck Surg* 1987;97:504-509
11. Hoopes PC, Anderson RL, Blodi FC. Giant cell (reparative) granuloma of the orbit. *Ophthalmology* 1981;88:1361-1366
12. Nemoto Y, Inoue Y, Tashiro T, et al. Central giant cell granuloma of the temporal bone. *AJNR Am J Neuroradiol* 1995;16:982-985
13. Santos-Briz A, Lobato RD, Ramos A, et al. Giant cell reparative granuloma of the occipital bone. *Skeletal Radiol* 2003;32:151-155