



Get Clarity On Generics

Cost-Effective CT & MRI Contrast Agents



FRESENIUS
KABI

WATCH VIDEO

AJNR

Factors Predictive of Cerebral Hyperperfusion after Carotid Angioplasty and Stent Placement

Yasuhiko Kaku, Shin-ichi Yoshimura and Jouji Kokuzawa

AJNR Am J Neuroradiol 2004, 25 (8) 1403-1408

<http://www.ajnr.org/content/25/8/1403>

This information is current as of August 17, 2025.

Factors Predictive of Cerebral Hyperperfusion after Carotid Angioplasty and Stent Placement

Yasuhiko Kaku, Shin-ichi Yoshimura, and Jouji Kokuzawa

BACKGROUND AND PURPOSE: Cerebral hyperperfusion syndrome has been increasingly reported as a complication of carotid angioplasty and stent placement. The aim of the present study was to determine significant predictors of hyperperfusion phenomenon after carotid angioplasty and stent placement.

METHODS: We retrospectively reviewed 30 consecutive patients with unilateral severe carotid stenosis who underwent angioplasty and stent placement. Resting cerebral blood flow (CBF) and cerebral vasoreactivity (CVR) to acetazolamide challenge were quantitatively measured to evaluate cerebral hemodynamic reserve. Split-dose [^{123}I] iodoamphetamine single photon emission CT (SPECT) was performed before and 7 days after carotid angioplasty and stent placement. Technetium-99m hexamethylpropyleneamine oxime (HMPAO) SPECT was performed immediately after the procedure.

RESULTS: Three patients had cerebral hyperperfusion phenomenon immediately after angioplasty and stent placement, as shown by HMPAO SPECT: One developed status epilepticus 2 weeks after the procedure. Significant predictors of hyperperfusion included patient age, pretreatment CVR, and pretreatment asymmetry index ([ipsilateral resting CBF/contralateral resting CBF] \times 100). Variables determined not to be significant risk factors included pretreatment resting CBF value, degree of carotid stenosis, and interval from the onset of ischemic symptoms.

CONCLUSION: Significant predictors of hyperperfusion phenomenon after carotid angioplasty and stent placement included patient age, pretreatment CVR, and pretreatment asymmetry index. Pretreatment CBF measurements, including those obtained by quantifying CVR and performing SPECT immediately after the procedure may aid in identifying patients at risk and in initiating careful monitoring and control of blood pressure to prevent hyperperfusion syndrome.

Percutaneous transluminal angioplasty and stent placement are considered less invasive than carotid endarterectomy (CEA) for treatment of carotid stenosis, and they may provide an alternative to CEA, especially in patients deemed to be at increased risk for endarterectomy. Data on the benefits, risks, and complications of carotid angioplasty and stent placement are accumulating (1–3); documented complications include cerebral embolism, vessel dissection, hemodynamic compromise, and cerebral hyperperfu-

sion syndrome. Cerebral hyperperfusion syndrome has been increasingly reported as a complication of carotid angioplasty and stent placement (4–6). However, the incidence of cerebral hyperperfusion after endovascular revascularization procedures of the extracranial carotid artery remains unclear. Few studies have been conducted to evaluate the incidence of hyperperfusion syndrome after carotid angioplasty and stent placement, whereas cerebral hyperperfusion syndrome is a recognized complication of CEA, with a reported incidence of 0.3–1.2% (7–9). Results of several studies indicate that the prevalence of hyperperfusion syndrome after carotid angioplasty and stent placement may be greater than that of hyperperfusion syndrome after CEA (10, 11). Because cerebral hyperperfusion syndrome is associated with substantial morbidity and mortality, factors predictive of cerebral hyperperfusion after carotid angioplasty and stent placement must be identified to prevent

Received October 31, 2003; accepted after revision January 15, 2004.

From the Department of Neurosurgery, Asahi University Murakami Memorial Hospital (Y.K.), and the Department of Neurosurgery, Gifu University School of Medicine (S.Y., J.K.), Japan.

Address reprint requests to Yasuhiko Kaku, MD, Department of Neurosurgery, Asahi University Murakami Memorial Hospital Hashimotochou 3–23, Gifu 500-8523, Japan.

reperfusion injury. The aim of the present study was to determine significant predictors of hyperperfusion after carotid angioplasty and stent placement. To our knowledge, there have been no previous studies of the predicting factors of cerebral hyperperfusion after carotid angioplasty and stent placement.

Methods

Patient Population

Between January 2001 and September 2003, 42 consecutive patients underwent carotid angioplasty and stent placement at the University Hospital of Gifu, Japan. We retrospectively reviewed 30 consecutive patients with unilateral severe carotid stenosis who underwent angioplasty and stent placement. The remaining 12 patients, who had bilateral carotid lesions, were excluded. Twenty-seven of the 30 patients were male, and three were female. Their mean age (\pm SD) was 67.9 ± 8.1 years, and their ages ranged from 51 to 83 years. Twenty patients were hypertensive, and four had diabetes mellitus. In 21 subjects, carotid stenoses were associated with transient ischemic attacks, and nine of the subjects had minor completed strokes. All nine patients with stroke had a favorable functional recovery (modified Rankin disability score of 0, 1, or 2).

Preoperative MR imaging findings were as follows: no signs of infarction in eight patients, watershed-type infarction in five, cortical infarction (territory of the middle cerebral artery [MCA]) in five, lacunar infarctions in 10, and diffuse white matter lesions in two. All patients underwent preoperative angiography. Percentages of stenosis ranged from 70–99% ($93.97\% \pm 6.95$), according to the North American Symptomatic Carotid Endarterectomy Trial (NASCET) criteria.

Cerebral Blood Flow Studies

Split-Dose [^{123}I]Iodoamphetamine Single Photon Emission CT.—Resting cerebral blood flow (CBF) and cerebral vasoreactivity (CVR) to acetazolamide (ACZ) challenge were quantitatively measured to evaluate cerebral hemodynamic reserve. For this, single photon emission CT (SPECT) was performed before and 7 days after carotid angioplasty and stent placement (12, 13). We used a rotating three-head gamma camera (Prism3000; Picker, Cleveland, OH). Data were acquired in a continuous rotating mode in a reciprocal direction at 20 seconds per revolution for 66 minutes from 96 directions in a 64×64 matrix. The transaxial images were reconstructed with a Butterworth filter. During dynamic SPECT, 111 MBq of [^{123}I]Iodoamphetamine (^{123}I -IMP; Nihon Mediphsics, Nishinomiya, Japan) was intravenously injected at the beginning of imaging and again at the start of the 10th frame of acquisition, with continuous arterial blood sampling for 366 seconds after injection. Eleven minutes after the initial ^{123}I -IMP injection, 1 g of ACZ was slowly injected intravenously. An additional 111 MBq of ^{123}I -IMP was injected 23 minutes after the initial injection. The absolute relative CBF values were quantified with the microsphere method, by using the octanol extraction activities of arterial samplings. Two perfusion images, one obtained with the subject at rest and another with the subject in a vasodilated state, were obtained with the subtraction technique. An irregular, mirror-shaped region of interest was placed in the whole MCA territory in the affected hemisphere at the level of the parietal lobe, excluding the infarct, and in the corresponding contralateral region. The following equation was used to estimate the percentage of increase in regional CBF induced by ACZ challenge, in terms of CVR: $\text{CVR} = (\text{ACZ challenge relative CBF} - \text{resting relative CBF}) / \text{resting relative CBF}$.

Technetium-99m Hexamethylpropyleneamine Oxime SPECT

$^{99\text{m}}\text{Tc}$ -hexamethylpropyleneamine oxime (HMPAO) SPECT was performed immediately after carotid angioplasty and stent placement by using the scanner used for split-dose ^{123}I -IMP SPECT. Patients received 20 mCi (740 MBq) of $^{99\text{m}}\text{Tc}$ -HMPAO, and the first scan for CBF imaging was started 5 minutes later (acquisition time, 20 minutes). Images were reconstructed in a 128×128 matrix, with a section thickness of 5 mm in the transverse, sagittal, and coronal planes. An irregular, mirror-shaped region of interest was placed in the whole MCA territory of the affected hemisphere at the level of the parietal lobe, excluding the infarct, and in the corresponding contralateral region. The asymmetry index (affected side counts per pixel/contralateral side counts per pixel) was calculated. Hyperperfusion after carotid angioplasty and stent placement was defined as a CBF increase of $>100\%$, as compared with the normal side, immediately after the procedure.

Procedural Technique

Patients were pretreated with aspirin (100 mg/day), ticlopidine (200 mg/day), or both for at least 3 days before the procedure. Carotid angioplasty and stent placement were performed by means of transfemoral catheterization with the patient under local anesthesia. Predilation was performed with a controlled-compliant balloon dilation catheter. The balloon size was selected according to normal luminal diameter of each internal carotid artery immediately distal to the stenotic segment (diameter at full dilation was usually 5 or 6 mm). The balloon was inflated with 6–8 atm for 60 seconds. If a satisfactory increase in diameter was not achieved or if substantial wall dissection was observed after the balloon dilation, a self-expandable stent (Smart stent; Cordis Endovascular Systems, Miami, FL) was deployed. Poststenting dilation was omitted to prevent embolic complications. Distal protection was not used during the procedure. Intravenous heparin was administered during the procedure ($100 \mu\text{g}/\text{kg}$ plus $1000 \mu\text{g}/\text{h}$) and not reversed at completion. Intravenous Argatroban (Daiichi Pharmaceutical Co., Ltd., Nishinomiya, Japan) was continued for 24 hours after the procedure (60 mg/24 h). A systolic blood pressure of less than 130 mm Hg was maintained for 1 week after the procedure. Usually, the carotid sinus reflex lowered the patients' blood pressure after carotid angioplasty and stent placement; occasionally, intravenous catecholamine was necessary to maintain blood pressure.

Definition of Hyperperfusion Phenomenon and Hyperperfusion Syndrome

Hyperperfusion phenomenon was used to designate increased CBF after carotid angioplasty and stent placement (CBF increase of $>100\%$ compared with the normal side). Hyperperfusion syndrome was used to designate the development of clinical symptoms as a result of rapidly increased CBF in excess of that required to meet metabolic demands.

Statistical Analysis

Statistical analysis was performed, with descriptive statistics presented as the mean \pm SD. The Student *t* test was used for univariate analysis. The Fisher exact probability test was used for proportion analysis. $P < .05$ was considered to indicate significance. A commercially available software package was used (Statview 5.0 software; SAS Institute Inc, Cary, NC).

Results

Stents (Smart stent; Cordis Endovascular Systems) were deployed in 25 patients, whereas satisfactory

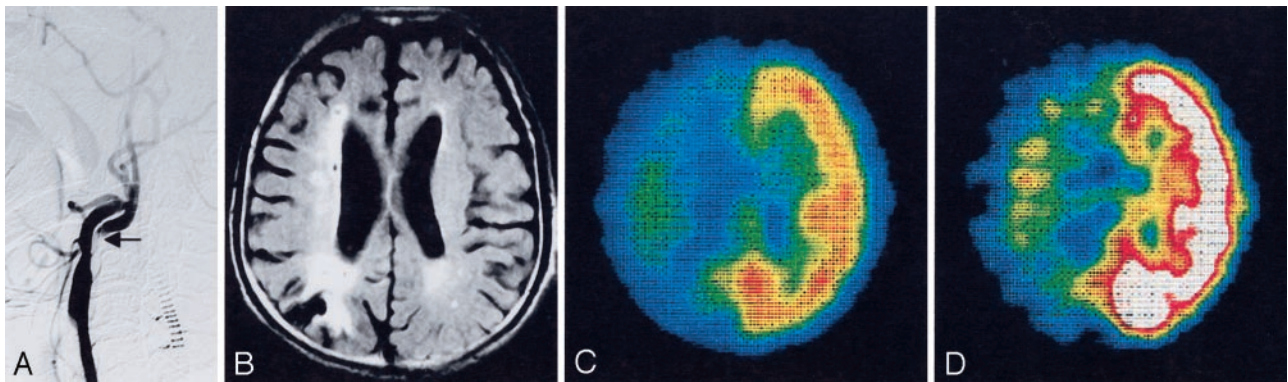


FIG 1. Images obtained in an 83-year-old man with a minor, completed stroke. A, Pretreatment right carotid angiogram shows severe internal carotid artery stenosis at its origin (arrow), with delayed filling of the distal part of the artery. B, Pretreatment FLAIR image shows small ischemic lesions in the right posterior watershed area. C, Pretreatment ^{123}I -IMP SPECT scan in the resting state shows severely decreased perfusion in the right cerebral hemisphere with an asymmetry index of 50.7%. D, Pretreatment SPECT scan obtained with an ACZ challenge shows an impaired cerebrovascular reserve of 11.1% in the right cerebral hemisphere.

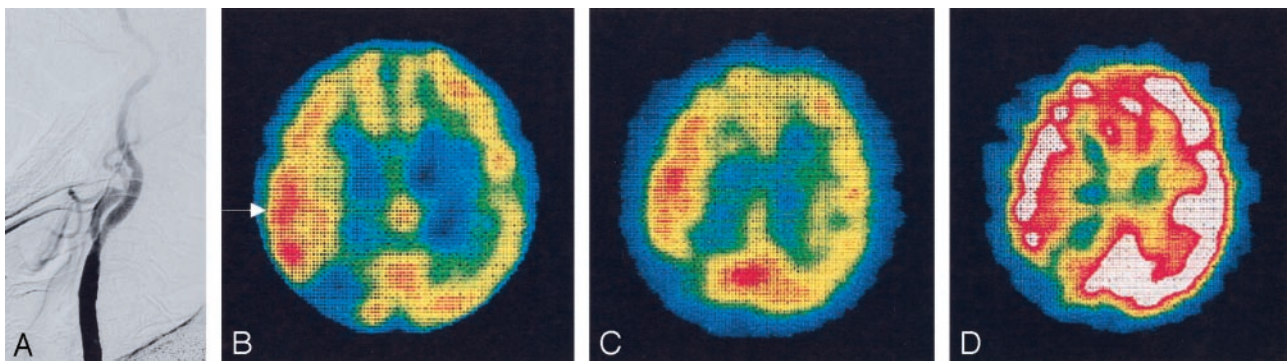


FIG 2. Images obtained in an 83-year-old man with cerebral hyperperfusion after carotid stent placement. A, Postprocedural carotid angiogram shows satisfactory dilatation of the right internal carotid artery with normalized distal blood flow. B, $^{99\text{m}}\text{Tc}$ -HMPAO SPECT scan obtained immediately after stent placement shows hyperperfusion in the right MCA territory, with an asymmetry index of 120.3% (arrow). C, ^{123}I -IMP SPECT scan in the resting state obtained 7 days after stent placement shows prolonged hyperperfusion in the territory, with an asymmetry index of 108.1%. D, ^{123}I -IMP SPECT scan obtained with an ACZ challenge 7 days after stent placement shows a slightly improved but still impaired cerebrovascular reserve of 13.4% in the right cerebral hemisphere.

dilation of carotid stenoses was achieved by means of balloon angioplasty alone in five patients. All carotid stenoses were successfully dilated. Carotid angioplasty and stent placement reduced pretreatment stenoses of 70–99% ($94.0 \pm 7.0\%$) to residual stenoses of 0–40% ($15.1\% \pm 17.7\%$), according to the NASCET criteria. All patients tolerated the procedures well. No patient had new ischemic symptoms, and postprocedural CT scans revealed no cerebral hemorrhage during the periprocedural period. However, an 83-year-old man developed status epilepticus 2 weeks after the procedure, and CT scans revealed cerebral edema in the ipsilateral cerebral hemisphere. His seizure was difficult to control, and he had left-sided weakness as a sequel (Figs 1 and 2).

Changes in CBF and CVR

Three patients had cerebral hyperperfusion phenomenon, as shown by HMPAO SPECT immediately after the procedure (hyperperfusion group). In these patients, their pretreatment asymmetry index of 50.7–98.7% ($70.2\% \pm 25.2\%$) increased to a post-treatment index of 111.4–120.3% ($116.0\% \pm 4.5\%$). The

asymmetry index was not significantly different in the other 27 patients (nonhyperperfusion group) before ($91\% \pm 14.1$) and after ($95.16\% \pm 8.04$) treatment (Fig 3). Univariate analysis demonstrated significant differences between the hyperperfusion and nonhyperperfusion groups in terms of patient age (78.3 ± 4.16 vs 66.7 ± 7.82), pretreatment ipsilateral CVR ($6.3\% \pm 5.7$ vs $40.3\% \pm 20.1$), and pretreatment asymmetry index ($70.2\% \pm 25.2$ vs $91\% \pm 14.1$) (Fig 4). No significant difference was observed between the two groups in pretreatment resting CBF value (19.6 ± 2.7 vs 25.1 ± 5.8 mL/100 g/min), the pretreatment degree of carotid stenosis ($99\% \pm 0$ vs $93\% \pm 7.2$), and the interval from the onset of ischemic symptoms (120 ± 30 vs 122 ± 22.6 days) (Table 1). Seven days after the procedure, CBF and CBV measurement demonstrated that the asymmetry index had decreased to $105.3\% \pm 4.1$ in the hyperperfusion group, whereas the asymmetry index of the nonhyperperfusion group ($95.2\% \pm 8.0$) exhibited no significant change (Fig 3). On postoperative day 7, resting CBFs of the hyperperfusion and nonhyperperfusion groups were 35.9 ± 12.9 and 26.8 ± 5.9 mL/100 g/min,

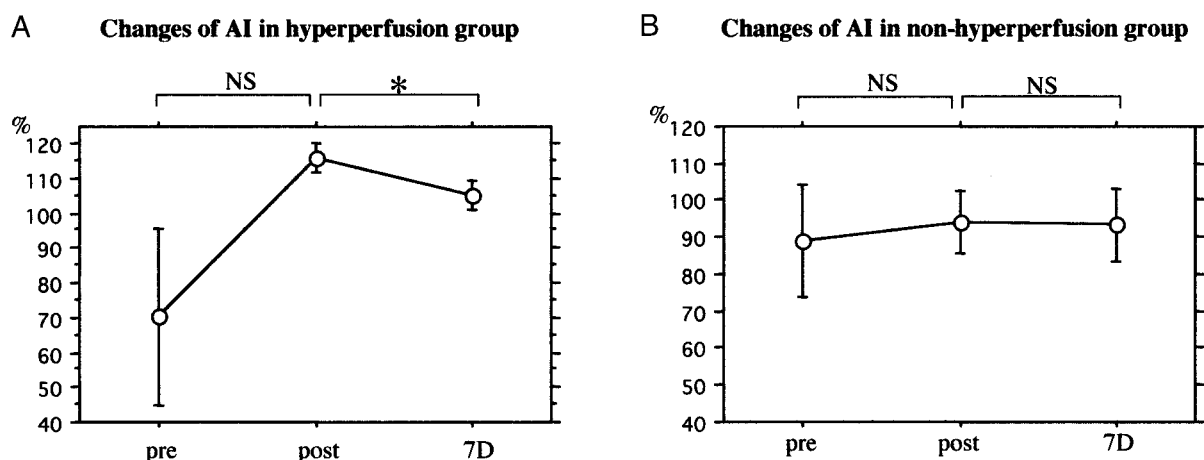


Fig 3. Sequential changes in the asymmetry index (AI). In the hyperperfusion group (A), the pretreatment index of $70.2\% \pm 25.2$ increases to $116.0\% \pm 4.5$ immediately after carotid stent placement and then decreases to $105.3\% \pm 4.1$ 7 days after the procedure (Asterisk indicates $P < .01$.) The index did not significantly change in the nonhyperperfusion group (B).

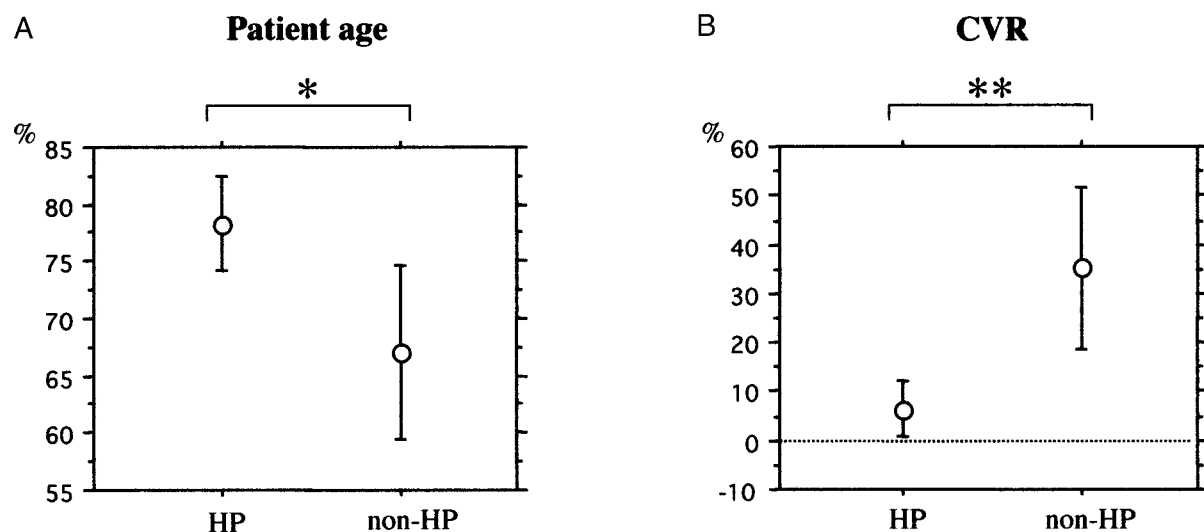


Fig 4. Comparisons of patient age, pretreatment ipsilateral CVR, and asymmetry index (AI) between the hyperperfusion (HP) and nonhyperperfusion (non-HP) groups. Univariate analysis demonstrated significant differences between the groups for age (78.3 ± 4.16 vs 66.7 ± 7.8 years) A, pretreatment ipsilateral CVR ($6.3\% \pm 5.7$ vs $40.3\% \pm 20.1$) B, and asymmetry index ($70.2\% \pm 25.2$ vs $91.1\% \pm 14.1$). Asterisk indicates $P < .05$; double asterisk, $P < .01$.

TABLE 1: Patient characteristics and findings of pre-treatment CBF study

Characteristic	Hyperperfusion Group (n = 3)	Nonhyperperfusion Group (n = 27)	P Value
Age (y)	78.3 ± 4.2	66.7 ± 7.8	.0185
Interval from onset (d)	120 ± 30	122 ± 22.6	.9896
Degree of carotid stenosis (%)	99 ± 0	93 ± 7.2	.2
Resting CBF (mL/100 g/min)	19.6 ± 2.7	25.1 ± 5.8	.1285
Asymmetry index (%)	70.2 ± 25.2	91.1 ± 14.1	.0325
Pretreatment CVR (%)	6.3 ± 5.7	40.3 ± 20.1	.0075

respectively, and CVRs were $13.6\% \pm 0.2$ and $52.2 \pm 21.9\%$, respectively. In the Fisher exact probability test for proportion analysis, variables determined to be significant predictors of hyperperfusion phenomenon included patient age >75 years, pretreatment CVR <20 , and pretreatment asymmetry index $<75\%$; P values for these variables are shown in Table 2.

Discussion

Cerebral Hyperperfusion after CEA

Cerebral hyperperfusion syndrome after CEA is a well-described complication. After surgical revascularization that alleviates a high-grade symptomatic stenotic lesion, hyperperfusion syndrome may occur as a result of a sudden, rapid increase in CBF in

TABLE 2: Univariate analysis of variables related to hyperperfusion phenomenon

Variable	Hyperperfusion Group (n = 3)	Nonhyperperfusion Group (n = 27)	P Value
Age <75 y	3	4	.0086
CVR <20%	3	4	.0086
Pretreatment asymmetry index <75%	2	2	.0394

excess of that required to meet metabolic demands. Transient cerebral hyperemia can lead to severe unilateral headache, face and eye pain, confusion, seizures (7), focal neurologic deficits, and intracerebral hemorrhages. Intracerebral hemorrhage reportedly occurs in 0.4–1.8% of patients after CEA and accounts for approximately one-fifth of all perioperative strokes (8, 9). The prognosis for these patients is poor, with mortality rates of 36–63%; survivors have substantial morbidity. Piepgras et al (8) reported a 11.6% incidence of hyperperfusion, defined as a CBF increase of >100% after CEA; intracerebral hemorrhage developed in 3.3% of subjects with hyperperfusion. Hyperperfusion syndrome is thought to be the result of failed normal cerebral autoregulation involved in CBF, secondary to longstanding decreased perfusion pressure. This failure results in the cerebral arterioles being maximally dilated over a long period, with subsequent loss of their ability to constrict when normal perfusion pressure is restored. Autoregulatory failure and cerebral hyperperfusion persist for some time after revascularization, but the conditions eventually normalize. The pathologic consequences of autoregulatory failure appear similar to those of normal perfusion pressure breakthrough, which occasionally occurs after resection of cerebral arteriovenous malformations. In both of these conditions, restoration of normal CBF to a chronically underperfused brain can result in edema, capillary breakthrough, and perivascular hemorrhages in association with fibrinoid necrosis of small arteries and macroscopic hemorrhages.

Cerebral Hyperperfusion after Carotid Angioplasty and Stent Placement

Percutaneous transluminal angioplasty and stent placement is becoming an increasingly common treatment for high-grade symptomatic stenoses involving the extracranial and intracranial arteries. Data on the benefits, risks, and complications of this procedure are accumulating, and several prospective trials comparing the results of CEA with angioplasty and stent placement are now underway (1, 2). The incidence of hyperperfusion syndrome after cerebral angioplasty and stent placement has not been extensively studied. A small number of studies of hyperperfusion syndrome after carotid angioplasty and stent placement have been conducted (4–6). Meyers et al (10) reported that five (6.6%) of 76 patients with carotid stenoses (10 intracranial, 66 extracranial) developed

hyperperfusion syndrome after angioplasty and stent placement. Morrish et al (11) observed a 3.8% incidence of cerebral hemorrhage after carotid stent placement. In these studies, the incidence of cerebral hyperperfusion syndrome was greater than that reported for CEA. In the present study, hyperperfusion syndrome developed in one patient (3.3%), and SPECT scans obtained immediately after the procedure demonstrated hyperperfusion phenomenon in three patients (10%). This trend may reflect patient selection: High-risk patients (eg, those with high-grade stenosis, and older patients with medical complications) who are regarded as suboptimal candidates for CEA are commonly referred for angioplasty and stent placement, and endovascular treatment involves different anticoagulation protocols. Stimulation of carotid baroreceptors with a balloon or carotid stent may play an important role in the development of delayed hyperperfusion syndrome, as in the 83-year-old patient described earlier. Carotid baroreceptor stimulation induces transient, sometimes prolonged, bradycardia and hypotension; subsequent rebound arterial hypertension may induce cerebral hyperperfusion.

Risk Factors for Cerebral Hyperperfusion

Several variables have been identified as risk factors for the development of post-CEA intracerebral hemorrhage. These include severe ($\geq 90\%$) ipsilateral stenosis, impaired collateral blood flow secondary to advanced occlusive disease in other extracranial cerebral vessels or an incomplete circle of Willis, perioperative and postoperative hypertension, and use of antiplatelet agents or other anticoagulants (14). Some surgical reports suggest that patients with preoperative hemodynamic failure are at definite risk for hyperperfusion syndrome (15–17). In a study by Hosoda et al (18), CBF significantly increased on the first postoperative day in subjects with reduced preoperative CVR but not in those with normal preoperative CVR. This finding suggests that the basic mechanism responsible for hyperperfusion is massive vasodilatation due to loss of vasoconstriction from chronic cerebral ischemia distal to the high-grade carotid stenosis. However, there have been no reported findings regarding predictors of postprocedural hyperperfusion after angioplasty and stent placement, to our knowledge. In the present study, patient age, pretreatment CVR, and pretreatment asymmetry index were significant predictors of hyperperfusion phenomenon after carotid angioplasty and stent placement. These results suggest that, in older patients, profound cerebral ischemia with impaired hemodynamic reserve is the highest-risk situation for cerebral hyperperfusion phenomenon after carotid angioplasty and stent placement. When this treatment is required for such patients, extreme postprocedural care must be taken.

Although pretreatment resting CBF, degree of carotid stenosis, and interval from the onset of ischemic symptoms were not significant risk factors, the num-

ber of patients with the hyperperfusion phenomenon and syndrome was too low to categorically state that these variables are not predictive of hyperperfusion phenomenon after carotid angioplasty and stent placement. In addition, factors predictive of hyperperfusion phenomenon may differ from those associated with the hyperperfusion syndrome. Results from past studies suggest that more recent ischemic symptoms may be associated with hyperperfusion syndrome.

Conclusion

In the present study, significant predictors of hyperperfusion phenomenon after carotid angioplasty and stent placement included patient age, pretreatment CVR, and pretreatment asymmetry index. Pretreatment CBF measures, including quantification of CVR and SPECT findings immediately after the procedure may aid in identifying at-risk patients and in initiating careful monitoring and control of blood pressure to prevent hyperperfusion syndrome.

References

- Hobson RW II, Brott T, Ferguson R, et al. **CREST: Carotid Revascularization Endarterectomy versus Stent Trial.** *Cardiovasc Surg* 1997;5:457-458
- Malek AM, Higashida RT, Phatouros CC, et al. **Stent angioplasty for cervical carotid artery stenosis in high-risk symptomatic NASCET-ineligible patients.** *Stroke* 2000;31:3029-3033
- Sivaguru A, Venables GS, Beard JD, Gaines PA. **European carotid angioplasty trial.** *J Endovasc Surg* 1996;3:16-20
- Ho DSW, Wang Y, Chui M, Ho SL, Cheung RTF. **Epileptic seizures attributed to cerebral hyperperfusion after percutaneous transluminal angioplasty and stenting of the internal carotid artery.** *Cerebrovasc Dis* 2000;10:374-379
- McCabe DJH, Brown MM, Clifton A. **Fatal cerebral reperfusion hemorrhage after carotid stenting.** *Stroke* 1999;30:2483-2486
- Schoser BGH, Heesen C, Eckert B, Thie A. **Cerebral hyperperfusion injury after percutaneous transluminal angioplasty of extracranial arteries.** *J Neurol* 1997;244:101-104
- Kiebertz K, Ricotta JJ, Moxley RT III. **Seizures following carotid endarterectomy.** *Arch Neurol* 1990;47:568-570
- Piepgas DG, Morgan MK, Sundt TM, Yanagihara T, Mussman LM. **Intracerebral hemorrhage after carotid endarterectomy.** *J Neurosurg* 1988;68:532-536
- Solomon RA, Loftus CM, Quest DO, Correll JW. **Incidence and etiology of intracerebral hemorrhage following carotid endarterectomy.** *J Neurosurg* 1986;64:29-34
- Meyers PM, Higashida RT, Phatouros CC, et al. **Cerebral hyperperfusion syndrome after percutaneous transluminal stenting of the craniocervical arteries.** *Neurosurgery* 2000;47:335-345
- Morrish W, Grahovac S, Douen A, et al. **Intracranial hemorrhage after stenting and angioplasty of extracranial carotid stenosis.** *AJNR Am J Neuroradiol* 2000;21:1911-1916
- Imaizumi M, Kitagawa K, Hashikawa K, et al. **Detection of misery perfusion with split-dose 123I-iodoamphetamine single-photon emission computed tomography in patients with carotid occlusive disease.** *Stroke* 2002;33:2217-2223
- Moriwaki H, Matsumoto M, Hashikawa K, et al. **Iodine-123-iomazenil and iodine-123-iodoamphetamine SPECT in major cerebral artery occlusive disease.** *J Nucl Med* 1998;39:1348-1353
- Hosoda K, Fujita S, Kawaguchi T, Shose Y, Shibata Y, Tamaki N. **Influence of degree of carotid artery stenosis and collateral pathways and effect of carotid endarterectomy on cerebral vasoreactivity.** *Neurosurgery* 1998;42:988-995
- Baker CJ, Mayer SA, Prestigiacomo CJ, Heertum RLV, Solomon RA. **Diagnosis and monitoring of cerebral hyperperfusion after carotid endarterectomy with single photon emission computed tomography: case report.** *Neurosurgery* 1998;43:157-161
- Cikrit DF, Dalsing MC, Harting PS, et al. **Cerebral vascular reactivity assessed with acetazolamide single photon emission computer tomography scans before and after carotid endarterectomy.** *Am J Surg* 1997;174:193-197
- Yoshimoto T, Houkin K, Kuroda S, Abe H, Kashiwaba T. **Low cerebral blood flow and perfusion reserve induce hyperperfusion after surgical revascularization: case reports and analysis of cerebral hemodynamics.** *Surg Neurol* 1997;48:132-139
- Hosoda K, Kawaguchi T, Shibata Y, et al. **Cerebral vasoreactivity and internal carotid artery flow help to identify patients at risk for hyperperfusion after carotid endarterectomy.** *Stroke* 2001;32:1567-1573