

# Generic Contrast Agents

Our portfolio is growing to serve you better. Now you have a *choice*.



[VIEW CATALOG](#)

# AJNR

## **A Technique to Circumvent Subcutaneous Cement Tracts during Percutaneous Vertebroplasty**

Timothy J. Kaufmann, John T. Wald and David F. Kallmes

*AJNR Am J Neuroradiol* 2004, 25 (9) 1595-1596

<http://www.ajnr.org/content/25/9/1595>

This information is current as  
of May 11, 2025.

## A Technique to Circumvent Subcutaneous Cement Tracts during Percutaneous Vertebroplasty

Timothy J. Kaufmann, John T. Wald, and David F. Kallmes

**Summary:** The deposition of a subcutaneous cement tract is a potential complication of percutaneous vertebroplasty. These tracts can be a source of pain and tenderness for the patient. We describe a case of symptomatic cement deposition within a needle tract in the subcutaneous tissues that required surgical removal, and we describe a technique to prevent this complication in a second patient, by using needle redirection to cut across the cement core.

Percutaneous vertebroplasty (PV) has become a widely employed therapy for painful vertebral compression fractures. Complications of the procedure are uncommon but are most frequently related to cement leakage (1). In this report, we describe a complication in which a tract of cement leading from the vertebral body to the subcutaneous tissue was created and required surgical removal. We also report a simple technique that can be used to avoid such a complication.

### Case 1

A 57-year-old female patient who had been treated with corticosteroids for sarcoidosis developed osteoporosis and multiple thoracic and lumbar vertebral compression fractures. PV of the T9–T12 vertebrae was performed at the same sitting because of severe, persistent back pain and limitation in mobility that was refractory to conservative therapy.

We typically employ a moderately viscous cement mixture of powdered Codman cranioplastic polymethylmethacrylate, gentamicin, barium (Parallax Medical, Scotts Valley, CA), and liquid Codman cranioplastic methylmethacrylate monomer in our PV cases (2). On withdrawal of the 13-gauge Osteo-Site needle (Cook Inc., Bloomington, IN) from the T9 vertebra, the cylindrical column of partially solidified cement that was yet in the needle remained in the needle tract from the site of instillation in the vertebral body, through the left pedicle, and into the subcutaneous tissues of the lower thorax, as depicted radiographically (Fig 1).

The patient experienced persistent pain and tenderness at the site of this subcutaneous cement deposition, particularly when sitting on backed chairs. Two months after the procedure, the patient underwent surgical removal of 2.5 cm of the superficial portion of the subcutaneous cement. The surgery was effective in alleviating her pain.

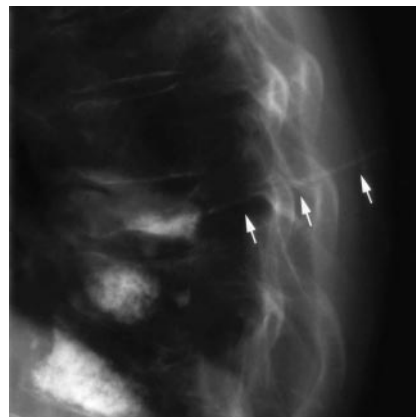


FIG 1. Cement is seen in the needle tract of the subcutaneous tissues of the lower thorax, extending dorsally from the T9 vertebral body cement deposition site (arrows).

### Case 2

A 66-year-old female patient with multiple myeloma and osteoporosis developed multiple thoracic vertebral compression fractures. PV of the T8, T11, and T12 vertebrae was performed because of severe, persistent back pain and interference with activities of daily living.

We used 11-gauge Osteo-Site needles and the cement mixture described in case 1. Following cement instillation through the left T11 pedicle, we noticed that as the needle was being withdrawn with its tip still within the posterior aspect of the vertebral body, the core of partially solidified cement within the needle was being deposited in the needle tract (Fig 2A). Despite multiple attempts at breaking the cement core by rotating the needle and advancing and withdrawing the needle, the column of cement remained unbroken.

To prevent the deposition of a subcutaneous cement tract, the needle tip was then redirected superiorly and advanced toward the superior endplate, which cut completely through the column of cement (Fig 2B). This maneuver disconnected the cement deposited in the vertebral body from that which remained in the needle and allowed the needle to be subsequently withdrawn completely without depositing cement within the needle tract (Fig 2C).

The patient tolerated the procedure well and is doing well in short-term follow-up.

### Discussion

Occasionally during PV, the cement mixture partially solidifies before the introducing needle can be removed, particularly as the length of time between cement mixture and needle removal increases. This may be more common when multiple vertebral levels are treated in the same sitting by using one cement mixture or when complicating features occur which otherwise prolong the procedure. This cement solid-

Received March 31, 2004; accepted April 6.

From the Department of Radiology, Mayo Clinic, Rochester, MN.

Address correspondence to Timothy J. Kaufmann, MD, Department of Radiology, Mayo Clinic, Mayo Building, West 2, Rochester, MN 55905.

© American Society of Neuroradiology

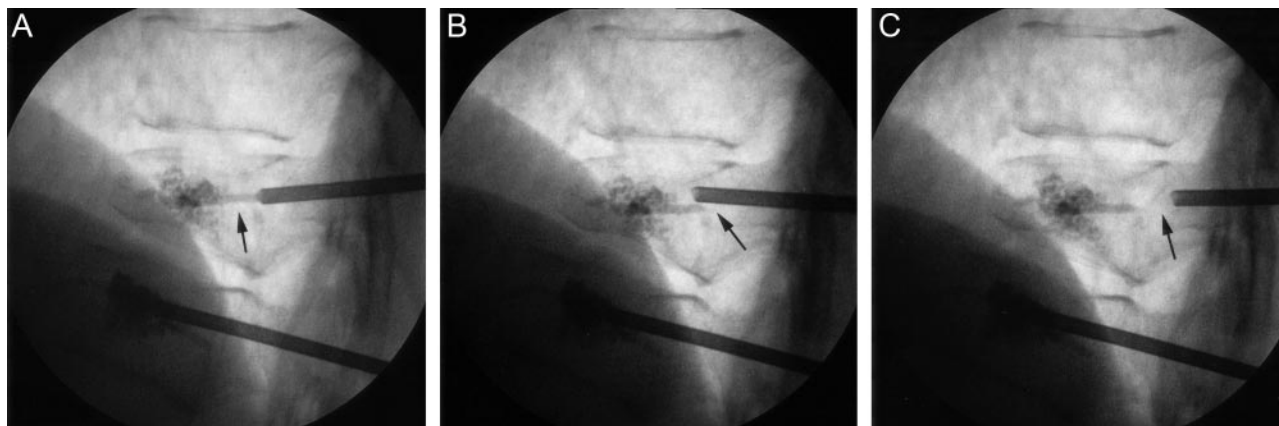


FIG 2. Deposition of a subcutaneous cement tract is averted.

A, Cement column, visualized in the posterior T11 vertebral body (arrow) as needle withdrawal is first begun.

B, The cement column inside the needle is broken at the tip of the needle (arrow) by pulling the needle hub inferiorly and advancing the tip of the needle toward the superior endplate.

C, The needle can then be withdrawn without further cement deposition in the needle tract (arrow).

ification can result in symptomatic subcutaneous cement deposition in the needle tract, which requires surgical intervention, as presented in case 1. We have had one other similar case in our practice, which also required subcutaneous tract excision.

We describe a simple maneuver in case 2 that can avert this complication. This technique may be employed during needle removal as soon as it is recognized that cement deposition is occurring in the needle tract. As needle position within the vertebral body may differ in other cases, the needle may be advanced forward across the cement column to cut it in any direction that is safe, with care taken to remain within the vertebral body and to avoid transgression of a vertebral endplate. The need for this technique should not be frequent, but we have used it successfully in two patients since case 1.

There are potential limitations to this technique. It would be theoretically possible to fracture the pedicle if extreme repositioning of the needle trajectory were needed to cut through the cement tract. Risk of this complication might be mitigated in soft, osteoporotic bone. Further, redirection and advancement of the needle might injure adjacent tissue such as the vertebral endplate, which should be avoided.

## References

1. Mathis JM. Percutaneous vertebroplasty: complication avoidance and technique optimization. *AJNR Am J Neuroradiol* 2003;24:1697-1706
2. Jensen ME, Evans AJ, Mathis JM, et al. Percutaneous polymethylmethacrylate vertebroplasty in the treatment of osteoporotic vertebral body compression fractures: technical aspects. *AJNR Am J Neuroradiol* 1997;18:1897-1904