AJNR

MR Imaging of Cerebral Cortical Involvement in Aceruloplasminemia

Marina Grisoli, Alberto Piperno, Luisa Chiapparini, Raffaella Mariani and Mario Savoiardo

AJNR Am J Neuroradiol 2005, 26 (3) 657-661
http://www.ajnr.org/content/26/3/657

This information is current as of August 9, 2025.

AJNR Am J Neuroradiol 26:657–661, March 2005

MR Imaging of Cerebral Cortical Involvement in Aceruloplasminemia

Marina Grisoli, Alberto Piperno, Luisa Chiapparini, Raffaella Mariani, and Mario Savoiardo

Summary: Aceruloplasminemia is a rare autosomal recessive disorder. The lack of ceruloplasmin ferroxidase activity leads to parenchymal and reticuloendothelial iron overload, resulting in diabetes and progressive neurodegeneration with extrapyramidal disorders, ataxia, and dementia. We describe the MR imaging findings in a 40-year-old woman with hereditary aceruloplasminemia. The abnormal T2 hypointensities were more marked than those seen in any other condition, including degenerative disorders of the basal ganglia and Wilson disease, and they may be typical of aceruloplasminemia. To our knowledge, involvement of the cortex has not been described and suggests that brain iron accumulation in aceruloplasminemia is more extensive than previously believed, even in asymptomatic patients.

Ceruloplasmin is a copper-containing α2-glycoprotein synthesized in hepatocytes that carries more than 95% of the copper present in plasma. This protein has ferroxidase activity and catalyzes the conversion of ferrous iron into ferric iron during transfer to transferrin with consequent iron delivery. A complete absence of circulating serum ceruloplasmin (aceruloplasminemia) results in ferrous iron accumulation within both the reticuloendothelial system and parenchymal cells (1, 2).

Aceruloplasminemia (or hereditary ceruloplasmin deficiency), first described by Miyajima et al (1), is an autosomal recessive disorder affecting iron metabolism. It is associated with mutations of the ceruloplasmin (*Cp*) gene on chromosome 3q (3). Clinical manifestations of the disease are diabetes mellitus, retinal pigmentary degeneration, dystonia, extrapyramidal signs, cerebellar ataxia, and dementia. Pathologic studies have shown marked accumulation of iron in the liver, pancreas, retina, and CNS, and marked loss of neurons occurs in the neostriatum, dentate nucleus, and thalamus. Although the pathogenesis of brain damage in aceruloplasminemia is still not clear, iron-mediated, free-radical stress is speculated to contribute to neuronal cell death (4, 5). The neurologic symptoms reflect the specific sites of neurodegeneration and iron deposition seen at autopsy. MR imaging abnormalities consist of marked hypointensity on T2-weighted images in the putamina, caudate, and dentate nuclei consistent with iron deposition (3, 6–13).

We report a patient with inherited aceruloplasminemia who, in addition to the deposition of iron in the usual sites, had particular cortical involvement on MR imaging. To our knowledge, this finding has not been described and may help to further characterize the disease.

Case Report

A 40-year-old woman, the proband, was admitted to the hospital for a mild microcytic anemia (hemoglobin level, 11 g/dL; mean corpuscular volume, 74 fl), with a low serum iron concentration (27 μg/dL), low transferrin saturation (10%), and an increased serum ferritin level (471 μg/L). Serum ceruloplasmin levels were repeatedly undetectable. No other biochemical abnormality was found. She had no symptoms except for generalized weakness. Spectroscopy quantum interference device analysis confirmed hepatic iron overload (1252 μg/g liver wet weight; upper normal value, 400 μg/g liver wet weight).

The mother and a maternal uncle of the proband presented with mild microcytic anemia with low serum iron, high serum ferritin, and undetectable serum ceruloplasmin levels. The mother also had mild ataxia and dystonia. Both the mother and the uncle refused hospitalization for a full medical evaluation. The proband's mother and children (one son and one daughter) had normal laboratory test results, with serum ceruloplasmin values at the lowest level of the normal range or slightly below it. The proband's brother, who had a normal neurologic examination, was found to have a mild hepatic iron overload.

Direct sequencing of the entire ceruloplasmin gene, including exons 1–20 and intron-exon boundaries, was carried out in the proband, her brother, and her children by using a reaction kit (ABI Prism Terminator Cycle Sequencing Ready; PE Applied Biosystems, Foster City, CA) and DNA Sequencer (ABI Prism 3100 Avant; PE Applied Biosystems). A novel missense mutation in exon 4, changing a phenylalanine to serine (F198S), was found in the homozygous form in the proband and in the heterozygous form in the brother and the proband's children. The F198S mutation was confirmed during restriction fragment length polymorphism analysis by using Hinf-I digestion in the proband and in the available relatives, but this was not found in 50 healthy individuals.

Brain MR imaging studies of the proband, her brother, and her two children were obtained on a 1.5T unit (Gyroscan ACS-II; Philips Medical Systems, Best, the Netherlands). MR images of her mother were obatined in another hospital by using a 0.5T unit (Gyroscan T5-NT; Philips). Axial and coronal spin-echo proton density- and T2-weighted images (TR/TE, 2300/20 and 90; 4- and 6-mm section thickness) and sagittal spin-echo T1-weighted images (TR/TE, 600/15) were obtained

Received February 5, 2004; accepted after revision June 14.

From the Department of Neuroradiology, Istituto Nazionale Neurologico C. Besta, Milano (M.G., L.C., M.S.), and the Department of Clinical Medicine, Azienda Ospedaliera San Gerardo, Università Milano-Bicocca, Monza (A.P., R.M.), Italy.

Address reprint requests to M. Grisoli, MD, Department of Neuroradiology, Istituto Nazionale Neurologico C. Besta, Via Celoria 11, 20133 Milano, Italy.

© American Society of Neuroradiology

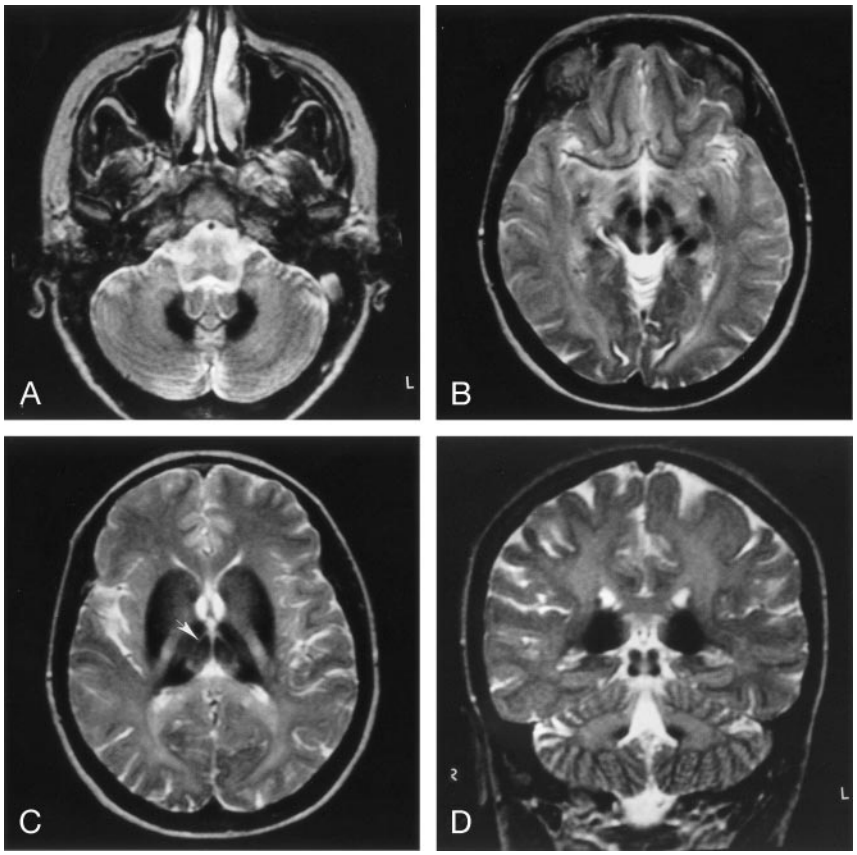

FIG 1. Spin-echo T2-weighted MR images obtained at 1.5T show marked hypointensity in the dentate nuclei (*A* and *D*), substantia nigra and red nuclei (*B*), neostriatum and thalamic nuclei (*C* and *D*), and superior and inferior colliculi (*B* and *D*). Note the relative hyperintensity of the internal medullary lamina of the thalamus (*arrow* in *C*) and the hyperintensity of the pyramidal tract in the posterior limb of the internal capsule. The white matter of the parietal and occipital lobes and of the cerebellar hemispheres is diffusely hyperintense. The cerebral cortex is questionably hypointense (*D*).

A–C, Axial images.

D, Coronal image.

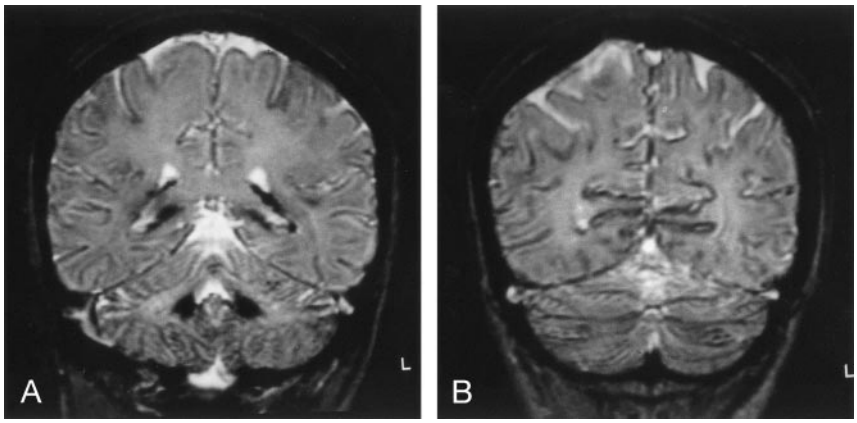

FIG 2. Coronal T2*-weighted gradient recalled-echo images at the level of the fourth ventricle (A) and 20 mm dorsally (B) show definite hypointensity in the superficial cortical layers of the cerebral and cerebellar hemispheres.

in the patient and in her family. In the proband, axial T1-weighted and gadolinium-enhanced (0.2 mmol/Kg) imaging was also performed. A coronal fluid-attenuated inversion recovery sequence (TR/TE/TI, 8000/150/2200) and axial T2*-weighted gradient recalled-echo sequences were also performed at 1.5T (TR/TE, 600/35; flip angle, 25°). The proband underwent a second MR imaging study 1 year later, with the same examination protocol.

Results

Brain T2-weighted MR images of the proband showed two findings: 1) hypointensity consistent with magnetic susceptibility effect due to iron deposits in several gray structures and 2) slight hyperintensity of the white matter. Hypointensity of the gray structures involved the neostriatum, mainly the putamina, dentate nuclei, substantia nigra, red nuclei, inferior and superior colliculi, and thalamic nuclei, particularly the pulvinar (Fig 1). Diffuse hypointensities were also present on T2*-weighted gradient recalled-echo images in the cerebellar cortex and in the superficial layers of the cerebral cortex (Fig 2). Spin-echo T1-weighted images showed a mild hypointensity in the dentate nuclei. No signal intensity abnormalities were recognizable in the other gray matter structures.

White matter hyperintensities on T2-weighted images were present in the posterior frontal and parieto-occipital regions and extended caudally, particularly along the corticospinal tracts down to the brain stem (Figs 1 and 3). In the thalami, the internal medullary

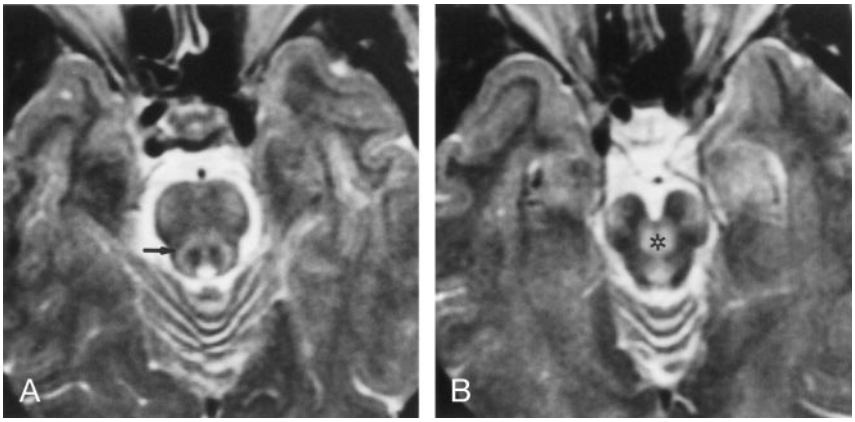

FIG 3. Axial SE T2-weighted images show mild hyperintensity of the corticospinal and corticopontine tracts in the cerebral peduncles and basis pontis.

A, Superior cerebellar peduncles are hyperintense (*arrow*).

B, Their decussation (*asterisk*) are also hyperintense.

lamina appeared hyperintense (Fig 1C). In the posterior fossa, in addition to the pyramidal tract abnormalities and diffuse hyperintensity of the white matter of the cerebellar hemispheres, hyperintensities of the middle cerebellar peduncles and the superior cerebellar peduncles, particularly at the level of the decussation, were observed (Fig 3).

The second examination of the proband did not show any difference in the extension and intensity of signal intensity abnormalities.

T2-weighted MR images of the patient's mother, obtained at another hospital with a 0.5T unit, showed a mild hypointensity in the putamen, pulvinar, red nuclei, and dentate nuclei. A questionable hypointensity also involved the cerebral cortex. A few small, hyperintense areas in the white matter of the hemispheres were considered consistent with chronic ischemic lesions. Brain MR imaging of the patient's brother showed a mild hypointensity in T2-weighted images in the dentate nuclei, a subtle lateral rim of hypointensity in the putamen and a mild white matter hyperintensity in the posterior frontal and parietal regions of the cerebral hemispheres. MR images of the two children were normal.

Discussion

MR imaging studies of aceruloplasminemia reported in the literature (3, 6–13) demonstrate a marked hypointensity on T2-weighted images in the basal ganglia and the dentate nuclei; these findings can be explained by marked iron deposition. The structures involved in the MR imaging studies reflect the specific sites of neurodegeneration seen at autopsy (6, 14) and explain the clinical findings. Cultures of neurons and glia indicate that ceruloplasmin is synthesized and secreted by astrocytes surrounding specific neurons mainly in the substantia nigra and basal ganglia, with kinetics identical to those observed in hepatocytes (5). The absence of ceruloplasmin is responsible for the iron accumulation, which probably causes neuronal degeneration through either a direct oxidant-mediated injury to the CNS or a glial cell-specific injury, with loss of glia-derived neurotrophic factors essential for neuronal survival (14).

The T2 hypointensities observed in our case were more marked and more widely distributed than those in other reported cases and may further characterize aceruloplasminemia. MR imaging abnormalities observed in the proband's mother were mild, of uncertain interpretation, and probably resulted because the study was performed with 0.5T equipment and standard spin-echo sequences. Furthermore, specific clinical and genetic studies were not performed in the patient's mother.

The mild, diffuse T2-hyperintensity observed in the white matter of the posterior part of the cerebral hemispheres, in the cerebellum, and in some white matter tracts may reflect degeneration of projection fibers from the involved deep nuclei to the cortex and vice versa, or of fibers connecting specific nuclei. Hyperintensity along the superior cerebellar peduncles, for example, may suggest degeneration of the fibers originating in the dentate nuclei that appear markedly involved by iron accumulation. This interpretation, however, is still speculative.

Although cerebral and cerebellar cortex involvement is described in neuropathologic reports (3, 6, 13), MR imaging hypointensity of the cortex has not been previously described, to our knowledge. The slight hypointensity of the superficial layers of the cerebral cortex and of the cerebellar cortex in T2-weighted spin-echo images were much more marked in the T2*-weighted gradient recalled-echo sequence which is more sensitive to the magnetic susceptibility effects of iron. The cortical involvement may support the hypothesis of direct expression of ceruloplasmin gene at these specific sites (2), or it may be secondary to a particularly marked iron overload.

In our case of aceruloplasminemia, the cortical hypointensities on T2-weighted images had some similarities to those observed in cases of superficial siderosis of the CNS due to repeated subarachnoid bleeding. However, T2-weighted images of superficial siderosis of the CNS usually show more marked hypointensity, which has a predilection for specific areas such as cerebellar cortex, brainstem, and cranial nerve VIII in the posterior fossa, sylvian fissure, and interhemispheric fissures in the supratentorial areas (15). More importantly, deep nuclei involvement is absent.

T2 hypointensities of the basal ganglia due to de-

posits of iron or other paramagnetic substances are characteristic of other neurodegenerative disorders such as Hallervorden-Spatz disease (HSD), multisystemic atrophy with prevalent parkinsonian signs (MSA-P), hereditary or secondary hemochromatosis, and Wilson disease. In HSD, iron deposition in the globus pallidus with the characteristic MR imaging appearance defined as the eye-of-the-tiger sign has been described (16, 17). Identification of the gene and the metabolic abnormalities involved in HSD has led to a new denomination proposed for HSD (i.e., pantothenate kinase–associated neurodegeneration). Hayflick et al (18) found the eye-of-the-tiger sign in all the patients they reviewed with mutations in the gene encoding pantothenate kinase 2. With MSA-P, T2 hypointensity on MR imaging is limited to the putamen. It is more marked in its posterior part and often associated with a thin, slitlike hyperintensity of its lateral margin (19, 20). In hereditary or secondary hemochromatoses, which are usually considered in the differential diagnosis, iron depositions do not usually occur in the basal ganglia. Only Nielsen et al (21) described a case of hereditary hemochromatosis with iron accumulation in the basal ganglia and the cerebellum. In secondary iron overload (transfusion-dependent β-thalassemia major or sideroblastic anemia), the central gray structures are spared, and T2 hypointensities are found in the pituitary gland and the choroid plexus, two structures not protected by the blood-brain barrier (22, 23). In Wilson disease, hypointensities in T2-weighted images are rare; when present, they are limited to the lentiform nucleus and the head of caudate nucleus, sometimes only to the putamen; a hyperintense halo surrounding the hypointensity may be observed (24, 25). In Wilson disease, basal ganglia and lateral thalamic hyperintensities with involvement of white matter tracts are more common. Treatment can precipitate iron deposition (26), and the contribution of copper to the hypointensities is unknown. T1-weighted images may also show hypointensity in the most severely affected nuclei; this is probably due to destructive changes (27). The T2 hyperintensities of the white matter observed in our patient were more subtle and uniform than those observed in advanced cases of Wilson disease (28). Although Wilson disease results in decreased serum ceruloplasmin level, the deficiency is not caused by mutations in the *Cp* gene, but rather, it is associated with mutations of another gene located on chromosome 13q.

Conclusion

We believe that this is the first report of the clear, *in vivo* MR imaging demonstration of cerebral cortical involvement in a patient with aceruloplasminemia. In addition to the marked T2 hypointensities in the basal ganglia and other deep nuclei, this finding, detected with T2*-weighted gradient recalled-echo sequences, may help to further characterize the disease. Determining the significance of the T2 hyperintensities described requires further study. Knowledge of the different distribution patterns of iron-related signal intensity abnormalities might make it possible to identify the different disorders characterized by iron deposition.

References

1. Miyajima H, Nishimura Y, Mizoguchi K, Sakamoto M, Shimizu T, Honda N. **Familial apoceruloplasmin deficiency associated with blepharospasm and retinal degeneration.** *Neurology* 1987;37:761–777
2. Harris LZ, Klomp WJ, Gitlin JD. **Aceruloplasminemia: an inherited neurodegenerative disease with impairment of iron homeostasis.** *Am J Clin Nutr* 1998;67:972–977
3. Kawanami T, Kato T, Daimon M, et al. **Hereditary caeruloplasmin deficiency: clinicopathological study of a patient.** *J Neurol Neurosurg Psychiatry* 1996;61:506–509
4. Kohno S, Miyajima H, Takahashi Y, Suzuki H, Hishida A. **Defective electron transfer in complexes I and IV in patients with aceruloplasminemia.** *J Neurol Sci* 2000;182:57–60
5. Klomp LWJ, Gitlin JD. **Expression of the ceruloplasmin gene in the human retina and brain: implications for a pathogenetic model in aceruloplasminemia.** *Hum Mol Genet* 1996;5:1989–1996
6. Morita H, Ikeda S, Yamamoto K, et al. **Hereditary ceruloplasmin deficiency with hemosiderosis: a clinicopathological study of a Japanese family.** *Ann Neurol* 1995;37:646–656
7. Okamoto N, Wada S, Oga T, et al. **Hereditary ceruloplasmin deficiency with hemosiderosis.** *Hum Genet* 1996;97:755–758
8. Miyajima H, Takahashi Y, Kamata T, Shimizu H, Sakai N, Gitlin JD. **Use of desferrioxamine in the treatment of aceruloplasminemia**. *Ann Neurol* 1997;41:404–407
9. Miyajima H, Fujimoto M, Kohno S, Kaneko E, Gitlin JD. **CSF abnormalities in patients with aceruloplasminemia.** *Neurology* 1998;51:1188–1190
10. Servan J, Elghozi D, Gaynot S, Duclos H. **Hémosidérose cérébrale liée à un déficit héréditaire en céruloplasmine.** *Rev Neurol* 1998;154:158–162
11. Daimon M, Moriai S, Susa S, Yamatani K, Hosoya T, Kato T. **Hypocaeruloplasminaemia with heteroallelic caeruloplasmin gene mutation: MRI of the brain.** *Neuroradiology* 1999;41:185–187
12. Loréal O, Turlin B, Pigeon C, et al. **Aceruloplasminemia: new clinical, pathophysiological and therapeutic insights.** *J Hepatol* 2002;36:851–856
13. Miyajima H, Kono S, Takahashi Y, Sugimoto M, Sakamoto M, Sakai N. **Cerebellar ataxia associated with heteroallelic ceruloplasmin gene mutation.** *Neurology* 2001;57:2205–2210
14. Gitlin JD. **Aceruloplasminemia.** *Pediatr Res* 1998;44:271–276
15. Bracchi M, Savoiardo M, Triulzi F, et al. **Superficial siderosis of the CNS: MR diagnosis and clinical findings.** *AJNR Am J Neuroradiol* 1993;14:227–236
16. Sethi KD, Adams RJ, Loring DW, el Gammal T. **Hallervorden-Spatz syndrome: clinical and magnetic resonance imaging correlations.** *Ann Neurol* 1988;24:692–694
17. Savoiardo M, Halliday WC, Nardocci N, et al. **Hallervorden-Spatz disease: MR and pathologic findings.** *AJNR Am J Neuroradiol* 1993;14:155–162
18. Hayflick SJ, Westaway SK, Levinson B, et al. **Genetic, clinical, and radiographic delineation of Hallervorden-Spatz syndrome.** *N Engl J Med* 2003;348:33–40
19. Savoiardo M, Girotti F, Strada L, Ciceri E. **Magnetic resonance imaging in progressive supranuclear palsy and other parkinsonian disorders.** *J Neural Transm* 1994;42:93–110
20. Horimoto Y, Aiba I, Yasuda T, et al. **Longitudinal MRI study of multiple system atrophy: when do the findings appear, or what is the course?** *J Neurol* 2002;249:847–854
21. Nielsen JE, Neerup Jensen L, Krabbe K. **Hereditary haemochromatosis: a case of iron accumulation in the basal ganglia associated with a parkinsonian syndrome.** *J Neurol Neurosurg Psychiatry* 1995;59:318–321
22. Duprez T, Maiter D, Cosnard G. **Transfusional hemochromatosis of the choroid plexus in β-thalassemia major.** *J Comput Assist Tomogr* 2001;25:487–488
23. Sparacia G, Banco A, Midiri M, Iaia A. **MR imaging technique for the diagnosis of pituitary iron overload in patients with transfusion-dependent β-thalassemia major.** *AJNR Am J Neuroradiol* 1998;19:1905–1907
24. Megalhaes ACA, Caramelli P, Menezes JR, et al. **Wilson's disease: MRI with clinical correlation.** *Neuroradiology* 1994;36:97–100

25. Savoiardo M, Grisoli M. **Magnetic resonance imaging of movement disorders.** In: Jankovic J, Tolosa E, eds. *Parkinson's Disease and Movement Disorders.* 3rd ed. Baltimore: Lippincott Williams & Wilkins, 1998;967–990
26. Engelbrecht V, Schlaug G, Hefter H, et al. **MRI of the brain in Wilson disease: T2 signal loss under therapy.** *J Comput Assist Tomogr* 1995;19:635–638
27. van Wassenaer-van Hall HN, van den Heuvel AG, Algra A, et al. **Wilson disease: findings at MR imaging and CT of the brain with clinical correlation.** *Radiology* 1996;198:531–536
28. van Wassenaer-van Hall HN, van den Heuvel AG, Jansen GH, et al. **Cranial MR in Wilson disease: abnormal white matter in extrapyramidal and pyramidal tracts.** *AJNR Am J Neuroradiol* 1995; 16:2021–2027