



Providing Choice & Value

Generic CT and MRI Contrast Agents



**FRESENIUS
KABI**

CONTACT REP

AJNR

Coil Thickness and Packing of Cerebral Aneurysms: A Comparative Study of Two Types of Coils

Marjan J. Slob, Willem Jan van Rooij and Menno Sluzewski

AJNR Am J Neuroradiol 2005, 26 (4) 901-903

<http://www.ajnr.org/content/26/4/901>

This information is current as
of July 8, 2025.

Coil Thickness and Packing of Cerebral Aneurysms: A Comparative Study of Two Types of Coils

Marjan J. Slob, Willem Jan van Rooij, and Menno Sluzewski

BACKGROUND AND PURPOSE: In coiling cerebral aneurysms, high packing prevents reopening over time. The purpose of this study was to compare packing of cerebral aneurysms treated with two types of coils with different wire thickness and different shapes.

METHODS: Packing, defined as the ratio between the volume of inserted coils and the volume of an aneurysm, was calculated for 144 cerebral aneurysms treated in 130 patients. Seventy-two aneurysms were treated with predominantly helical-shaped coils of 0.010-inch-diameter wire, and 72 aneurysms were treated with predominantly complex-shaped coils of 0.012-inch-diameter wire. Aneurysm volume was assessed from three-dimensional angiography. Aneurysm packing, inserted coil lengths, and numbers of coils were compared for both types of coils.

RESULTS: Mean packing was significantly higher (absolute value, 6.4%; relative value, 26.6%; $P < .0001$) in aneurysms coiled with 0.012-inch-diameter coils than aneurysms coiled with 0.010-inch-diameter coils. Inserted coil length per cubic millimeter of aneurysmal volume was equal for both types of coils.

CONCLUSION: Use of complex-shaped coils with a wire diameter of 0.012 inch to coil cerebral aneurysms results in significantly better packing than is achieved with helical coils of 0.010-inch-diameter wire.

Over time, about 25% of cerebral aneurysms treated with coils show reopening of the lumen (1–2). Compaction of coil mesh (decrease of interspaces between the loops of the coils leading to a smaller coil mesh) is the most important contributing factor, and this phenomenon is believed to be caused by the water-hammer effect of pulsatile blood flow. Previous studies (3–5) have shown that compaction strongly relates to packing density, defined as the ratio of inserted coil volume to the volume of an aneurysm. Nonthrombosed aneurysms packed for 24% or more did not show compaction at 6-month follow-up angiography (3).

Higher aneurysm packing can be obtained by inserting higher volumes of coils. The volume of inserted coils is dependant on both coil thickness and inserted coil length. Theoretically, with equal inserted coil length, thicker coils should lead to higher packing than thinner coils. If using thicker coils implies that inserted coil length would be substantially lower, however, this positive effect of coil thickness on pack-

ing could be reduced. In the present study, we retrospectively compared the packing of aneurysms treated with helical coils of 0.010-inch diameter to packing of aneurysms treated with complex coils of 0.012-inch diameter.

Methods

Between March 17, 2003, and January 29, 2004, 166 patients with 180 cerebral aneurysms were treated with endovascular methods in our hospital. Twenty-one patients with 21 aneurysms had been coiled previously, five patients with five aneurysms larger than 15 mm were treated with 0.018-inch coils, and eight patients with eight aneurysms were treated with parent vessel occlusion. The remaining 146 aneurysms in 132 patients were treated with either 0.010-inch coils (Guglielmi detachable coil 10 regular, soft, and ultrasoft, three-dimensional and helical; Boston Scientific, Fremont, CA) or 0.012-inch coils (TruFill DCS complex and helical; Cordis, Miami, FL). Coiling was performed by one of us (W.J.v.R. or M.S.), by using both types of coils in approximately equal numbers of patients. The choice of whether to use 0.010-inch or 0.012-inch coils was influenced by factors such as operator preference and availability of coils in stock, but the decision was independent of aneurysm or patient characteristics. In two of 132 patients (one in each group), the aneurysm ruptured during coiling and coils were placed outside the aneurysmal sac. These two patients were excluded from packing analysis but were included in assessment of procedure-related complications.

The present study group consists of 130 patients with 144 aneurysms. There were 88 women and 42 men with a mean age

Received June 24, 2004; accepted August 24.

From the Department of Radiology, St. Elisabeth Ziekenhuis, Tilburg, the Netherlands.

Address correspondence to Willem Jan van Rooij, MD, PhD, Department of Radiology, St. Elisabeth Ziekenhuis, Hilvarenbeekseweg 60, 5022 GC Tilburg, the Netherlands.

Comparison of relevant results between 72 aneurysms treated with coils of 0.010 inch wire diameter and 72 aneurysms treated with coils of 0.012 inch wire diameter

	0.010-inch Coils (GDC 10)	0.012-inch Coils (Cordis TruFill DCS)	P Value
Number of aneurysms	72	72	
Mean aneurysm volume	134.7 mm ³ (median 64, range 4-1.181 mm ³)	173.9 mm ³ (median 86, range 5-1245 mm ³)	=.27
Mean packing	24.1% (median 22.8, range 11.9-47.5%)	30.5% (median 30.5, range 17.0-57.0%)	<0.0001
Σ aneurysm volume	9700 mm ³	12,521 mm ³	
Σ coil length	3556 cm	4564 cm	
Coil length per mm ³ aneurysm	0.37 cm/mm ³	0.37 cm/mm ³	
Number of aneurysms with packing >24%	29 (40.3%)	55 (76.4%)	<.0001
Σ number of coils	303	320	
Aneurysm volume filled per coil	32.0 mm ³	39.1 mm ³	

of 53.2 years (median, 53.5 years; range, 19–81 years). Seventy-two of 144 aneurysms were treated with 0.010-inch coils; the other 72 aneurysms were treated with 0.012-inch coils. Of these 144 aneurysms, 110 had ruptured and 34 had not. Of the 110 ruptured aneurysms, 53 were treated with 0.010-inch coils and 57 with 0.012-inch coils. Of the 34 unruptured aneurysms, 15 were in addition to a ruptured aneurysm, 13 were truly incidental, two presented with clinical signs of mass effect, two with carotid-cavernous fistula, and two were coiled after failed surgery. The locations of the 72 aneurysms coiled with 0.010-inch coils were anterior communicating artery (20), posterior communicating artery (13), middle cerebral artery (9), basilar tip (8), carotid bifurcation (5), pericallosal artery (5), anterior choroidal artery (3), posterior inferior cerebellar artery (3), superior cerebellar artery (2), ophthalmic artery (1), vertebral junction (1), cavernous sinus (1), and posterior cerebral artery (1). The locations of the 72 aneurysms coiled with 0.012-inch coils were anterior communicating artery (26), posterior communicating artery (16), basilar tip (9), middle cerebral artery (3), posterior inferior cerebellar artery (3), superior cerebellar artery (3), anterior choroidal artery (3), pericallosal artery (2), anterior inferior cerebellar artery (2), carotid bifurcation (2), ophthalmic artery (1), vertebral artery (1), and posterior cerebral artery (1).

Coiling of aneurysms was performed on a biplanar angiographic unit (Integris BN 3000, Philips Medical Systems, Best, the Netherlands) with use of general anesthesia and systemic administration of heparin. Intravenously or subcutaneously administered heparin was continued for 48 hours after the procedure, followed by orally administered aspirin for 3 months. The aim of coiling was to pack the aneurysm as densely as possible, until not a single additional coil could be placed. With use of 0.010-inch coils, the first was generally a three-dimensional coil, followed by insertion of helical coils. With use of 0.012-inch coils, complex-shaped coils were inserted, except for 2- and 3-mm-diameter coils, because they were not available in complex shapes. For every aneurysm, the volume of the aneurysm, the volume of inserted coils, the total length of inserted coils, and the number of coils placed was assessed.

Volume of aneurysm was measured as follows: before the coiling procedure a rotational angiography with a 17-cm image intensifier was performed. A magnification of 33% of the initial 3D data set was reconstructed in a matrix of 256³. In this magnified three-dimensional reconstruction, the aneurysm was manually segmented from the parent artery and volume was calculated by using machine software. Volume of coils was calculated with a spreadsheet containing volume per centimeter for each type of coil. Packing was calculated as ratio of coil volume and aneurysm volume $\times 100\%$.

Mean aneurysm volume, packing, inserted coil length per cubic millimeter, and number of inserted coils were calculated and compared for both groups. Differences were statistically analyzed by using the unpaired *t* test for continuous variables with a normal distribution and Mann-Whitney U test for con-

tinuous variables, which are not normally distributed. A χ^2 test was used for categorical variables. Also, the proportion of aneurysms packed above 24% was assessed and compared for both groups. *P* values <0.05 were considered significant. Procedure-related complications leading to mortality or morbidity during hospital stay were assessed.

Results

Mean packing, aneurysm volume, inserted coil length per cubic millimeter of aneurysm, number of coils, and number of aneurysms with packing of more than 24% in both groups are listed in Table 1. There was no statistically significant difference in aneurysm volume in aneurysms treated with 0.010-inch coils versus 0.012-inch coils. Mean packing was significantly higher (absolute value, 6.4%; relative value, 26.6%) in aneurysms coiled with 0.012-inch coils than in aneurysms coiled with 0.010-inch coils. Proportion of aneurysms with packing of more than 24% was also significantly higher (absolute value, 36.1%; relative value, 89.6%) in aneurysms coiled with 0.012-inch coils. Inserted coil length per cubic millimeter of aneurysm was equal for both types of coils. The number of inserted coils was lower per filled aneurysm volume unit for aneurysms treated with 0.012-inch coils. Both types of coils show an inverse relation between aneurysm volume and packing (Fig 1).

Of the 132 patients treated with either type of coil, five patients (3.8%) suffered procedure-related complications leading to death or neurologic deficit during their hospital stay. Of these five patients, four were treated with 0.010-inch coils and one with 0.012-inch coils. This difference was not significant (*P* = 0.37).

Discussion

We found that complex-shaped coils with thickness of 0.012 inch packed significantly better than helical coils of 0.010 inch. This better packing can be explained by increased volume per coil length for thicker coils, because inserted coil length per cubic millimeter of aneurysm volume was found to be equal. The fact that equal lengths of 0.012-inch and 0.010-inch coils can be delivered per unit of aneurysm volume may be due to the complex shape of most inserted 0.012-inch coils, whereas most inserted

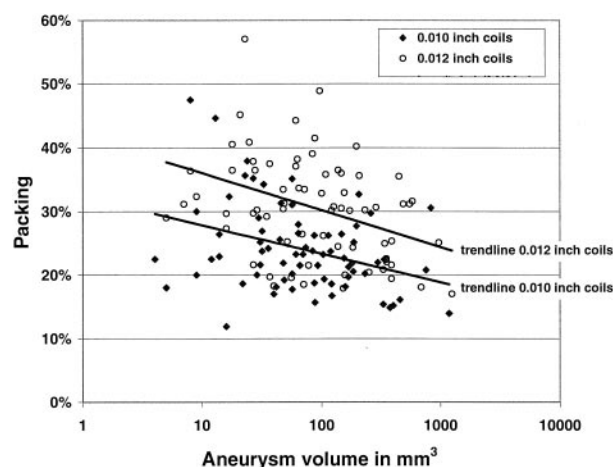


FIG 1. Graph showing the relation between aneurysm volume and packing. Aneurysm volume is a logarithmic scale. Packing is lower with larger aneurysm volumes for both types of coils. Difference in position of trend lines reflects difference in packing.

0.010-inch coils were helical. An experimental study has already shown that complex-shaped coils allowed better aneurysm filling than did helical coils of the same diameter (6). The proportion of aneurysms packed for more than 24% was significantly higher for 0.012-inch coils than for 0.010-inch coils (76% vs. 40%). In a previous study, we found that nonthrombosed aneurysms packed for 24% or more did not show compaction at 6-month follow-up angiography. Therefore, it is plausible that more aneurysms treated with 0.012-inch coils will remain stable over time compared with aneurysms treated with 0.010-inch coils, but this has yet to be proved and is subject to ongoing evaluation. We also found that fewer 0.012-inch coils were necessary to obtain a significantly better packing compared with 0.010-inch coils. Perhaps the complex-shaped 0.012-inch coils achieve better concentric filling of the aneurysm, thereby creating less dead space than helical shaped coils. This allows the operator to keep on by using larger diameter coils with complex—instead of helical—shapes to completely fill the aneurysm. Because larger coils are generally longer, fewer coils are needed.

A drawback of the present study is its retrospective and nonrandomized design. Aneurysm volumes were prospectively collected, however, and we are not aware of any selection bias in choosing type of coil in treatment of aneurysms. Possible errors in the measurement of aneurysm volume may have occurred as the result of differences in setting the threshold of the

3D data set and of manual segmentation of the aneurysm. In this study, aneurysm volume was measured by one of us (W.J.v.R. or M.S.), and threshold was set visually in conjunction with the histogram of the data set.

Recurrence of coiled cerebral aneurysms is probably related to a combination of factors—local hemodynamics, vessel geometry, the presence of intraluminal thrombus, and packing density. If it is shown that higher packing obtained with 0.012-inch coils in treatment of aneurysms leads to a reduction in reopening and retreatment rates compared with 0.010-inch coils, this will be an important step in improving the long-term stability of coiled cerebral aneurysms. We believe that future research should aim at finding optimal coil thickness and shape to obtain the highest possible packing and optimal mechanical occlusion of cerebral aneurysms. Coils coated with bioabsorbable material (7) might also contribute to better long-term results of coiled cerebral aneurysms, although in vivo evidence is lacking.

Conclusion

Coiling of cerebral aneurysms with complex-shaped 0.012-inch coils leads to significantly better packing than with helical-shaped 0.010-inch coils. Its impact on aneurysm recurrence remains uncertain but is the subject of ongoing evaluation.

References

1. Sluzewski M, van Rooij WJ, Rinkel GJ, Wijnalda D. Endovascular treatment of ruptured intracranial aneurysms with detachable coils: long-term clinical and serial angiographic results. *Radiology* 2003;227:720–724
2. Raymond J, Guilbert F, Weill A, et al. Long-term angiographic recurrences after selective endovascular treatment of aneurysms with detachable coils. *Stroke* 2003;34:1398–1403
3. Sluzewski M, van Rooij WJ, Slob MJ, et al. Relation between aneurysm volume, packing and compaction in 145 cerebral aneurysms treated with coils. *Radiology* 2004;231:653–658
4. Kawanabe Y, Sadato A, Taki W, Hashimoto N. Endovascular occlusion of intracranial aneurysms with Guglielmi detachable coils: correlation between coil packing density and compaction. *Acta Neurochir (Wien)* 2001;143:451
5. Tamatani S, Ito Y, Abe H, et al. Evaluation of the stability of aneurysms after embolization using detachable coils: correlation between stability of aneurysms and embolized volume of aneurysms. *AJNR Am J Neuroradiol* 2002;23:762–767
6. Piotin M, Iijima A, Wada H, Moret J. Increasing the packing of small aneurysms with complex-shaped coils: an in vitro study. *AJNR Am J Neuroradiol* 2003;24:1446–1448
7. Murayama Y, Tateshima S, Gonzalez NR, Vinuela F. Matrix and bioabsorbable polymeric coils accelerate healing of intracranial aneurysms: long-term experimental study. *Stroke* 2003;34:2031–2037