



Get Clarity On Generics

Cost-Effective CT & MRI Contrast Agents



**FRESENIUS
KABI**

[WATCH VIDEO](#)

AJNR

**Neuroimaging Clinics of North America:
Peripheral Neuropathies. Vol. 14, no. 1,
February 2004**

AJNR Am J Neuroradiol 2005, 26 (4) 981-982
<http://www.ajnr.org/content/26/4/981>

This information is current as
of August 12, 2025.

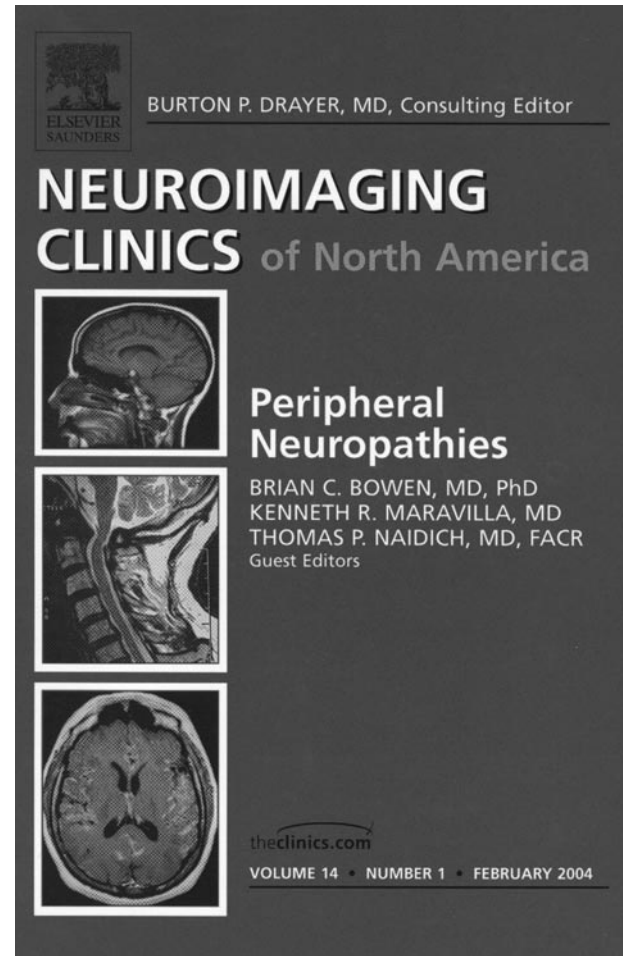
Neuroimaging Clinics of North America: Peripheral Neuropathies. Vol. 14, no. 1, February 2004

Brian C. Bowen, Kenneth R. Maravilla, and Thomas Naidich, guest editors. Philadelphia: Elsevier Saunders; 2004. 138 pages, 209 illustrations. \$84.

Imaging of the peripheral nervous system remains an art often lost between the subdisciplines of musculoskeletal and neuroradiology. For the trainee, acquiring a cohesive and systematic knowledge of peripheral nerve diseases and their imaging features can be challenging in light of the relatively limited number of cases and seemingly arbitrary assignment of studies to either musculoskeletal or neuroradiology sections. Imaging of peripheral nervous system disease, however, is becoming an increasingly valuable adjunct to neurologic examination and electrophysiologic studies, particularly as imaging technologies, especially MR imaging, become more adept at high-resolution anatomic and functional assessment of peripheral nerves. A systematic review of basic peripheral neuropathology and advanced peripheral neuroimaging techniques is therefore likely to benefit many radiologists who feel their training is limited in this area.

A succinct review of this kind is now provided with the recent addition of the *Neuroimaging Clinics of North America* volume *Peripheral Neuropathies*, edited by Drs. Bowen, Maravilla, and Naidich, all leaders in neuroradiology with expertise in the peripheral nervous system. One of the many benefits of having these individuals edit (as well as contribute to) this volume is that, on the whole, it is well written, well illustrated, and understandable. The images in each chapter range from good to impressive and are almost never superfluous. The exception lies with the last chapter, by Grant et al, which recapitulates much of what is already shown in previous chapters, although this chapter contains perhaps the most impressive images yet. And indeed, their images serve to illustrate a major theme emphasized throughout the book: special care and attention must be applied to the techniques used to acquire images of peripheral neuropathology to obtain information that has diagnostic utility. The technical finesse used to obtain images of nerve inflammation in the setting of cervical radiculopathy in Grant et al's chapter, for example, are inspiring, prompting us to consider the future possibility of more specific interpretations of neuropathology in the setting of degenerative spine disease, particularly as higher-field-strength magnets are incorporated into clinical practice.

This volume is organized to cover everything from embryogenesis of the peripheral nervous system to basic peripheral neuropathology and review of those regions where peripheral neuropathology is most commonly imaged—namely, the brachial plexus and the carpal tunnel. The first chapter on embryogenesis is the one contribution that is not integrated well into the remaining chapters. The chapter clocks in at 42



pages, or just less than one-third of the entire volume, and adds little to our relevant understanding of peripheral neuropathology. A more appropriate contribution may have distilled the review of basic embryology, instead tying our growing understanding of neural development into a discussion of what we now know about peripheral nerve regeneration. The basic biology of neural regeneration will undoubtedly serve as a foundation for new clinically relevant functional and molecular imaging techniques in peripheral nervous system disease. Any future compilation on peripheral neuropathy should include this type of discussion.

The two chapters on basic pathology and clinical presentation of peripheral neuropathies are succinct and provide useful reviews that should enhance radiologists' interpretation of imaging findings and discussion of clinical cases with referring physicians. In the chapter on basic pathology, by Ruching and Bouf-

fard, excellent images guide us through normal anatomy and various forms of nerve pathology. Notable, however, is the short shrift given to the histopathology of traumatic nerve injury and the minimal discussion of radiation neuropathology, two major categories of peripheral neuropathology for which imaging studies are commonly performed. Readers seeking a concise review on the basic pathology and clinical presentation of traumatic and radiation nerve injuries will have to cull this information piecemeal from subsequent chapters.

The most comprehensive chapter in the book is presented by Bowen et al on the brachial plexus. This clear discussion of normal anatomy, pathology, and MR imaging features provides a very readable review on the subject that I anticipate resorting to in the future. The images are excellent—indeed, the authors stress appropriately the care necessary to obtain high-quality MR images, and they review techniques that may aid in the acquisition of diagnostically useful images. Perhaps the only minor criticism of this chapter is this reader's wish for more detail on the types of surgical repairs performed following traumatic plexus injury. The authors spend adequate time discussing the various forms of injury and distinguishing imaging features that aid the surgeon, yet a slightly more detailed discussion of what is actually done to restore function (neurolysis, nerve grafting, neurotization, and so forth) and when these procedures are per-

formed would only enhance interpretation skills and the quality of our discussions with referring physicians.

The chapters on carpal tunnel pathology are straightforward and readable and are more likely to benefit the newly minted radiologist just entering general practice. The chapter on sonography interrogation of carpal tunnel anatomy and pathology is important because, by virtue of sonography's diagnostic accuracy in this region, it reminds us once again that the most important aspect of our practice is to do what is best for the patient, not simply to perform the most expensive and fanciest examination. A caveat of sonography, however, is its dependence, especially in extremity imaging, on both the skill of the sonographer and of the interpreting radiologist. What is diagnostically accurate in one practice may be unacceptably off the mark in another.

Overall, this latest addition to the *Neuroimaging Clinics of North America* series is welcome and should serve to remind neuroradiologists that imaging of the peripheral nervous system, though in its infancy, can and should become a larger part of our practice. It also reminds us that there are many opportunities to develop new, clinically relevant methods for imaging peripheral neuropathy. Although some contributions in this volume are of questionable relevance or redundant, *Peripheral Neuropathies* should nonetheless prove a useful resource for both the academic and private practice radiologist.