



Discover Generics

Cost-Effective CT & MRI Contrast Agents



WATCH VIDEO

AJNR

Outcomes of Carotid Angioplasty and Stenting for Radiation-Associated Stenosis

Paul Harrod-Kim, Yasha Kadkhodayan, Colin P. Derdeyn, DeWitte T. Cross III and Christopher J. Moran

AJNR Am J Neuroradiol 2005, 26 (7) 1781-1788

<http://www.ajnr.org/content/26/7/1781>

This information is current as of June 24, 2025.

Outcomes of Carotid Angioplasty and Stenting for Radiation-Associated Stenosis

Paul Harrod-Kim, Yasha Kadkhodayan, Colin P. Derdeyn, DeWitte T. Cross III, and Christopher J. Moran

BACKGROUND AND PURPOSE: In light of their high surgical risk, carotid angioplasty and stent placement may be preferred in patients with radiation-associated carotid stenosis. The purpose of this study was to determine the procedural complication rate, patency, and clinical outcomes after carotid angioplasty and stent placement in this small group of high-risk patients.

METHODS: Sixteen patients (mean age, 65 years; 5 women and 11 men) who received radiation therapy for head and/or neck malignancy subsequently developed carotid stenosis (mean, 84%; range, 70%–99%) in a total of 19 carotid arteries, which were treated with angioplasty and stent placement. The patients were followed for a mean time of 28 months (range, 5–78 months) with periodic Doppler studies, angiography, CT angiography, or clinically.

RESULTS: In the total 19 stented carotid arteries, 23 procedures were performed (22 stent placement procedures and one repeat angioplasty). The procedural stroke rate was 1/23 (4%). The procedural transient ischemic attack rate was 0/23 (0%). There was one other observed complication: a puncture site hematoma. The 30-day postprocedure complication rate was 0/23 (0%); no neurologic symptoms were reported. Fifteen of the 19 vessels (79%) developed no new stenosis throughout the follow-up period. Two of 19 (11%) vessels had repeat angioplasty and stent placement; 1/19 (5%) had a repeat angioplasty. One restented vessel has remained patent for 50 months. Another restented vessel required a third stent placement 17 months after the second. Two of 19 (11%) vessels occluded per Doppler examination 14 and 22 months postprocedure.

CONCLUSION: Angioplasty and stent placement have low rates of complications and restenosis in the treatment of radiation-associated carotid occlusive disease.

Cerebrovascular disease is the third-leading cause of mortality in the United States (1, 2). Approximately 25% of strokes are caused by carotid occlusive disease. Currently, the standard treatment for extracranial carotid occlusive disease is carotid endarterectomy (CEA; 3). In 1991, the North American Symptomatic Carotid Endarterectomy Trial (NASCET) demonstrated the unequivocal benefit of endarterectomy over medical management in symp-

tomatic patients with severe carotid stenosis of at least 70% (17% absolute risk reduction of ipsilateral stroke over 2 years). More recently, the benefit of carotid endarterectomy in patients with symptomatic but more moderate stenosis of 50%–69% has been reported (6.5% absolute risk reduction of ipsilateral stroke over 5 years) (4). Carotid angioplasty and stent placement, however, have become increasingly used during the past two decades and are gaining wider acceptance.

A few multicenter randomized trials comparing carotid endarterectomy with angioplasty and stent placement have been inconclusive. The Carotid and Vertebral Artery Transluminal Angioplasty Study (CAVATAS) did not show a significant difference in stroke or death rate between the two techniques (5). The Wallstent trial was stopped prematurely because of safety considerations in the angioplasty and stent placement group (6). Stent placement and Angioplasty with Protection in Patients at High Risk for Endarterectomy (SAPPHIRE) found that carotid

Received November 30, 2004; accepted after revision March 27, 2005.

From the Department of Interventional Neuroradiology, Mallinckrodt Institute of Radiology (P.H.-K., Y.K., C.P.D., D.T.C., C.J.M.), and the Departments of Neurological Surgery (C.P.D., D.T.C., C.J.M.) and Neurology (C.P.D.), Washington University School of Medicine, St. Louis, MO.

Address correspondence to Christopher J. Moran, MD, Department of Interventional Neuroradiology, Mallinckrodt Institute of Radiology, Washington University School of Medicine, 510 South Kingshighway Boulevard, St. Louis, MO 63110.

© American Society of Neuroradiology

TABLE 1: Clinical characteristics

Pt	Age/Sex	Malignancy	Interval (years)	Neurological Symptoms	Radical Neck Dissection	Prior CEA (months before stenting)	Other Vessel Occlusions*
1	62/F	Parotid	3	TIA	Yes	No	LICA
2	61/M	Laryngeal	15	Stroke	Yes	No	RICA, R vert
3	57/M	Pituitary	22	TIA	No	Bilateral (2)	
4	68/F	Thyroid	21	TIA	Yes	No	
5	66/M	Head and neck	17	TIA	Yes	No	
6	68/M	Oral	1	None	Yes	Contralateral (13)	
7	77/M	Laryngeal	5	TIA	Yes	No	
8	76/F	Glomus tumor	1	None	No	Bilateral (60)	L vert
9	68/M	Oral	12	TIA	No	No	
10	68/M	Lymphoma	3	Stroke	No	No	
11	56/M	Tonsillar	4	TIA	Yes	No	
12	56/M	Head and neck	2	TIA	Yes	No	
13	54/F	Lymphoma	23	None	No	No	
14	52/M	Laryngeal	1	Syncopal	Yes	No	R vert
15	73/M	Head and neck	7	TIA	Yes	No	L vert
16	79/F	Head and neck	3–13	None	Yes	Contralateral (83)	

Note.—Pt indicates patient; Interval, time from radiation therapy to neurological symptoms; CEA, carotid endarterectomy; TIA, transient ischemic attack; R, right; L, left; ICA, internal carotid artery; vert, vertebral artery.

* Untreated.

stent placement with a cerebral protection device was not inferior to endarterectomy in a population of high-risk patients (7).

Although it did not randomize patients, the ARChER (Acculink for Revascularization of Carotids in High-Risk patients) study is the basis for the only FDA-approved stent. The study included nearly 600 patients distributed among 3 arms: ARChER 1 used the stent on its own, ARChER 2 used the stent plus embolic protection, and ARChER 3 used a new catheter altogether. At 1 year, the rates of major adverse events were 8.3% and 10.2% for ARChER 1 and 2, respectively (data for ARChER 3 are not yet available) compared with 14.5% for surgery patients (8). The Carotid Revascularization Endarterectomy versus Stent Trial and the International Carotid Stent placement Study (ICSS, or CAVATAS-2) are ongoing.

Radiation-associated carotid stenosis is more difficult to treat surgically because of periarterial scarring, ill-defined planes of dissection, risk of scar disruption, prosthetic infection, anastomotic breakdown and restenosis, long lesion length, and increased rate of wound complications (9, 10). For these reasons, percutaneous transluminal angioplasty and stent placement may be the preferred method of revascularization in patients who have undergone radiation therapy to the head or neck regions; however, these patients are excluded from clinical trials because of the surgical risks and possible reduced life expectancy. This is a prospective study of the procedural complication rate, patency, and clinical outcomes after carotid angioplasty and stent placement in patients with radiation-associated carotid occlusive disease.

Methods

Since November 1996, 16 patients with a history of head and/or neck malignancy treated with radiation therapy were

referred to our department for diagnosis and treatment of carotid occlusive disease (Table 1). Institutional review board approval was obtained for the study and written informed consent was obtained for the procedure.

All patients underwent a diagnostic cerebral angiogram on a dedicated biplanar neuroangiographic unit (Neurostar; Siemens, Munich, Germany) to document high-grade carotid stenosis (>70% according to NASCET) in either the internal carotid artery (ICA) or common carotid artery (CCA). Transfemoral access was used for all patients. Patients were premedicated with aspirin 325 mg orally each day 5 days before the procedure through 1999 (9 procedures). All subsequent procedures were performed by using clopidogrel bisulfate 75 mg (Plavix; Bristol-Myers Squibb/Sanofi Pharmaceuticals Partnership, NY) orally each day in addition to aspirin. The activated clotting time was maintained between 250 and 300 seconds with heparin during the procedure.

Following a diagnostic cerebral angiogram, the diagnostic catheter was exchanged for a 6-, 7-, or 8F Shuttle sheath (Cook, Bloomington, IN) placed in the carotid artery proximal to the stenosis. In patient 15, the Shuttle sheath could not be advanced because of the acuity of the angle of the proximal left CCA from the aortic arch and because the proximal location of the common carotid stenosis prevented purchase for the exchange. Therefore, a 5F HN4 catheter (Cook) was used to select the left CCA. Through this catheter, a Prowler Plus microcatheter (Cordis Corp., Miami Lakes, FL) and a Transcend 14 guidewire (Boston Scientific, Natick, MA) were used to catheterize and cross the left carotid stenosis. The Transcend 14 was then replaced by a 0.018-inch exchange length guidewire (Roadrunner; Cook) over which the angioplasty and stent placement were performed after removal of the HN4 and Prowler catheters. Intravenous atropine or glycopyrrolate (American Regent, Shirley, NY) was administered to the 14 patients who had not undergone prior ipsilateral carotid endarterectomy for prophylaxis of bradycardia.

In all but 3 patients, balloon angioplasty was performed before stent deployment. A total of 22 self-expanding stents were used: 9 Smart stents (Cordis), 6 Precise stents (Cordis), and 7 Wallstents (Boston Scientific). In patient 7, tortuosity in the proximal left CCA prevented placement of a Smart stent, so a balloon-expandable coronary stent (NIR; Boston Scientific) was used. Except for patient 5's right ICA (stented with a Smart stent), patients 1–6 (Table 2, in chronological order) received a Wallstent for their first or only procedure (last

TABLE 2. Results of carotid angioplasty and stenting for radiation-associated stenosis

Pt	Vessel	Stenosis (%)	Stent	Size (mm)	Across Bifurcation	Pre-stent Angiography	Post-stent Angiography	F/u (mo)	Neurological Symptoms after Stenting	Imaging Outcome
1	RICA	75	Wallstent	8 × 20	No	Yes	Yes	None		
2	LICA	85	Wallstent	8 × 40	Yes	Yes	Yes	61	TIA	Restented
		70	Precise	7 × 20	No, LCCA	Yes	No	17	No	Restented
		75	Precise	7 × 40	No, LCCA	No	Yes			
3	RCCA	90	Wallstent	10 × 42	No	Yes	Yes	76	No	Patent
4	LCCA	70	Wallstent	8 × 40	No	No	Yes	55	No	Patent
5	LICA	80	Wallstent	10 × 40	No	Yes	Yes	13	No	Restented
		70	Wallstent	6 × 20	No	Yes	Yes	50	No	Patent
	RICA	99	Smart	8 × 40	No	Yes	Yes	22	No	Occluded
6	RICA	75	Wallstent	6 × 20	Yes	Yes	Yes	22	No	Patent
7	LCCA	70	NIR	4 × 18	No	No	Yes	14	Stroke*	Occluded
8	RICA	95	Smart	6 × 60	Yes	Yes	Yes	34	No	Patent
9	LICA	80	Smart	10 × 20	No	Yes	No	32	No	Patent
10	LICA	75	Smart	10 × 20	No	Yes	Yes	11	No	Patent
	RICA	95	Smart	6 × 20	No	Yes	No	7	No	Patent
11	RICA	95	Smart	9 × 30	No	Yes	Yes	9	No	Patent
	LICA	85	Smart	10 × 40	No	Yes	No	8	No	Patent
12	LICA	99	Smart	9 × 40	No	Yes	No	16	No	Reangioplasty
13	RICA	90	Smart	9 × 30	Yes	Yes	No	11	No	Patent
14	LCCA	90	Precise	8 × 30	No	Yes	No	None		
15	LCCA	95	Precise, × 2	6 × 40, 6 × 20	No	Yes	No	12	No	Patent
16	LICA	80	Precise	8 × 20	No	Yes	No	5	No	Patent

Note.—Pt indicates patient; F/u, follow-up; R, right; L, left; ICA, internal carotid artery; CCA, common carotid artery; TIA, transient ischemic attack. Wallstent, NIR (Boston Scientific Corp., Natick, MA); Smart, Precise (Cordis Corp., Miami Lakes, FL).

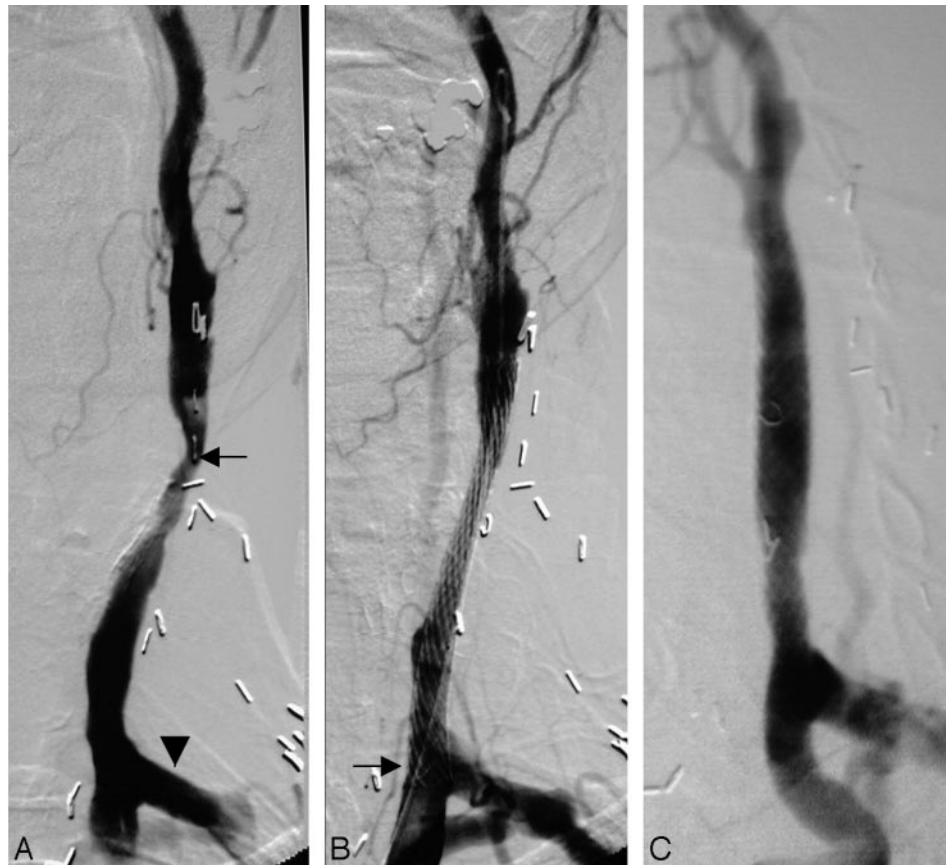
* Stroke occurred shortly after patient developed atrial fibrillation.

FIG 1. A case of long-term stent patency in patient 4, a 68-year-old woman with thyroidectomy for carcinoma followed by postoperative radiation, bilateral radical neck dissection, and permanent tracheostomy, who experienced transient ischemic changes in the left cerebral hemisphere 21 years after radiation therapy. The patient had a history of graft placement between her left CCA and left subclavian arteries (5 years before admission) as well as a right CCA vein graft bypass (10 years before admission).

A, Digital subtraction angiography (DSA) reveals a 70% stenosis (arrow) of the distal left CCA. Note the bypass graft (arrowhead) between the left CCA and left subclavian arteries.

B, Successful stent placement with little residual stenosis. The proximal end of the 8 × 40 mm Wallstent (Boston Scientific, Natick, MA) extends across the origin of the left subclavian graft (arrow). Poststent angioplasty with an 8 × 40 mm Olbert balloon (Boston Scientific) resulted in rupture of the balloon.

C, Repeat DSA 4.5 years after stent placement shows a patent carotid artery with interval auto expansion of the stent.



Wallstent used in May 1999). The Smart or Precise stent was adapted in lieu of the Wallstent because their cell characteristics allowed for abrupt changes in stent lumen diameter. The stents were oversized by 1–2 mm to the largest diameter of the artery to be treated. Thirteen stent placements were followed by balloon angioplasty. Poststent angioplasty was not performed in vessels that were sufficiently dilated with initial angioplasty and stent placement. No cerebral protection device was used. Intracranial images were routinely obtained before and after the intervention, to confirm patency of intracranial vessels.

Femoral hemostasis was obtained by using 4 Perclose devices (Abbott Laboratories, Abbott Park, IL) in 4 procedures on 3 patients and by using 2 AngioSeal devices (St. Jude Medical, St. Paul, MN) in 2 procedures on one patient. Manual compression was used in the remaining 17 procedures after the activated clotting time had returned to normal. Patients were monitored in the intensive care unit following the procedure with mean arterial pressure maintained within 20 mm Hg above or below baseline. They were discharged the following day, with the exception of the one patient, who suffered a periprocedural stroke. Aspirin and Plavix were continued for 30 days following the procedure, and aspirin was continued for life.

The patients' medical records were obtained from their referring physicians. Follow-up consisted of periodic carotid Doppler studies, repeat cerebral angiograms, CT angiography (CTA), or clinical history and physical examinations.

Results

Of the 16 patients, 5 were women and 11 were men, with ages ranging from 52 to 79 years (mean, 65 years). The interval from radiation therapy to carotid stent placement ranged from 1 to 23 years. Eleven of

16 (69%) patients had neurologic symptoms consistent with carotid disease: 9 transient ischemic attacks (TIAs) and 2 strokes (Table 1). Three patients (5, 10, and 11) had bilateral carotid stenoses that were treated separately. The first vessels were treated for symptomatic lesions followed (after 2, 4, and 1 month, respectively) by treatment of asymptomatic lesions on the contralateral side, making 19 treated vessels (14 ICAs and 5 CCAs). In the total 19 stented vessels, 23 procedures were performed: 22 stent placement procedures and 1 repeat angioplasty (Table 2). The mean stenosis was 84% (range, 70%–99%). One patient was treated with 2 stents (patient 15). One patient had 30% residual stenosis (patient 3), with the remaining procedures leaving minimal or no residual stenosis.

The procedural stroke rate was 1/23 (4%). Patient 4 developed a small left parietal infarct immediately after the procedure because of rupture of a poststent angioplasty balloon despite inflation pressure below the maximum recommendations (Fig 1). Immediate repeat left carotid angiography showed a widely patent left CCA and ICA with no intracranial emboli. It was not known whether foreign material or other embolus was responsible. The patient was transferred to a rehabilitation facility 13 days postprocedure with mild weakness of the right arm and leg along with mild speech difficulty, which resolved completely over the following month. The procedural TIA rate was 0/23 (0%). Patient 3 developed a 14-cm postproce-

TABLE 3: Summary

Total procedures	23
	22 angioplasty and stenting
	1 angioplasty
Procedural stroke rate	1/23 (4%)
Procedural TIA rate	0/23 (0%)
30-day stroke/TIA rate	0/23 (0%)
Total vessels stented	19
Vessels remaining patent	15/19 (79%)
	2 repeat angioplasty and stenting
	1 restenosis at distal stent margin
	1 at proximal stent margin (a third procedure was done for proximal stent margin stenosis with concurrent in-stent stenosis)
	1 repeat angioplasty (without stent placement)
	restenosis at distal stent margin
Vessels occluded	2/19 (11%)
Vessels lost to follow-up	2/19 (11%)

Note.—TIA indicates transient ischemic attack.

ture right groin hematoma that resolved without treatment or transfusion. There were no other procedural complications, including no retroperitoneal hemorrhages, infections, or cranial nerve palsies. The 30-day postprocedure complication rate was 0/23 (0%); no neurologic symptoms were reported.

The mean follow-up was 28 months (median, 16 months; range, 5–78 months). Of the 19 vessels stented, 15 (79%) remained patent (<50% stenosis) throughout the follow-up period (Table 3). Two of 19 (11%) vessels had repeat angioplasty and stent placement. Most the recurrent stenoses have not been at the initial site of angioplasty but rather at the proximal or distal ends of the stent. Patient 5 developed a new 70% stenosis at the distal margin of the first stent by 13 months. This has remained patent for 50 months following the repeat procedure. Patient 2 required 2 repeat angioplasty and stent placement procedures (Fig 2). The first repeat procedure was done at 61 months for a new 70% stenosis at the proximal margin of the original stent. A third procedure 17 months later resulted in a third stent placed for a new 75% stenosis at the proximal margin of the second stent. The third stent also traversed a 75% in-stent stenosis. One of 19 (5%) had a repeat angioplasty with minimal residual stenosis without the placement of a second stent (patient 12). As in patient 5, this was also done for a new stenosis at the distal margin of the first stent. Repeat procedures were performed when >70% restenosis was found on routine imaging, except for patient 2's first repeat procedure, which was performed for recurrent TIA at 61 months. In summary, of the 4 treated restenoses, there were 2 at the distal stent margin, one at the proximal stent margin, and one at the proximal stent margin with concurrent in-stent stenosis.

Two of 19 (11%) vessels occluded per Doppler examination 14 and 22 months postprocedure (patients 2 and 7). Before documented occlusion, patient

7 had a left hemisphere stroke at 14 months shortly after developing atrial fibrillation. Two patients (one carotid artery in each patient [1 and 14]) were lost to follow-up. Patient 1 died of metastatic adenocarcinoma 12 months after the stent placement of her right ICA. Aside from patients 2 and 7, noted above, no new neurologic symptoms were reported during the follow-up period. All patients were followed with periodic carotid Doppler studies, repeat cerebral angiograms, or CTA, with the exception of patients 9 and 15. These 2 were followed clinically, because imaging studies were not performed to confirm patency.

Discussion

The effects of radiation on normal tissue were investigated at the time of its initial widespread therapeutic use in the early 1940s. Warren discussed extensively the cardiovascular changes associated with radiation (11). Extensive animal studies have demonstrated that radiation induces changes consistent with atherosclerosis: intimal proliferation, selective disruption of the internal elastic lamina, and necrosis in both small and large vessels (12–14).

Many studies in humans have demonstrated increased prevalence of carotid occlusive disease in patients who have received local radiation therapy (15–20). Most recently, a study of 40 patients who had received cervical radiation for head and neck cancer found that 16 (40%) patients had significant (>50%) carotid artery stenosis (20). Six of these patients had unilateral complete carotid occlusion, and 6 had significant bilateral carotid stenosis. Three had sustained a stroke after radiation therapy. Another study, by Elerding et al, of 910 patients surviving at least 5 years after neck irradiation for Hodgkin disease, non-Hodgkin lymphoma, or primary head and neck neoplasm found the incidence of stroke was 6.9% (63 patients) during a mean observation period of 9 years (21). The expected number of strokes per 1000 people in the general population over the same time period is 38 (22). These studies demonstrate that the prevalence of carotid disease in this population is clinically significant and requires follow-up to determine if and when intervention becomes necessary.

The benefits of carotid endarterectomy in general were demonstrated by NASCET. In the case of asymptomatic disease, the Asymptomatic Carotid Atherosclerosis Study (ACAS) estimated the 5-year risk of ipsilateral stroke and any perioperative stroke or death in good surgical candidates with carotid artery stenosis of 60% or greater was 5.1% versus 11.0% in medically treated patients. This study is the basis for surgical treatment of asymptomatic disease in good surgical candidates (23).

In the case of radiation-associated disease, a series of 24 patients treated surgically has been reported (24). In this study, 20 of the 24 patients underwent standard carotid endarterectomy, 2 underwent external carotid endarterectomy, one underwent aortocarotid bypass, and one had a saphenous vein bypass. Following the procedure, 6 patients demonstrated

FIG 2. A case of multiple restenting in patient 2, a 61-year-old man with bilateral radical neck dissection and external beam radiation for laryngeal cancer 15 years before right cerebral hemisphere stroke due to right ICA occlusion.

A, DSA shows an 85% ulcerated stenosis (arrow) of the proximal left ICA.

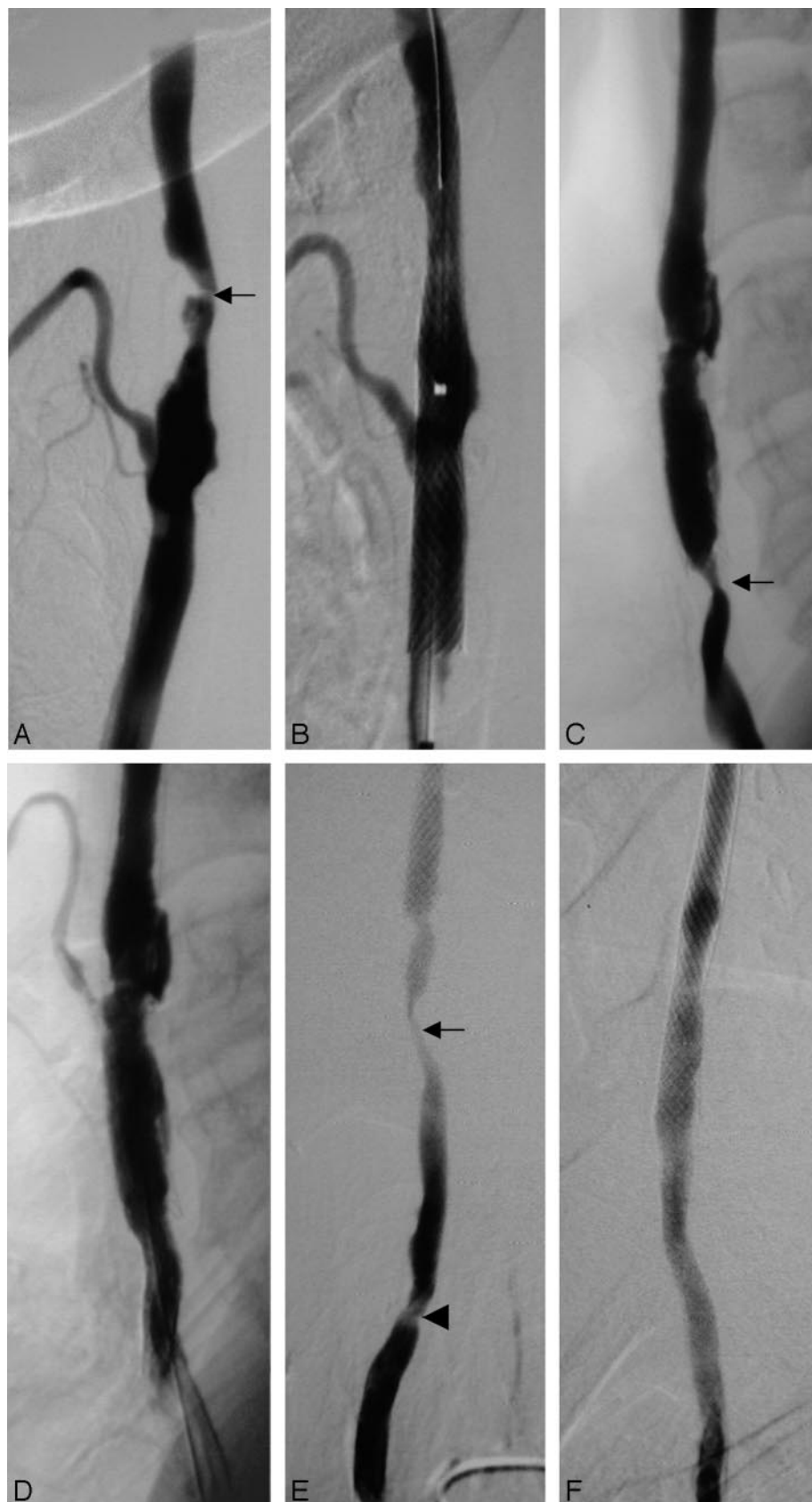
B, DSA after angioplasty and stent placement shows little residual stenosis. Prestent angioplasty was performed with a 4×20 mm Symmetry balloon (Boston Scientific). This was followed by placement of an 8×40 mm Wallstent (Boston Scientific). Poststent angioplasty was performed by using an 8×40 mm Olbert balloon (Boston Scientific).

C, Repeat DSA 5 years after stent placement shows 70% restenosis (arrow) in the distal left CCA at the inferior margin of the stent. The external carotid artery no longer fills.

D, DSA after angioplasty and stent placement with a 5×20 mm Savvy balloon (Cordis Corp., Miami Lakes, FL) followed by a 7×20 mm Precise stent (Cordis). There is minimal filling of the external carotid artery.

E, DSA 17 months later shows a focal high-grade in-stent restenosis (arrow) and a less severe stenosis in the CCA (arrowhead).

F, Immediate DSA following placement of a third stent (7×40 mm Precise; Cordis) and poststent angioplasty with a 6×40 Savvy balloon (Cordis) shows a good angiographic result.



transient cranial nerve palsies, one patient had a postoperative hematoma, which did not require evacuation, and two patients suffered postoperative wound

infections. Follow-up ranged from 1 to 156 months, with only 6 of the 24 patients having a follow-up period longer than 18 months. No patients suffered

any neurologic events during their follow-up. Duplex scan examination documented one occlusion 1 month postprocedure and one restenosis that required a second operation. The remainder of the grafts were widely patent. Although this study did not show a high rate of procedural complications, it is acknowledged that in this population of patients, radiation-induced scarring and previous neck dissections complicate the surgical treatment.

Of the 16 patients in the present study, 11 had prior radical neck dissections, and 4 had prior CEA. A recent study comparing 124 repeat CEAs with 265 primary CEAs has shown that repeat CEA carries a higher rate of perioperative stroke (4.8% vs 0.8%; $P = .015$) and cranial nerve injury (17% vs 5.3%; $P < .001$) (25). The 4 patients in this study with prior CEAs had an uncomplicated periprocedure course with patent vessels through their follow-up period.

Our results have been echoed in three recent studies. In a series of 14 patients, one patient suffered a periprocedural stroke but recovered completely in 2 days (26). There were no other procedural complications. At 6 months postprocedure, nine (64%) patients demonstrated $<50\%$ stenosis on carotid Doppler studies, and no patients had any neurologic events. At 18 months, 3 patients had died of unrelated causes, and the others remained asymptomatic. Another study reported 7 patients with 10 treated vessels (27). Six of 7 patients were symptomatic; 4 of 7 had undergone previous radical neck dissection. There was no evidence of early restenosis after a mean follow-up of 8 months. Most recently, in a series of 16 patients who underwent 17 procedures, one postprocedure stroke occurred as a result of thromboembolism to the ipsilateral middle cerebral artery and led to hospital death; there was also one TIA (28). There were 3 recurrent stenoses on duplex scan and one repeat angioplasty with no new neurologic events over a median 30-month (range, 5–55 months) follow-up.

The procedures in this study were performed before the widespread availability of cerebral protection devices. The rate of ischemic complications, however, was low (4% procedural, 0% at 30 days) in these postradiation, symptomatic and asymptomatic, NASCET-excluded patients. Fifteen of 19 vessels (79%) were widely patent as demonstrated by Doppler examination, angiography, or CTA, and the patients remained free of new neurologic symptoms at the end of a mean follow-up period of 28 months.

The benefit of using cerebral protection devices has not been demonstrated in this population, and their use is not without complications. It may not be possible to cross a high-grade stenosis with a filter or balloon-type protection device, and doing so may result in complete occlusion or dissection. In these instances, a nonlesion-crossing balloon device such as the Parodi antiembolism system (W. L. Gore and Associates, Newark, DE) may be of value. Future studies are necessary to show the impact of such devices on the procedural complication rate in this subgroup of patients.

A limitation of the study is its small size (23 pro-

cedures and 16 patients). Also, in any study of head and neck cancer patients, another difficulty is obtaining long-term follow-up in view of their comorbidities. In our series, one patient died of her malignancy before follow-up was obtained.

Conclusion

In light of the evolution of self-expandable stents, the use of carotid angioplasty and stent placement has increased rapidly. Although it is clear that endarterectomy is preferred to medical management, the benefit of endovascular stent placement versus endarterectomy remains unclear in the general population. In the population of patients treated with neck irradiation who were excluded from NASCET, angioplasty and stent placement may be preferred in light of the difficulty of surgical management. In this population, the procedure was safe and effective with few complications and good midterm results.

References

1. National Advisory Neurological Disorders and Stroke Council. *Stroke and cerebrovascular disease. Status report: decade of the brain*. Bethesda, MD: National Institutes of Health, 1992:26–27
2. Bonita R, Beaglehole R. **Stroke: populations, cohorts and clinical trials**. In: Whisnant JP, ed. *Stroke mortality*. Oxford: Butterworth-Heinemann;1993:59–79
3. Zarins CK. **Carotid endarterectomy: the gold standard**. *J Endovasc Surg* 1996;3:10–15
4. Barnett HJ, Taylor DW, Eliasziw M, et al. **Benefit of carotid endarterectomy in patients with symptomatic moderate or severe stenosis: North American Symptomatic Carotid Endarterectomy Trial Collaborators**. *N Engl J Med* 1998;339:1415–1425
5. Brown MM, Rogers J, Bland JM, et al. **Endovascular versus surgical treatment in patients with carotid stenosis in the Carotid and Vertebral Artery Transluminal Angioplasty Study (CAVATAS): a randomised trial**. *Lancet* 2001;357:1729–1737
6. Alberts MJ. **Results of a randomized multicenter trial of carotid stenting vs. carotid endarterectomy in symptomatic patients**. Presented at: 26th International Stroke Conference, Fort Lauderdale, FL, February 14–16, 2001
7. Yadav JS, Wholey MH, Kuntz RE, et al. **Protected carotid artery stenting versus endarterectomy in high-risk patients**. *N Engl J Med* 2004;351:1493–1501
8. **ACCULINK carotid stent system and RX ACCULINK carotid stent system. P040012: summary of safety and effectiveness data**. <http://www.fda.gov/cdrh/pdf4/P040012b.pdf>; August 30, 2004
9. Loftus CM, Biller J, Hart MN, et al. **Management of radiation-induced accelerated carotid atherosclerosis**. *Arch Neurol* 1987;44:711–714
10. Melliore D, Becquemin JP, Berrahal D, et al. **Management of radiation-induced occlusive disease: a reassessment**. *J Cardiovasc Surg* 1997;38:261–269
11. Warren S. **Effects of radiation on normal tissues**. *Arch Pathol* 1942;34:1070–1089
12. Smith C, Lowenthal L. **A study of elastic arteries in irradiated mice of different ages**. *Proc Soc Exp Biol Med* 1950;75:859–861
13. Sams A. **Histologic changes in the larger blood vessels of the hind limb of the mouse after x-irradiation**. *Int J Med Biol* 1965;9:165–174
14. Lindsay S, Kohn HI, Dakin RL, Jew J. **Aortic arteriosclerosis in the dog after localized aortic x-irradiation**. *Circ Res* 1962;10:51–59
15. Lam WW, Leung SF, So NM, et al. **Incidence of carotid stenosis in nasopharyngeal carcinoma patients after radiotherapy**. *Cancer* 2001;92:2357–2363
16. Cheng SW, Ting AC, Lam LK, Wei WI. **Carotid stenosis after radiotherapy for nasopharyngeal carcinoma**. *Arch Otolaryngol* 2000;126:517–521

17. Cheng SW, Wu LL, Ting AC, et al. **Irradiation-induced extracranial carotid stenosis in patients with head and neck malignancies.** *Am J Surg* 1999;178:323–328
18. King LJ, Hasnain SN, Webb JA, et al. **Asymptomatic carotid arterial disease in young patients following neck radiation therapy for Hodgkin lymphoma.** *Radiology* 1999;213:167–172
19. Dubec JJ, Munk PL, Tsang V, et al. **Carotid artery stenosis in patients who have undergone radiation therapy for head and neck malignancy.** *Br J Radiol* 1998;71:872–875
20. Steele SR, Martin MJ, Mullenix PS, et al. **Focused high-risk population screening for carotid arterial stenosis after radiation therapy for head and neck cancer.** *Am J Surg* 2004;187:594–598
21. Elerding S, Fernandez R, Grotta J, et al. **Carotid artery disease following external cervical irradiation.** *Ann Surg* 1981;5:609–615
22. Stallones DA, Dylan ML, Fang HCH, et al. **Epidemiology for stroke facilities planning.** *Stroke* 1972;3:360–369
23. Executive Committee for the Asymptomatic Carotid Atherosclerosis Study. **Endarterectomy for asymptomatic carotid artery stenosis.** *JAMA* 1995;273:1421–1428
24. Kashyap V, Moore W, Quinones-Baldrich W. **Carotid artery repair for radiation-associated atherosclerosis is a safe and durable procedure.** *J Vasc Surg* 1999;29:90–99
25. AbuRahma AF, Jennings TG, Wulu JT, et al. **Redo carotid endarterectomy versus primary carotid endarterectomy.** *Stroke* 2001;32:2787–2792
26. Al-Mubarak N, Roubin GS, Iyer SS, et al. **Carotid stenting for severe radiation-induced extracranial carotid artery occlusive disease.** *J Endovasc Ther* 2000;7:36–40
27. Houdart E, Mounayer C, Chapot R, et al. **Carotid stenting for radiation-induced stenoses: a report of 7 cases.** *Stroke* 2001;32:118–121
28. Ting AC, Cheng SW, Yeung KM, et al. **Carotid stenting for radiation-induced extracranial carotid artery occlusive disease: efficacy and midterm outcomes.** *J Endovasc Ther* 2004;11:53–59