



Get Clarity On Generics

Cost-Effective CT & MRI Contrast Agents



FRESENIUS
KABI

WATCH VIDEO

AJNR

Atlas of Spine Imaging

AJNR Am J Neuroradiol 2005, 26 (7) 1879-1880

<http://www.ajnr.org/content/26/7/1879>

This information is current as
of August 14, 2025.

Atlas of Spine Imaging

Donald L. Renfrew. Philadelphia: Saunders; 2003. 376 pages, 000 illustrations. \$135.

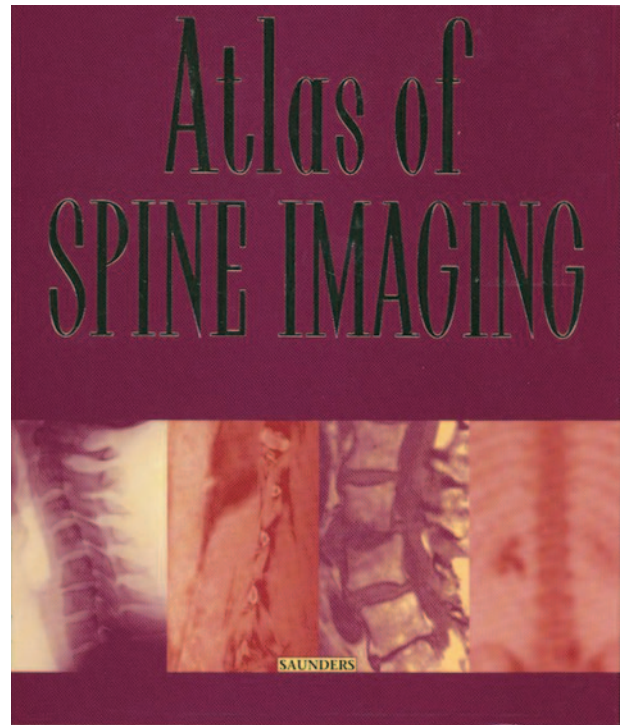
In the preface of the *Atlas of Spine Imaging*, Donald Renfrew indicates that he wrote this text because the existing texts on spine imaging lacked the appropriate focus; specifically, there has been little emphasis on the treatment of spinal conditions, lack of copious images obtained with current technology, concise description of disease processes, and pragmatic approaches to interpretation. The book is written with these shortfalls in mind. The author appears to have done an adequate job in this regard.

Although some of the criticisms of previous texts are accurate, the uniqueness and strength of this text is that many of the chapters categorize patients into particular "clinical scenarios" with the provision of algorithms that include differential diagnoses and next steps, including imaging and/or clinical results, that guide patient work-up. An additional unique aspect of the book is the inclusion of forms that are helpful in the reporting of degenerative spine disease and sample clinical cases with reports emphasizing the need for an understanding of neural physiology and anatomy as well as pain diagrams that allow for the generation of more meaningful reports. The inclusion of specific examples of radiology reports can be of particular use for those inexperienced in reporting spine images, but they have less value for more-experienced radiologists.

The book is divided into nine chapters: "Anatomy," "Degenerative Disease," "Imaging of the Postoperative Spine," "Imaging of Spine Tumors," "Imaging of Trauma," "Infectious Spondylitis," "Congenital and Developmental Anomalies," "Spondylolysis," and "Miscellaneous Diseases of the Spine." There are no subheadings at the beginning of each chapter, an addition that would have enabled more rapid identification of particular entities.

Although this book contains more images than found in most texts on the subject, the title is a bit misleading. Most spine atlas texts are configured as unknown casebooks with a brief description of the pathologic entity along with a differential diagnosis. This book is somewhere between an atlas and a complete authoritative text on spine imaging, although it falls significantly short of the latter.

The strength of an atlas should be in the images and captions. In general, the quality of the images is mediocre. There are many images that have a "washed-out" appearance. The emphasis is heavily weighted toward MR, representative of current clinical practice. There are, however, few CT scans, conventional radiographs, myelograms, bone scans, or positron-emission tomographic scans, all of which are important tools in the evaluation of many conditions. There is a particular deficiency of high-quality, state-of-the-art CT scans and plain films, which are com-



monly utilized in the daily evaluation of patients with spinal problems.

One of the major drawbacks of the book is the use of excessive narrative in the legends. Rather than pointing out the major findings and purpose of the case, there is an excessive amount of extraneous information. At times, rather than enabling the reader to determine quickly what the arrows in a figure are pointing out, the process became onerous.

In the anatomy chapter, the spinal anatomy is displayed with T2-weighted MR images. There is no use of conventional radiographs or CT scans in the demonstration of any anatomy, even though the emphasis in the prose is on the bony vertebral anatomy. There is no mention of the normal canal dimensions. The vascular anatomy is generally ignored.

The degenerative disease chapter extensively uses pain diagrams, but there is no accompanying use of motor or sensory diagrams. Emphasis is on the lumbar spine. Nomenclature adopted by the North American Spine Society and American Society of Neuroradiology is utilized in the depiction of disk herniations. Table 2-3 gives an incorrect description for an extrusion, although it is correct in the text. The tables detailing the grading schemes for canal stenosis, subarticular recess stenosis, are particularly helpful. There are several statements made that I do not agree with and are not based on hard, scientifically

verified facts. For example, it is recommended that the axial images should be obtained only through the disk spaces. There is no discussion or demonstration of the radiographic definition of instability.

In chapter 3, "Imaging of the Postoperative Spine," there is nice utilization of postoperative scenarios with demonstration of potential causes of postoperative symptoms in different settings. In many of the images, there is no indication of how long after surgery the images were acquired. This is crucial information that is necessary when interpreting postoperative images. For example, Fig 3-14 is labeled as showing residual disk herniation following discectomy; however, there is no indication of how long after surgery the images were acquired, and the patient's preoperative symptoms had resolved. On the basis of the imaging findings, the defect pointed out could represent a postoperative seroma or edema rather than residual disk. In Fig 3-19, the authors present the case as foraminal stenosis causing persistent radicular pain following laminectomy and discectomy, yet they neither mention the fact that the incorrect operation was performed nor point out that the patient has foraminal stenosis related to a spondylolysis with spondylolisthesis.

In the spine tumor chapter, it is unclear why dermoid and lipoma are included in the algorithm of an enhancing intramedullary lesion. Figure 4-35 demonstrates a patient with myelofibrosis in whom the authors indicate that there is T1 shortening of the mar-

row, but actually there is T1 lengthening. T2-weighted fast spin-echo (FSE) images are used to characterize bony pathology. This is a critical error in that bony lesions cannot be characterized on T2-weighted FSE images without the use of some type of fat suppression such as short-inversion-time inversion recovery or chemical fat suppression. Without use of these techniques, mischaracterization of the true nature of the lesion can occur.

The chapter on spine trauma does not deal with the important but difficult concept of instability. I find it odd that an entire chapter is dedicated to spondylolysis. The author, however, does an excellent job in the chapter. The chapter on infectious spondylitis is particularly well done, with excellent images, tables, and algorithms.

Finally, the references provided are limited and, in many instances, outdated.

In summary, this book will be most useful to any radiologists who routinely interpret spine images and particularly those who have not had the benefit of fellowship training. The author provides a unique approach to teaching spinal pathology with the strengths of the book the chapters on degenerative disease, the postoperative spine, infectious spondylitis, and spondylolysis, as well as its use of clinical scenarios, diagnostic algorithms, and example reports. There are some limitations related to image quality, verbose captions, inaccuracies, and incomplete references.