



Discover Generics

Cost-Effective CT & MRI Contrast Agents



FRESENIUS
KABI

WATCH VIDEO

AJNR

CT Evaluation of Lumbar Interbody Fusion: Current Concepts

Alan L. Williams, Matthew F. Gornet and J. Kenneth Burkus

AJNR Am J Neuroradiol 2005, 26 (8) 2057-2066

<http://www.ajnr.org/content/26/8/2057>

This information is current as
of June 21, 2025.

CT Evaluation of Lumbar Interbody Fusion: Current Concepts

Alan L. Williams, Matthew F. Gornet, and J. Kenneth Burkus

Operative techniques for fusing an unstable portion of the lumbar spine or immobilizing a painful vertebral motion segment have been in use for many years. Lumbar fusion procedures initially were used to treat patients with infections (tuberculous spondylitis) or misaligned spines (isthmic spondylolisthesis) (1–8). Early techniques involving the use of harvested autogenous bone graft without instrumentation were largely unsuccessful because of the lack of structural integrity and the undesirable side effects of the harvesting procedure. Because of the high failure rates associated with early fusion procedures using bone graft or posterior pedicle screws, an eventual transition to more successful approaches to disk height maintenance using a structural graft took place. The evolution of construct design from femoral ring allograft, to threaded cortical bone dowels, to cylindrical metal fusion cages, and ultimately to tapered fusion cages (metal and composite) proceeded with the knowledge that fusion success requires, in part, both mechanical stability and adequate graft material to provide a favorable biologic environment in which fusion can occur (9).

Increasingly, lumbar interbody fusions have been performed in patients with degenerative disk disease and discogenic pain syndromes (10–11). It is estimated that more than 300,000 lumbar spine fusion procedures are performed each year in the United States (12). The radiologist should be familiar with the various techniques, devices, and potential complications associated with these procedures.

Since the first posterior lumbar interbody fusion performed by Cloward in 1940, spinal interbody fusion techniques have continued to evolve with an increasing number of interbody fusion devices available for use (9, 11–18). These devices have varying geometric configurations and wall thicknesses and are made of various materials, such as titanium, PEEK (polyether etherketone), and other polymers. In addition, human allograft bone dowels and allograft

bone spacers are also used in interbody fusion procedures. The choice of a particular interbody fusion device affects the ability of surgeons and radiologists to assess fusion progression on dynamic radiographs and CT scans.

Interbody Fusion Techniques

Interbody fusion, or fusion across the disk space, can be performed by using several surgical approaches. Posterior lumbar interbody fusion, anterior lumbar interbody fusion, and transforaminal lumbar interbody fusion have unique advantages and potential complications associated with each approach. Each technique can stand alone or can be accompanied by supplemental segmental posterior instrumentation (posterior rods and pedicle screws most commonly). The purpose of all interbody fusion devices is to restore and maintain disk space height and normal sagittal contours (lordosis) and to increase the stability of the operated segment or segments (13). Stability and lordosis are obtained by stretching the annulus and supporting ligaments via distraction of the disk space. This stretching of the motion segment is termed “ligamentotaxis” and provides a biomechanically stable construct that will limit motion and permit fusion to develop. Distraction of the disk space also results in indirect decompression of the foramina (13).

The approach to the disk space is based on the surgeon's experience and familiarity with anatomy. Posterior lumbar interbody fusion is used most often when decompression of a nerve root is required. Transforaminal lumbar interbody fusion is a modified posterior approach that permits foraminal decompression and a wider, safer access to the disk space for a surgeon with a preference for the posterior approach. Anterior lumbar interbody fusion is the optimal approach for accessing the disk space and performing interbody fusion but requires a skilled access surgeon and may necessitate a supplemental posterior approach to provide nerve root access and structural support. For each approach, an annular window is created and a total discectomy performed to achieve clean bleeding endplates. This clean bone surface provides an optimal environment for fusion to occur.

A posterior lumbar interbody fusion typically requires resection of a major portion of the posterior lumbar laminae and, frequently, near-total facetectomies for levels above L5–S1 (1, 8). To obtain access to the disk space, the surgeon must retract the thecal sac

Received February 18, 2005; accepted after revision February 24, 2005.

From the Mallinckrodt Institute of Radiology, Washington University School of Medicine (A.L.W.), and the Orthopaedic Center of St. Louis (M.F.G.), St. Louis, MO; and the Wilderness Spine Services (J.K.B.), Hughston Clinic, Columbus, GA.

Address correspondence and reprint requests to Alan L. Williams, Section of Neuroradiology, Mallinckrodt Institute of Radiology, 510 South Kingshighway, St. Louis, MO 63110 (e-mail: willistlou@aol.com).

and nerve roots medially. Through this approach, it is often difficult to place sufficiently large devices to gain stability and provide ligamentotaxis without injuring the nerve roots. Because of the increased risk of nerve root complications and relatively poor results with stand-alone posterior lumbar interbody fusion constructs, most posterior lumbar interbody fusion operations today use supplemental posterior instrumentation. Posterior instrumentation allows smaller stabilization devices to be placed within the disk space, which has the secondary effect of limiting nerve root injuries. Many of the posterior lumbar interbody fusion procedures are accompanied by posterolateral intertransverse process fusion.

Another common approach for lumbar interbody fusion is transforaminal lumbar interbody fusion. This approach allows wider access to the disk space than a posterior lumbar interbody fusion and accommodates placement of intradiskal grafts with less nerve root retraction (19, 20). This approach removes the pars interarticularis and facet joint unilaterally. The disk space is approached from the posterolateral direction in the zone between the transversing nerve root and the superior exiting nerve root. This approach, however, does not allow placement of sufficiently large devices for a stand-alone fusion and must be supplemented with posterior instrumentation (19–21).

The advantage of the anterior approach (anterior lumbar interbody fusion) to the disk space is that it permits placement of optimal-sized devices to provide stability and ultimately to facilitate fusion (11, 14). It is the only approach that does not require supplemental posterior instrumentation. This approach avoids injury to posterior paravertebral muscles, an important factor when treating low back pain, while retaining all posterior stabilizing structures and avoiding nerve root retraction and epidural scarring. The disadvantage of the approach is that it requires the presence of a skilled access surgeon familiar with the anatomy of the anterior lumbar spine. Potential complications associated with anterior lumbar interbody fusion include vascular injuries such as laceration of the iliac vein and retrograde ejaculation (3, 4, 14).

Anterior lumbar interbody fusion is frequently performed as a stand-alone procedure. The use of supplemental posterior instrumentation with anterior lumbar interbody fusion requires 2 separate surgical approaches. A number of spine surgeons opt for stand-alone anterior lumbar interbody fusion and reserve posterior instrumentation for patients in whom arthrodesis is subsequently delayed. In many patients with delayed interbody fusion via the anterior approach, the application of posterior rods and pedicle screws will promote rapid progression to solid arthrodesis. Currently, supplemental posterior instrumentation with anterior lumbar interbody fusion is being introduced through minimally invasive techniques that reduce the soft-tissue trauma associated with placement of pedicle screws via open techniques. Most pedicle screw systems currently use titanium implants; degradation of anatomic detail on postop-

erative MR imaging is not as severe as in the past, when stainless steel implants were used.

The time from implantation of an interbody fusion device to solid arthrodesis is variable, but it is usually a minimum of 6–12 months (22).

Common Lumbar Interbody Fusion Devices

First-generation devices were cylindrical and could be placed via a posterior lumbar interbody fusion or an anterior lumbar interbody fusion approach. Subsequent second-generation devices offered improved shapes and sizes to optimize fit within the disk space and improve alignment and fusion.

Metal Devices

BAK (Bagby and Kuslich) Cage. Originally developed to treat race horses with wobbler syndrome (cervical spinal stenosis), the BAK cage (Zimmer Spine, Warsaw, IN) is a cylindrical, hollow, porous, square-threaded, titanium alloy cage that is screwed into position within the disk space (Fig 1A) (8, 16–17). It can be implanted through anterior lumbar interbody fusion or a posterior lumbar interbody fusion approach. Advantages include the absence of supply difficulties related to donor size or accessibility, improved shelf life, and the lack of disease transmission issues. This first-generation cage is still used. It is thicker than subsequent generations of cages and produces more severe artifacts on MR and CT imaging. The BAK cage has less area for bone growth relative to newer generation devices.

Ray Threaded Fusion Cage. A second-generation cage developed by Charles Ray, the Ray Threaded Fusion Cage (Stryker Spine, Allendale, NJ) is a cylindrical, hollow, titanium, threaded device that contains less metal than the BAK cage (Fig 1B) (18). Although it offers advantages similar to those of the BAK cage, the Ray cage produces fewer artifacts on imaging studies. The Ray cage can be implanted through posterior lumbar interbody fusion or an anterior lumbar interbody fusion approach.

LT-CAGE Lumbar Tapered Fusion Device. The LT-CAGE (Medtronic Sofamor Danek, Memphis, TN), a third-generation device, is currently the most widely used interbody implant in North America. Because of its trapezoidal configuration (tall anterior/short posterior), it is placed only through the anterior approach. The shape also allows increased surface area for bone growth (Fig 1C). The tapered configuration facilitates restoration of lordosis (14). It is a thin-walled, threaded cage with truncated side walls that facilitate radiographic assessment of new bone formation inside and outside the implant. Advantages versus allograft include the absence of supply difficulties related to donor size or accessibility, improved shelf life, and the lack of disease transmission concerns.

INTER FIX Threaded Fusion Device and the INTER FIX RP Threaded Fusion Device. The INTER FIX and the INTER FIX RP (Medtronic Sofamor Danek) are second-generation cylindrical, fenestrated, titanium cages that permit improved CT imaging because of




FIG 1. A, BAK cage (Zimmer Spine). B, Ray Threaded Fusion Cage (Stryker Spine). C, LT-CAGE. D, INTER FIX device (panels C and D; Medtronic Sofamor Danek). E, Harms cage (DePuy Spine). F, PEEK cage (Medtronic Sofamor Danek). G, JAGUAR I/F CAGE (Brantigan Device; DePuy Spine). H, BOOMERANG. I, Bone Dowel. J, Femoral Ring (panels H-J courtesy of Medtronic Sofamor Danek).

the decreased wall thickness (Fig 1D). These devices can be implanted through anterior lumbar interbody fusion or posterior lumbar interbody fusion approaches. Advantages versus allograft are similar to the aforementioned devices.

Harms Cage. Harms cage (DePuy Spine, Raynham, MA), a surgical titanium mesh cage, has an open diamond configuration to maximize the area of bone graft and allow for load sharing. The device has a 1-mm wall thickness to provide axial strength. It is placed through either an anterior or posterior approach. Advantages versus allograft are similar to the aforementioned devices.

Composite Devices

PEEK Cage. PEEK refers to polyetheretherketone, a plastic substance with biomechanical properties similar to those of cortical bone. This compound can

be machined into any shape and size and is radiolucent on CT and plain radiographs. Depending on the shape, it can be placed through any approach. Fusion results with a PEEK device are currently under investigation. It is reasonably well visualized on MR images, because the PEEK cage (Medtronic Sofamor Danek) is essentially free of water. Because it is radiolucent, small metallic markers are usually placed at the anterior and posterior ends of the device to allow monitoring of position (Fig 1F).

JAGUAR I/F CAGE (Brantigan Device). The JAGUAR I/F CAGE (DePuy Spine) is a carbon fiber-reinforced polymer implant, which can be machined to meet size and shape requirements. It is predominately radiolucent and produces fewer artifacts on CT and MR images (Fig 1G). As with the PEEK device, markers are placed to allow visualization on plain radiographs. The JAGUAR I/F CAGE is typically a rectangular-type cage that is driven into a disk space. This device was

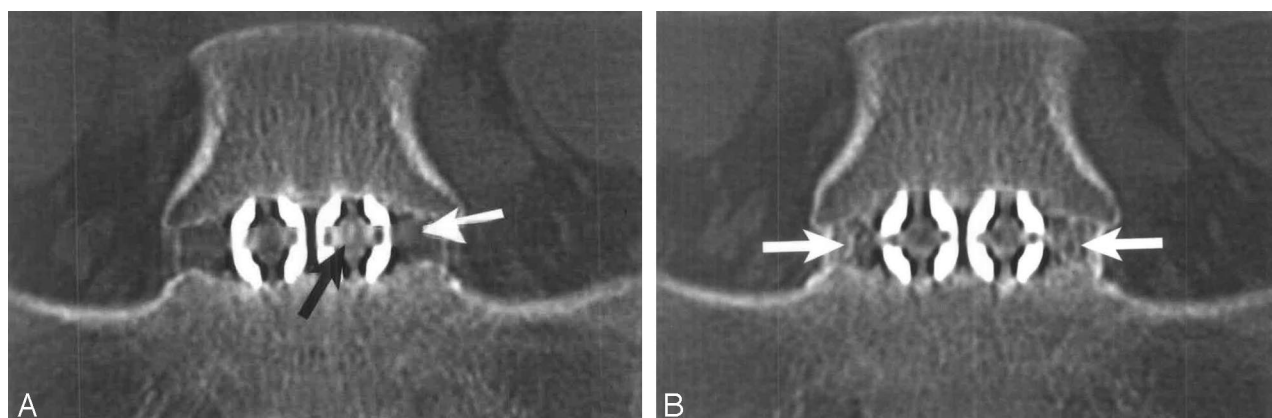


FIG 2. Normal progression of interbody fusion in a 28-year-old woman. A, On a coronal reformatted CT image, obtained 6 months after surgery, new bone formation is evident within (black arrow) and adjacent to (white arrow) the LT-CAGE devices. B, Ten months after surgery, reformatted CT image shows additional new bone formation, especially lateral to the fusion devices (white arrows), with bony bridging across the disk space.

designed for the posterior lumbar interbody fusion approach and is always used with supplemental posterior instrumentation (9). The disadvantage of a rectangular cage placed through a posterior approach is the tendency toward segmental kyphosis.

BOOMERANG II Device. The BOOMERANG II (Medtronic Sofamor Danek) second-generation device is a bow-shaped implant with biconvex surfaces that provide a large opening for graft placement. The device is implanted most often through a transforaminal lumbar interbody fusion approach. Other advantages of the BOOMERANG II include its radiolucency, lack of artifacts on CT imaging, and transverse positioning within the disk space, producing increased biomechanical stability. Markers are placed to allow visualization on plain radiographs (Fig 1H).

Biologic Devices

Bone Dowels/Femoral Rings. MDII Threaded Cortical Bone Dowels (Medtronic Sofamor Danek) are threaded pieces of femoral allograft that are screwed into position within the disk space (Fig 1I). Precision Graft femoral rings (Medtronic Sofamor Danek) are cut pieces of allograft femur that are impacted into the disk space (Fig 1J). These devices can be placed through anterior lumbar interbody fusion, posterior lumbar interbody fusion, or a transforaminal lumbar interbody fusion approach. Advantages of bony devices are the absence of imaging artifacts and the placement of a completely biologic device. With the anterior lumbar interbody fusion approach, stand-alone femoral rings are less stable than threaded Bone Dowels, with stand-alone fusion rates of only 60%. Disadvantages of allograft materials include the risk of disease transmission and the potential for fracture when inserted with an impactor (15).

Bone Graft Substitutes

Recombinant Human Bone Morphogenetic Protein (rhBMP-2), Commercially Available as INFUSE Bone

Graft. INFUSE Bone Graft substance (Medtronic Sofamor Danek) has been the most significant development in interbody fusion in recent years (22–27). Approved in July 2002 as the first bone graft substitute equivalent to iliac crest autograft for spinal fusion, INFUSE Bone Graft combines rhBMP-2 with an absorbable collagen sponge carrier. The rhBMP-2 acts as a signaling molecule to attract mesenchymal stem cells, binding to cell receptors and causing these stem cells to differentiate into osteoblasts and initiate bone formation. Recently, INFUSE has been shown to be superior to autologous iliac crest bone graft in obtaining interbody fusion (22). INFUSE can be used with any interbody fusion device as a bone graft replacement in the interbody space; however, it is currently approved by the Food and Drug Administration for use only with the LT-CAGE. INFUSE Bone Graft is radiolucent at the time of placement. Increased attenuation within the disk space reflects new bone formation (Fig 2) (25–26).

Radiographic Evaluation Of Interbody Fusion

Plain Radiographs

For many years, dynamic lateral flexion and extension radiographs have been used to monitor the progression of an interbody arthrodesis (28). These films have significant intra- and interobserver variation. Measurement accuracy is also largely dependent on obtaining true lateral views; suboptimal radiographs are often obtained (29). Interpretation of plain radiographs is further complicated by the difficulty in judging fusion progression. In a study using sheep, Sandhu et al (24) found that although all sheep treated with interbody cages for fusion showed evidence of fusion at 6 months on plain radiographs, only 33% were subsequently judged fused on histologic examination. Because of the metallic artifact associated with fixation devices, it is often difficult to evaluate spinal fusion. In addition, because posterior fusions are often performed in conjunction with laminectomy, movement of the

Suggested CT scanning protocol*

Patient orientation	Supine, feet first
Gantry tilt	0°
Region of interest	Initial exam: mid-T12 to mid-sacrum Subsequent exams: One level above to one level below fusion level(s)
Kernel/algorithm	B80/bone
Milliamperage (mA)	250
Kilovoltage (kV)	140
Field of view (FOV)	14 cm
Matrix	512 × 512
Volume acquisition	1.0 mm
slice collimation	
Image reconstruction	
progression	
Step 1	Reconstructed axial 3.0-mm-thick sections; entire scan volume
Step 2	Reconstructed axial 1.0-mm-thick sections at 0.5-mm increments (overlapped); region of interest only
Step 3	Reformatted images in 3 planes; region of interest; 1.0 mm axial (parallel to the disc); 3.0 mm coronal and sagittal
Window and level settings	2000–3000/350–400

* Multisession (4) CT scanner.

posterior elements cannot be studied. Calculating subtle degrees ($<5^\circ$) of motion on flexion/extension films is considered irreproducible, because of observer measurement error. Dynamic radiographs do not usually provide detailed appreciation of bony bridging across the disk space. For these reasons, many spine surgeons assessing fusion now use CT scanning as an adjunct to dynamic radiographs (30).

The choice of bone graft material may impact the radiographic assessment of interbody fusion. When iliac crest bone graft or another graft substitute material is used to fill the device, the graft is radiopaque, and graft remodeling or resorption or both must be evaluated to determine if fusion is progressing. When a graft such as INFUSE Bone Graft is used, the graft is radiolucent at placement and fusion assessment is based in part on an increase in radiodensity that correlates with de novo bone formation.

The use of interbody devices presents new challenges in the determination of fusion status. Metal devices obscure the central bone graft, making it difficult to see if the bone graft has matured or remodeled or if trabeculations have formed between the graft and host bone. This obscuration is particularly true of first-generation devices such as the BAK cage, which is thick-walled and square-threaded. Although polymer devices do not conceal the bone graft from the site, the interbody space itself remains difficult to view without properly oriented radiographs, and this difficulty may impede interpretation of fusion. For this reason, it is important to obtain true lateral and anteroposterior radiographs to achieve good visualization of the intervertebral space. When human allograft bone is used for interbody fusion, it is

again difficult to interpret fusion progression or allograft resorption/replacement or graft incorporation on plain films.

MR Imaging

MR imaging in its current application is considered inadequate for the assessment of interbody fusion. Artifacts from metallic fusion devices typically degrade anatomic detail. Bony changes such as edema or inflammation have little specificity in determining fibrous union versus early stages of arthrodesis. Thus, MR imaging is not acceptable for monitoring the progress of an arthrodesis.

CT

CT has developed into the preferred method of assessing interbody fusion (26, 28, 30–32). CT is rapid, offers the potential for high-quality reformatted images in the coronal and sagittal planes, and provides exquisite bone detail. Hardware artifacts can compromise CT; however, later-generation metallic fusion devices using titanium result in less pronounced degradation by artifact compared with earlier stainless steel implants.

The use of CT for monitoring the progression of interbody fusion is now common at many centers. Thin-section reconstructed CT scans, especially the reformatted coronal and sagittal images, have been demonstrated to show fusion maturation and bone growth and have been effective in fusion evaluation. The scatter effect from second-generation metal devices has not been found to be a significant obstacle when using thin-section CT. CT can often identify failure of device fixation and nonunion, but it is not as sensitive in identifying when true arthrodesis has occurred (32).

CT Protocol

CT protocols have been developed to monitor periodically the progress of interbody arthrodesis. This particular protocol (Table 1) was developed in conjunction with several spine surgeons who perform large numbers of interbody fusions annually. CT scans are normally obtained 3, 6, 12, and 24 months after a fusion procedure or until solid arthrodesis has been obtained. These scans may be obtained without plain radiographs. The following is a summary of the typical findings for each assessment period:

Three Months. At 3 months, early bone healing is occurring (Fig 2A). Obvious perihardware lucencies that would indicate loss of fixation are noted. Subsidence, or sinking of the implant into the vertebral body above or below, should also be noted. Subsidence has direct impact on ligamentotaxis and therefore reflects a partial loss of structural stability. CT scans play an important role in the progression of patient activity levels, in particular the decision regarding return to work.

Six Months. Bony arthrodesis may be nearing completion at 6 months with evidence of bridging trabecular bone. Bridging bone is usually seen lateral to the implant and may also be noted within the implant

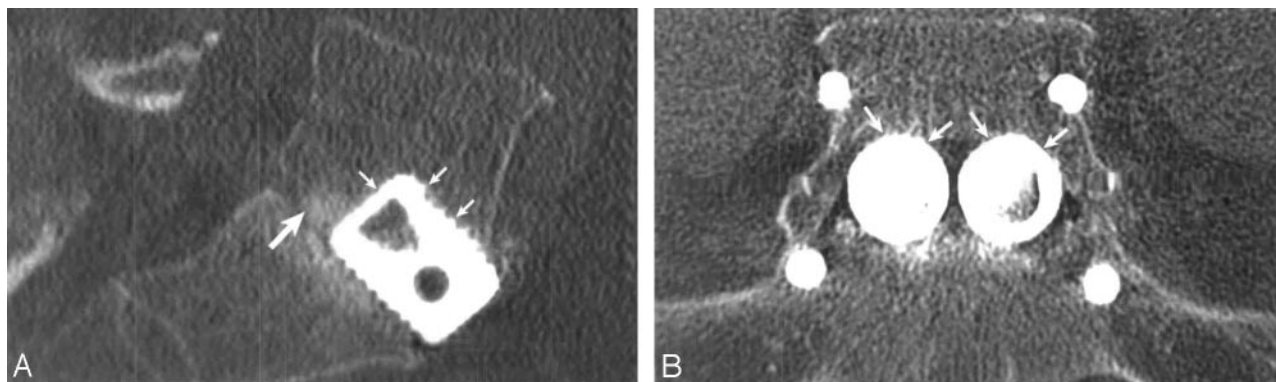


FIG 3. Subsidence of LT-CAGE devices at L5-S1. Sagittal (A) and coronal (B) reformatted CT images demonstrate subsidence of the LT fusion devices (*small arrows*) through the L5 inferior endplate into the vertebral body in a 60-year-old man. The sagittal image demonstrates new bone formation (*large arrow*) posterior to the fusion device with bony bridging taking place across the disk space.

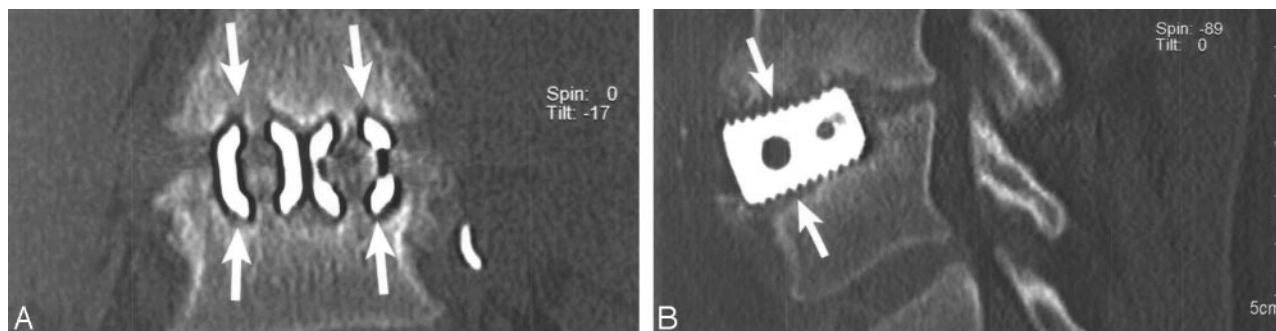


FIG 4. Lucency at fusion device margins. Coronal (A) and sagittal (B) reformatted images at L5-S1 in a 45-year-old man demonstrate lucency (*arrows*) at the margins of both LT CAGEs, suggesting delayed or failed fusion.

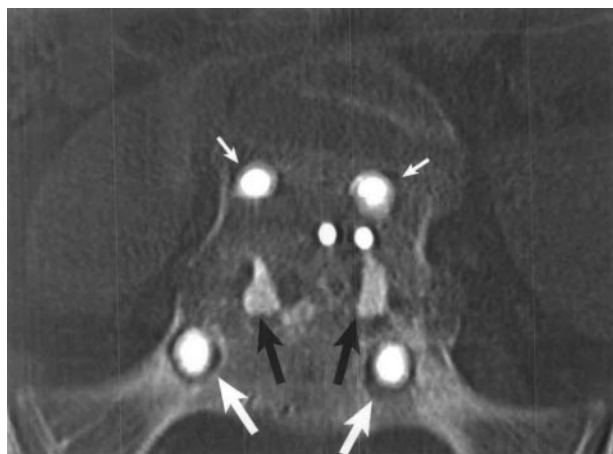


FIG 5. Lucency surrounding pedicle screws. Coronal reformatted image at L5-S1 in a 58-year-old woman demonstrates lucency (*large white arrows*) surrounding the pedicle screws at S1 and subtle lucency around the L5 screws (*small white arrows*), signifying instrumentation loosening and fusion failure. Note the fusion devices (*black arrows*) within the disk space.

itself (Fig 2B). Initial bone formation tends to occur between the lateral aspect of the fusion device and the annulus. There should be no cystic lucencies adjacent to the implant and no linear defects through the bridging bone. Presence of these findings is indicative of delayed union, with direct implications regarding return to work and the predictability of successful fusion.

Twelve Months. Findings at 12 months are similar to those with the 6-month CT scan. Trabecularization should be more mature with obvious bridging bone between vertebral bodies.

Twenty-four Months. CT is performed only if solid arthrodesis is not present at 12 months. The disk space has begun to consolidate more completely with filling of trabecular bone around the implants. Any evidence of lucency or cystic changes at the device margins or lucent lines through the fusion mass is an indicator of nonunion, or failed fusion.

CT Interpretation

The radiologist interpreting a CT scan on a patient who has undergone interbody fusion should evaluate the following points:

Scout Radiographs/Topograms. Reviewing anteroposterior and lateral scout radiographs enables the radiologist to appreciate the fusion level or levels involved, the approach (anterior, posterior, or both), the type of fusion device used, vertebral alignment, and the probable cause of the patient's problem necessitating the fusion (spondylolisthesis, discogenic pain, and so forth). The scout radiographs will alert the radiologist to any surgical procedure (eg, adding posterior rods and pedicle screws) that has occurred since the prior study.

Vertebral Body Alignment. Is anterolisthesis, retrolisthesis, or scoliosis visible?

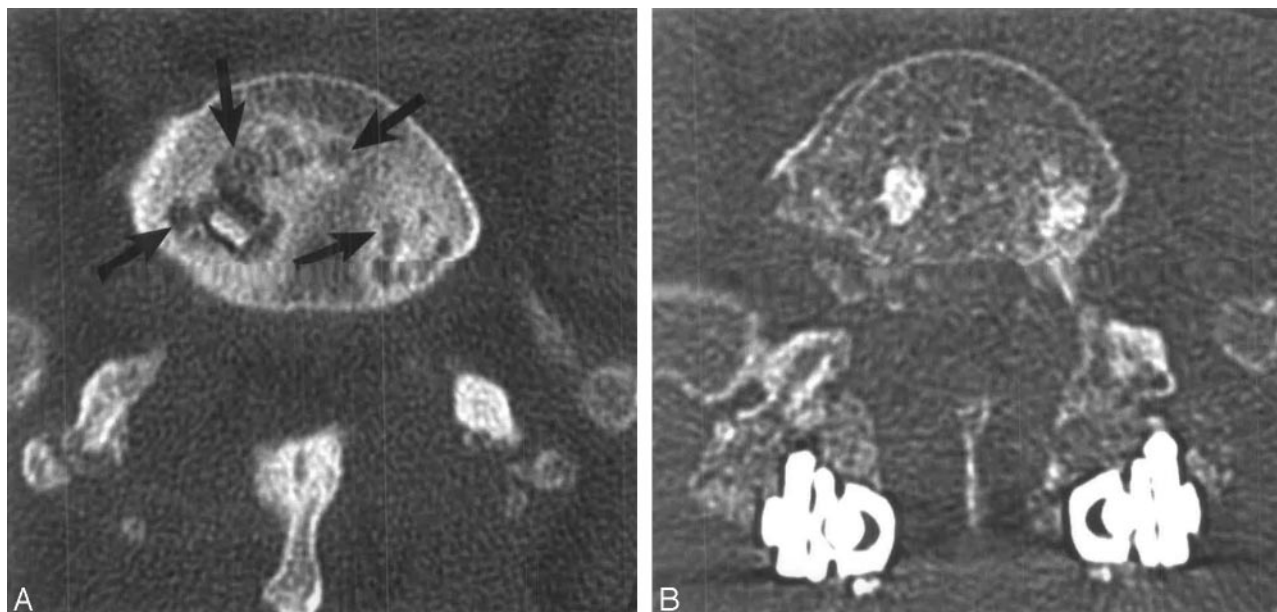


FIG 6. Cystic changes within the endplates adjacent to the implants. *A*, Five months after surgery in a 62-year-old woman, CT scan shows cystic changes (arrows) in the endplates at the L5-S1 level on an axial image. *B*, Twenty-one months after the application of posterior instrumentation, CT scan shows that the cystic changes are much less prominent as the fusion is progressing to solid bony union.

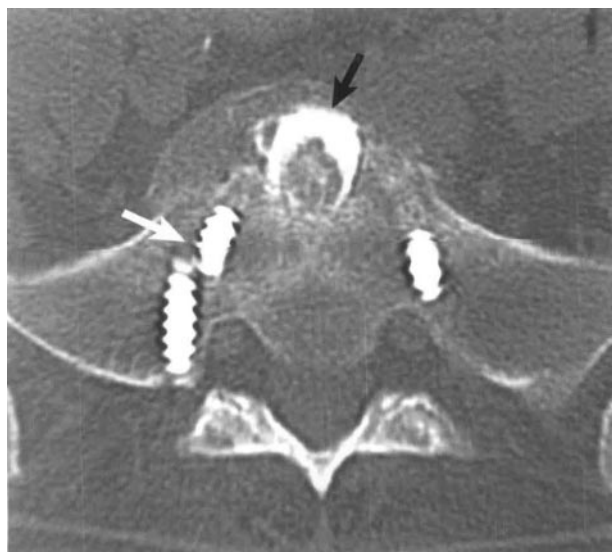

FIG 7. Broken pedicle screw. CT scan shows the fractured right S1 pedicle screw (white arrow). A Bone Dowel (black arrow) is present in the L5-S1 disk space.

Disk Space Preservation. Is significant disk disease visible at levels other than those fused? Has there been re-establishment of normal disk space height at the level or levels fused?

Anterior Versus Posterior Approach. Is the location of a fusion device or devices within the disk space anterior or posterior?

Number of Fusion Devices at Each Level Fused. Are the fusion devices single or paired?

Type of Fusion Device Used. Were Bone Dowel, femoral ring, metallic cage, carbon fiber device, and so forth used?

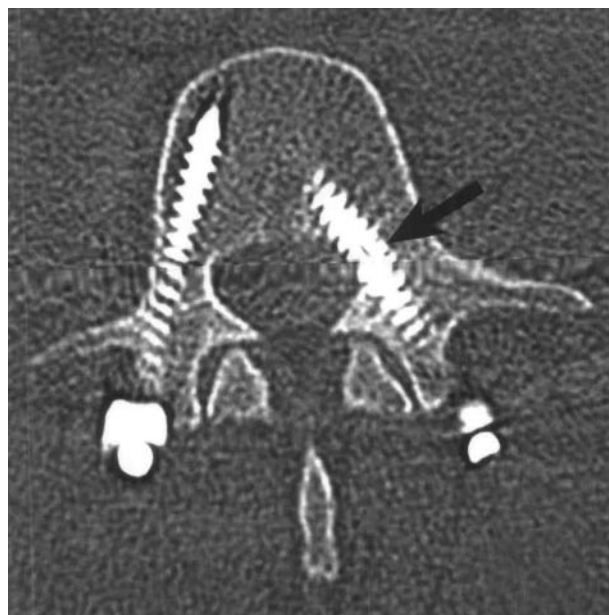


FIG 8. Medial orientation of pedicle screw. In a 48-year-old man, an axial image demonstrates that the left L4 pedicle screw (arrow) has penetrated the medial cortex of the pedicle in the vicinity of the L4 nerve root.

Change in Device Position. Is there any evidence of device movement since the previous CT scan?

Subsidence. Subsidence (defined as a fusion device sinking into one or both of the adjacent vertebral bodies) is significant because at the conclusion of a technically satisfactory interbody fusion procedure, a tight solid construct (ligamentotaxis) results. With subsidence, however, the ligaments are no longer tight. Subsidence is associated with an increased in-

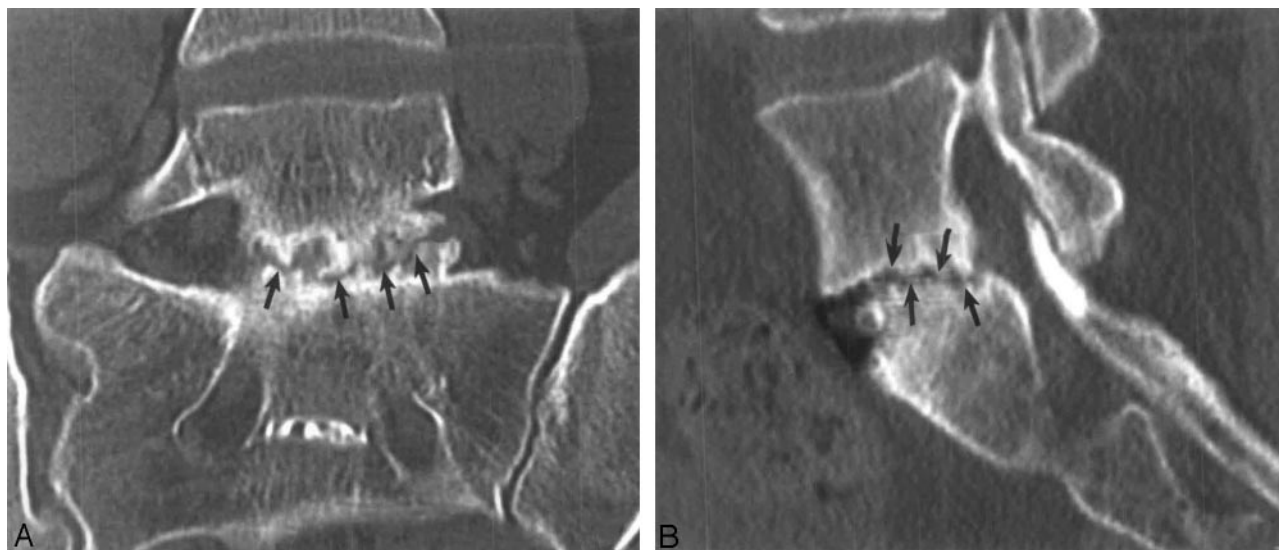


FIG 9. Linear lucency parallel to the endplate in new bone formation in a 31-year-old woman. Coronal (A) and sagittal (B) reformatted images at L5–S1 demonstrate irregular linear lucency (arrows) through new bone formation within the disk space, indicating failed fusion.

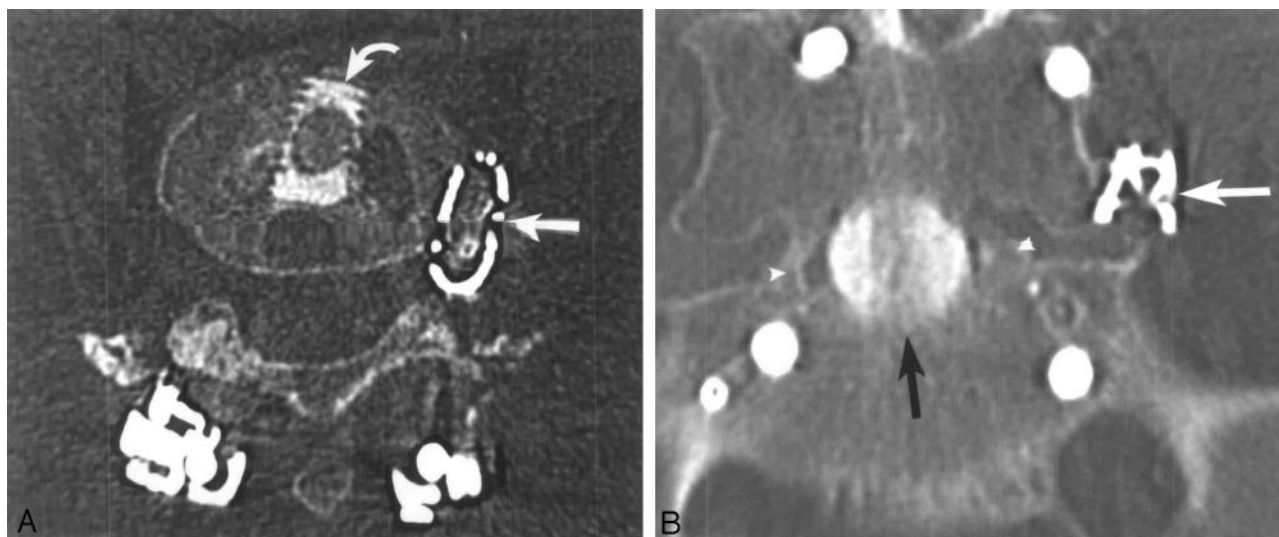


FIG 10. Dislodged fusion device. In a 51-year-old woman, axial (A) and coronal (B) reformatted images at L5–S1 demonstrate the left-sided mesh titanium fusion device (straight white arrow) displaced laterally within and lateral to the intervertebral foramen in the vicinity of the left L5 dorsal root ganglion and nerve. A Bone Dowel (curved white arrow) is noted in the midline in the disk space. Bony bridging (arrowheads) across the disk space is evident.

cidence of failed fusion because the loss of mechanical structural support allows the fusion device or bone graft material to shift or dislodge (Fig 3).

Lucency at the Fusion Device or Pedicle Screw Margins. Lucency suggests movement at the operated level and loosening of the device or screw. Such lucency is associated with delayed or failed fusion (Figs 4 and 5).

Cystic Changes Within the Endplates Adjacent to the Implant. Cystic changes are seen on axial views adjacent to the implants and are good markers for failed fusion (Fig 6). These changes will resolve if arthrodesis occurs.

New Bone Formation Within or Adjacent to the Fusion Devices. New bone, typically encouraged by the

inclusion of rhBMP-2-impregnated collagen sponge at the time of surgery, must develop to achieve solid bony bridging across the disk space in a successful fusion. New bone formation within or adjacent to the fusion device is typically seen by 3 months after the fusion procedure and usually progresses for 18–24 months (Fig 2). Often little change will be evident in a given 3-month period. New bone formation is best appreciated on the coronal and sagittal reformatted images.

Abnormalities at Levels Other Than the Fused Level or Levels. Our CT protocol initially covers T12 to the midsacrum. It is important for the radiologist to review carefully the images at levels rostral or caudal to the fused level to identify a herniated disk; central,

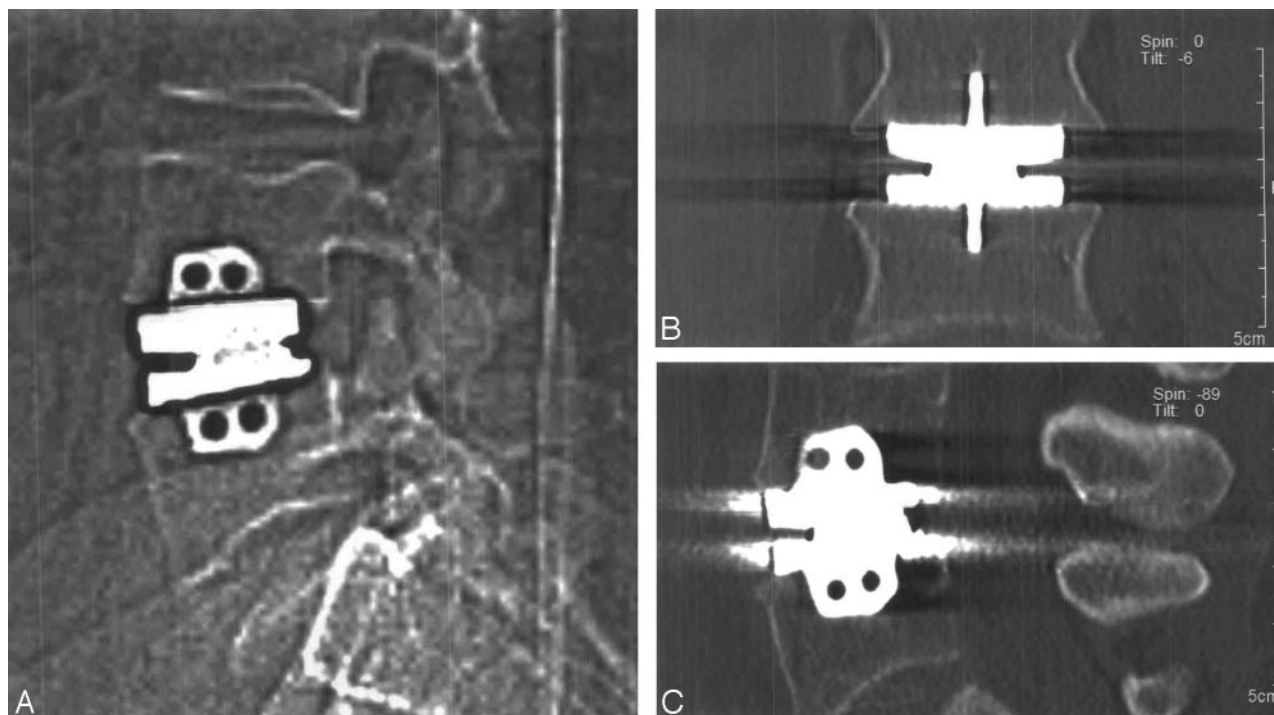


FIG 11. Intervertebral disk prosthesis. Lateral scout view (A) demonstrates a Maverick-type chrome cobalt disk prosthesis (Medtronic Sofamor Danek) within the L4–5 intervertebral disk space in a 33-year-old woman. Coronal (B) and sagittal (C) reformatted images demonstrate artifact related to the device, degrading anatomic detail at this level.

lateral recess, or foraminal stenosis; or facet arthropathy as potential causes for a patient's residual or recurrent symptoms after a fusion.

Location and Integrity of the Surgical Hardware. A fractured posterior rod or pedicle screw may be more easily appreciated on scout radiographs than on axial CT images (Fig 7); however, a medially directed pedicle screw that has penetrated the medial cortex of a pedicle in the vicinity of the adjacent nerve root is better delineated on axial images (Fig 8).

CT Features of Delayed or Failed Fusion

Lucency at the fusion device (or pedicle screw) margins. This lucency represents osteolysis secondary to device (screw) motion, which develops with bone resorption secondary to device motion (Figs 4 and 5). Another CT feature is cystic changes within the endplates adjacent to the implant (Fig 6). Linear defects (fracture) can be seen through intradiskal new bone within or adjacent to the fusion device parallel to the endplates (Fig 9). Relative indicators of loss of fixation that may lead to failure include a change in fusion device position (Fig 10) and device subsidence (Fig 3).

Future Advances

Radiolucent Fusion Devices. Radiolucent devices, such as those made of carbon fiber material, have a significant advantage over metallic devices in that they produce relatively little artifact on postoperative CT and MR imaging studies. Thus, monitoring the

fusion and appreciating any postoperative complication become easier for the radiologist.

Disk Prosthesis (Artificial Disk). Future treatment for low back pain will include use of a disk prosthesis (12, 33–34). Ideally, it will allow stabilization of the disk space but will maintain motion. The disk space height will be preserved with restoration of lordosis while permitting relatively normal mobility of the vertebral segments. The drawback of all disk prostheses currently under investigation is that their composition is predominantly chrome cobalt, which produces artifacts on CT and MR images (Fig 11).

Conclusion

Interbody fusion has become a reliable and frequent procedure and is the treatment of choice for a number of lumbar spinal disorders, including discogenic pain. CT provides better evaluation of fusion progression and status than dynamic radiography and is becoming the preferred method of monitoring patients who have undergone interbody fusion. The development of artificial disk replacement may reduce the need for interbody fusion in the future. In October 2004, the Charite became the first artificial disk to receive FDA approval (34); however, even as artificial disk replacement becomes more available, interbody fusion will remain an important procedure and the radiologist should be familiar with the common interbody fusion devices, the potential complications associated with each device and approach, the advantages of using CT to assess spinal fusion, and the important radiographic findings associated with fusion failure.

Acknowledgments

We would like to acknowledge the significant contributions to the preparation of this manuscript made by Yolanda Cillo, Francine Schranck, and Yelena Ruvenska. We also wish to thank the companies that allowed us to use the images presented in Fig 1: Zimmer Spine, Stryker Spine, Medtronic Sofamor Danek, and DePuy Spine.

References

- Cloward RB. The treatment of ruptured lumbar intervertebral discs vertebral body fusion. I. Indications, operative technique, after care. *J Neurosurg* 1953;10:154–168
- Lane JD, Moore ES. Transperitoneal approach to the intervertebral disc in the lumbar area. *Ann Surg* 1948;127:537–551
- Sacks S. Anterior interbody fusion of the lumbar spine. *J Bone Joint Surg Br* 1965;47:211–223
- Flynn JC, Hoque MA. Anterior fusion of the lumbar spine. *J Bone Joint Surg Am* 1979;61:1143–1150
- Harmon PH. Anterior excision and vertebral body fusion operation for intervertebral disk syndromes of the lower lumbar spine. *Clin Orth Rel Res* 1963;26:107–127
- Lipson SJ. Spinal-fusion surgery: advances and concerns. *N Engl J Med* 2004;350:7:643–644
- Crock HV. Anterior lumbar interbody fusion. *Clin Orthop* 1983;165:157–163
- Lin PM, Cantill RA, Joyce MF. Posterior lumbar interbody fusion. *Clin Orth Rel Res* 1983;180:154–168
- McAfee PC. Current concepts review: interbody fusion cages in reconstructive operations on the spine. *J Bone Joint Surg Am* 1999;81:859–880
- Deyo RA, Nachemson A, Mirza SK. Spinal-fusion surgery: the case for restraint. *N Engl J Med* 2004;350:7:722–726
- Kuslich SD, Ulstrom CL, Griffith SL, et al. The Bagby and Kuslich method of lumbar interbody fusion: history, techniques, and 2-year follow-up results of a United States prospective, multicenter trial. *Spine* 1998;23:1267–1279
- Becker C. Spine-tingling prospects: artificial disc implants are among the new technologies expected to revolutionize the outcomes of back surgery. *Mod Healthc* 2003;33:30–32
- Burkus JK. Intervertebral fixation: clinical results with anterior cages. *Orthop Clin N Am* 2002;33:349–357
- Burkus JK, Gornet MF, Dickman CA, Zdeblick TA. Anterior lumbar interbody fusion using rhBMP-2 with tapered interbody cages. *J Spinal Disord Tech* 2002;15:337–349
- Kleinstueck FS, Hu SS, Bradford DS. Use of allograft femoral rings for spinal deformity in adults. *Clin Orthop Rel Res* 2002;394:84–91
- Kuslich SD, Davidson G, Dowdle JD, et al. Four-year follow-up results of lumbar spine arthrodesis using Bagby and Kuslich lumbar fusion cage. *Spine* 2000;25:2656–2663
- Hacker RJ. Comparison of interbody fusion approaches for disabling low back pain. *Spine* 1997;22:660–666
- Ray CD. Threaded fusion cages for lumbar interbody fusion. *Spine* 1997;22:681–685
- Moskowitz A. Transforaminal lumbar interbody fusion. *Orthop Clin N Am* 2002;33:359–366
- Schwender JD, Holly LT, Rouben DP, Foley KT. Minimally invasive transforaminal lumbar interbody fusion (TLIF): technical feasibility and initial results. *J Spinal Disord Tech* 2005;18(Suppl):S1–S6.
- Foley KT, Holly LT, Schwender JD. Minimally invasive lumbar fusion. *Spine* 2003;28[suppl]:S26–S35
- Burkus JK, Heim SE, Gornet MF, Zdeblick TA. Is INFUSE bone graft superior to autograft bone? An integrated analysis of clinical trials using the LT-CAGE lumbar tapered fusion device. *J Spinal Disorders Tech* 2003;16:113–122
- Boden SD, Zdeblick TA, Sandhu HS, Heim SE. The use of rhBMP-2 in interbody fusion cages. *Spine* 2000;25:376–381
- Sandhu HS, Tothjun Diwan AD, Seim HB, et al. Histologic evaluation of the efficacy of rhBMP-2 compared with autograft bone in sheep spinal anterior interbody fusion. *Spine* 2000;27:567–575
- Burkus JK, Transfeldt EE, Kitchel SH, et al. Clinical and radiographic outcomes of anterior lumbar interbody fusion using recombinant human morphogenetic protein-2. *Spine* 2002;27:2396–2408
- Burkus JK, Dorchak JD, Sanders DL. Radiographic assessment of interbody fusion using recombinant human bone morphogenetic protein type 2. *Spine* 2003;28:2372–2377
- Burkus JK. Bone morphogenetic proteins in anterior lumbar interbody fusion: old techniques and new technologies. *J Neurosurg Spine* 2004;1:254–260
- Blumenthal SL, Gill K. Can lumbar spine radiographs accurately determine fusion in post-operative patients? Correlation of routine radiographs with a second surgical look at lumbar fusions. *Spine* 1993;18:1186–1189
- Schuler TC, Subach BR, Branch CL, et al. Segmental lumbar lordosis: manual versus computer-assisted measurement using seven different techniques. *J Spinal Disord Tech* 2004;17:372–379
- Rothman SLG, Glenn WV Jr. CT evaluation of interbody fusion. *Clin Orthop Rel Res* 1985;193:47–56
- Chafetz N, Can CE, Morris JM, et al. Pseudarthrosis following lumbar fusion: detection by direct coronal CT scanning. *Radiology* 1987;162:803–805
- Cook SD, Patron LP, Christakis PM, et al. Comparison of methods for determining the presence and extent of anterior lumbar interbody fusion. *Spine* 2004;29:1118–1123
- Huang RC, Sandhu HS. The current status of lumbar total disc replacement. *Clin Orthop North Am* 2004;35:33–42
- Geisler FH, Blumenthal SL, Guyer RD, et al. Neurological complications of lumbar artificial disc replacement and comparison of clinical results with those related to lumbar arthrodesis in the literature: results of a multicenter, prospective, randomized investigational device exemption study of Charite intervertebral disc-invented submission from the Joint Section Meeting on Disorders of the Spine and Peripheral Nerves, March 2004. *J Neurosurg Spine* 2004;1:143–154