

# Generic Contrast Agents

Our portfolio is growing to serve you better. Now you have a *choice*.



[VIEW CATALOG](#)

# AJNR

## **2D Thick-Section MR Digital Subtraction Angiography for the Assessment of Dural Arteriovenous Fistulas**

N. Horie, M. Morikawa, N. Kitigawa, K. Tsutsumi, M. Kaminogo and I. Nagata

This information is current as of May 10, 2025.

*AJNR Am J Neuroradiol* 2006, 27 (2) 264-269  
<http://www.ajnr.org/content/27/2/264>

ORIGINAL  
RESEARCH

N. Horie  
M. Morikawa  
N. Kitigawa  
K. Tsutsumi  
M. Kaminogo  
I. Nagata

## 2D Thick-Section MR Digital Subtraction Angiography for the Assessment of Dural Arteriovenous Fistulas

**BACKGROUND AND PURPOSE:** Although dynamic contrast-enhanced MR angiography studies for arteriovenous malformations (AVFs) and brain tumors have shown promising results, no formal attempt has yet been made to similarly evaluate dural AVFs. To assess the practical applicability of 2D thick-section contrast enhanced MR digital subtraction angiography (MRDSA) for the diagnosis and management of dural AVFs, MRDSA and intra-arterial digital subtraction angiography (IADSA) were comparatively evaluated.

**METHODS:** We performed 80 consecutive MRDSA studies for 25 dural AVFs, including 11 cavernous sinuses, 9 sigmoid sinuses, 2 tentorial sinuses, one anterior condylar vein, one craniocervical junction, and one spine. MR images were continuously obtained following the initiation of a bolus injection of gadtrinium chelates and subtraction images were constructed. We thereafter evaluated the imaging quality and hemodynamic information from all 46 MRDSA images performed in parallel with IADSA in either perioperative or follow-up studies.

**RESULTS:** Most MRDSA images detected early venous filling, sinus occlusion, leptomeningeal venous drainage, and varices. It was difficult, however, to identify the feeding arteries because of both the partial volume effect and a low spatial resolution. Most important, MRDSA accurately detected aggressive lesions with leptomeningeal venous drainage and varices.

**CONCLUSION:** Our MRDSA technique was found to have limited value for depicting all the anatomic details of dural AVFs, though it was able to identify important hemodynamic abnormalities related to the risk of hemorrhaging. MRDSA is therefore useful as a less invasive, dynamic angiographic tool, not only for perioperative studies but also for follow-up studies.

Dural arteriovenous fistulas (dural AVFs) constitute 10%–15% of all intracranial arteriovenous anomalies.<sup>1,2</sup> Previous studies have indicated that dural AVFs are pathologic arteriovenous shunts and communications that occur within the layers of the dura matter.<sup>3</sup> They have been considered to be congenital lesions resulting from an enlargement of intradural arteriovenous shunts, but they are more likely to be secondary to events such as trauma, surgery, and infection.<sup>4–6</sup> Although they are generally classified according to the pattern of their venous drainage,<sup>2,7–10</sup> their wide anatomic distribution and variability result in a broad range of clinical presentations, including hemorrhage, focal neurologic deficits, seizures, or intracranial hypertension. Therefore, accurately identifying the hemodynamic features, including early venous filling, leptomeningeal venous drainage, varices, and circulation time, is essential for making a timely diagnosis of dural AVFs.

With regard to the hemodynamic evaluation, intra-arterial digital subtraction angiography (IADSA) remains the single diagnostic technique for a hemodynamic evaluation despite the fact that it is invasive with some complications.<sup>11,12</sup> Dynamic contrast-enhanced MRA studies have recently become increasingly useful as a noninvasive technique to evaluate the hemodynamics of the neck, aorta, and its abdominal branches, as well as the pelvis and lower extremity vessels.<sup>13–16</sup> In the central nervous system (CNS) area, however, no formal attempt has yet been established

to evaluate dural AVFs in the same manner, and only a few such studies have been reported.<sup>17–21</sup>

We herein postulate that we may be able to obtain valuable hemodynamic information, which is compatible with the data obtained by IADSA, by using the MR imaging technique in combination with a bolus contrast injection and thick-section 2D acquisition. In the present study, we comparatively evaluated MR digital subtraction angiography (MRDSA) and IADSA to assess the practical applicability of 2D thick-section MRDSA in the diagnosis and management of dural AVFs.

### Patients and Methods

Since 2000, our department has used MRDSA in addition to routine MR studies to evaluate patients with dural AVFs. Between January 2000 and March 2005, 25 consecutive patients (9 men and 16 women; mean age,  $64.3 \pm 12.0$  years) underwent MRDSA for perioperative and/or follow-up purposes. All patients also underwent standard IADSA for perioperative and/or follow-up purposes if necessary. We performed 80 consecutive MRDSA studies for 25 dural AVFs, including 11 cavernous sinuses, 9 sigmoid sinuses, 2 tentorial sinuses, one anterior condylar vein, one craniocervical junction, and one spine. Table 1 summarizes the patient characteristics. In this study, we evaluated 46 MRDSA images performed in parallel with IADSA for both preoperative ( $n = 24$ ) and postoperative ( $n = 22$ ) cases.

Regarding treatment, 17 patients with leptomeningeal venous drainage and/or varices were considered to be at high risk for hemorrhaging<sup>22–24</sup> and therefore were all treated. Four patients who did not have leptomeningeal venous drainage were considered to be at low risk for hemorrhaging, though they were treated because they had symptomatic bruit. The remaining 4 patients were treated conservatively, because they demonstrated benign dural AVFs with only an

Received April 6, 2005; accepted after revision June 21.

From the Department of Neurosurgery and Radiology, Nagasaki University School of Medicine, Nagasaki, Japan.

Address correspondence to Nobutaka Horie, MD, Department of Neurosurgery, Nagasaki University School of Medicine, 1-7-1, Sakamoto-machi, Nagasaki-shi, Nagasaki, 852-8501, Japan.

**Table 1: Patient characteristics**

Age (y)	64.3 ± 12.0 (37–88)
Sex (M:F)	9:16
Presentation	
Asymptomatic	1 (4%)
Tinnitus	8 (32%)
Headache	3 (12%)
Vertigo	1 (4%)
Myelopathy	1 (4%)
Chemosis	6 (24%)
Diplopia	1 (4%)
ICH	2 (8%)
SAH	2 (8%)
Location	
Cavernous	11 (44%)
Sigmoid	9 (36%)
Tent	2 (8%)
Anterior condylar	1 (4%)
Craniocervical	1 (4%)
Spine	1 (4%)
Treatment	
Observation	4 (16%)
IVR (TAE)	1 (4%)
IVR (TVE)	17 (68%)
IVR/craniotomy	3 (12%)
Follow-up (mo)	12.6 ± 11.4 (1–33)

**Note.**—ICH indicates intracerebral hemorrhage; SAH, subarachnoid hemorrhage; IVR, interventional radiology; TAE, transarterial embolization; TVE, transvenous embolization.

antegrade flow. Endovascular embolization alone (transarterial or transvenous embolization [TVA or TVE]) was performed for 18 patients, whereas combined therapy with endovascular embolization and surgical obliteration was performed for 3 patients and the remaining 4 patients

were treated conservatively. We performed MRDSA within the first through third preoperative day and within the first through third postoperative day. The patients underwent routine pre- and/or postcontrast MR imaging, including MR angiography along with MRDSA with a 1.5T MR device (Signa Horizon LX CV; GE Medical Systems, Milwaukee, Wisc). 2D MRDSA was performed by fast spoiled gradient recalled-echo sequence (TR/TE, 5.4/1.4; flip angle, 60°; field of view, 20 × 20 cm; matrix size, 256 × 128 BW; 31.2 kHz; section thickness [single section], 4–10 cm; scanning time, 0.8 seconds per scan). By using a power injector, we administered 0.2 mmol/kg of gadolinium chelates via the right antecubital vein at a rate of 4 mL/s. The injector started 5 seconds after the initiation of scanning and continued for 40–50 seconds. From these serial images, we selected a mask image (the last image before contrast arrival) and subtracted it from the images that followed by using the manufacturer's standard system software incorporated into the imager. In our system, the scanning interval is short enough to visualize the arterial component of the angioarchitecture. For this reason, it is not necessary to optimize the timing of the start of data collection in our system.

We comparatively evaluated the imaging quality of hemodynamic features, including the feeding arteries, early venous filling, sinus occlusion, leptomeningeal venous drainage (cortical reflux), varices, and a pseudophlebitic pattern (venous congestion) between MRDSA and IADSA. The image analysis was conducted independently by 2 observers (N.H. and M.M.) blinded to the IADSA findings during the initial reading.

## Results

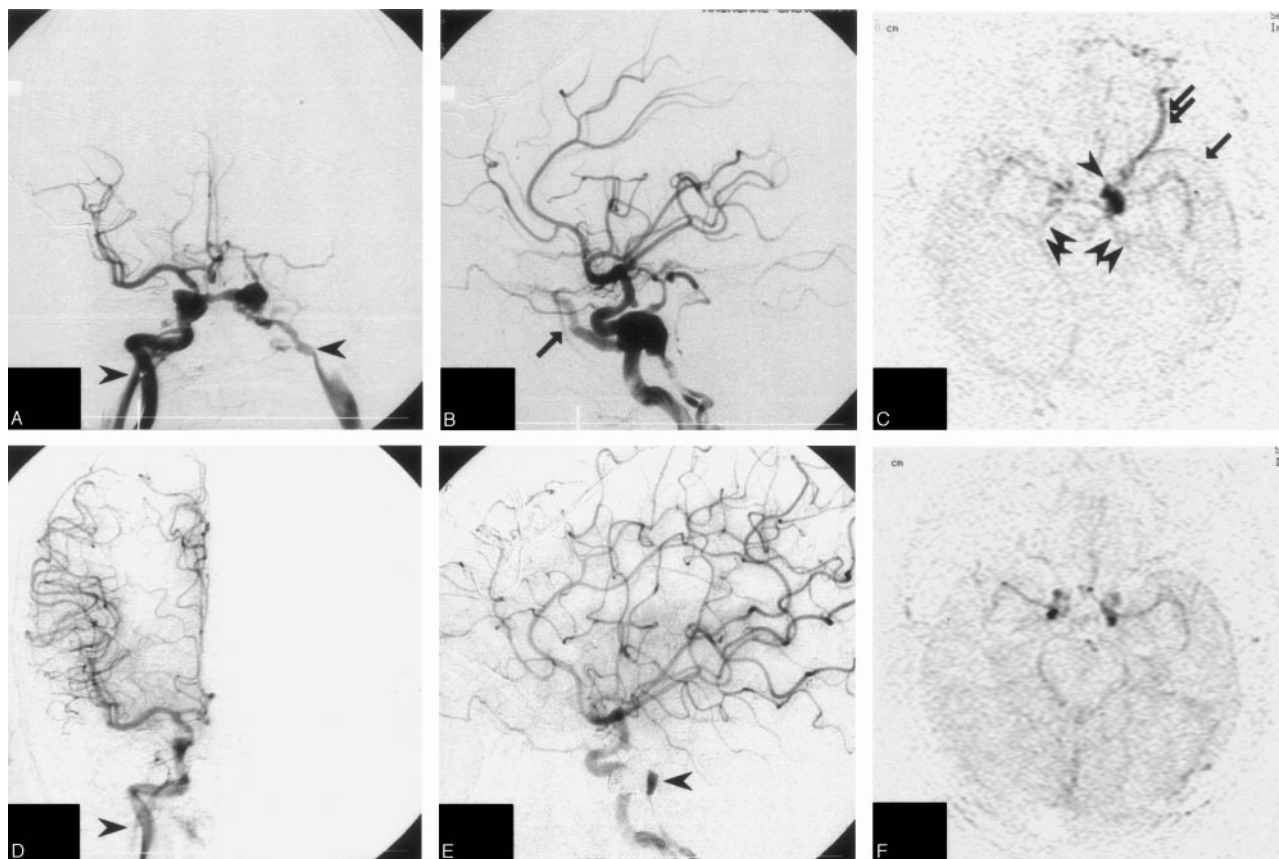
No complications were observed during the MRDSA procedures. We successfully obtained continuous serial hemody-

**Table 2: Detection of the presence of dural AVF by MRDSA and by IADSA**

	Reviewer	MRDSA		IADSA		Sensitivity (%)	Specificity (%)	Positive Predictive Value (%)	Negative Predictive Value (%)
		Present	Absent	Present	Absent				
Preoperative study									
Feeding arteries	R1	3	21	23	1	13.0	100	100	4.8
	R2	2	22			8.7	100	100	4.5
Early venous filling	R1	24	0	23	1	100	—*	95.8	0/0
	R2	24	0			100	—*	95.8	0/0
Sinus occlusion	R1	1	23	1	23	100	100	100	100
	R2	1	23			100	100	100	100
Leptomeningeal venous drainage	R1	12	12	16	8	75.0	100	100	66.7
	R2	14	10			87.5	100	100	80
Varices	R1	5	19	5	19	100	100	100	100
	R2	5	19			100	100	100	100
Pseudophlebitic pattern	R1	3	21	3	21	100	100	100	100
	R2	2	22			66.7	100	100	95.4
Postoperative and follow-up study									
Feeding arteries	R1	0	22	3	19	0	100	100	13.6
	R2	1	21			33.3	100	100	9.5
Early venous filling	R1	6	16	6	16	100	100	100	100
	R2	5	17			83.3	100	100	94.1
Sinus occlusion	R1	0	22	0	22	100	100	100	100
	R2	0	22			100	100	100	100
Leptomeningeal venous drainage	R1	2	20	1	21	—*	90.4	0/2	95.0
	R2	0	22			—*	100	100	95.4
Varices	R1	0	22	0	22	100	100	100	100
	R2	0	22			100	100	100	100
Pseudophlebitic pattern	R1	0	22	0	22	100	100	100	100
	R2	0	22			100	100	100	100

\* Not calculated because of the small number. R1 indicates reviewer 1; R2, reviewer 2.

**Note.**—AVF indicates arteriovenous fistula; MRDSA, magnetic resonance digital subtraction angiography; IADSA, intraarterial digital subtraction angiography.



**Fig 1.** A 68-year-old woman with left cavernous sinus dural AVF.

A-C, Preoperative IADSAs (A and B) show a cavernous sinus dural AVF with early filling in the bilateral inferior petrosal sinus (IPS; arrowheads) and the dilated superior ophthalmic vein (SOV; arrow). C, Preoperative MRDSA (axial) shows early venous filling in the cavernous sinus (arrowhead), IPS (double arrowheads), and reflux into the sphenoparietal sinus (arrows) and SOV (double arrows).

D-F, After TVE, IADSAs (D and E) show a small residual shunt (arrowhead) in the cavernous sinus. F, Postoperative MRDSA is unable to detect this shunt.

namic images in all 25 cases. Large cerebral vessels were clearly visualized on MRDSA in all cases. Smaller branches were also observed in all cases, but they tended to be less clear in comparison to the large vessels.

Table 2 summarizes the detection characteristics of dural AVF by MRDSA in comparison to the IADSA findings. Most MRDSA images detected early venous filling ( $>83.3\%$  sensitivity), sinus occlusion (100% for both sensitivity and specificity), and a pseudophlebitic pattern ( $>66.7\%$  sensitivity and 100% specificity) (Figs 1–3). Most important, MRDSA detected aggressive lesions with leptomeningeal venous drainage ( $>75.0\%$  sensitivity and 90.4% specificity) and varices (100% for both sensitivity and specificity). In a preoperative study, one false-positive with early venous filling and 2 false-negatives with leptomeningeal venous drainage were observed. In the postoperative and follow-up studies, on the other hand, 2 false-positives with leptomeningeal venous drainage, one false-negative with early venous filling, and one false-negative with leptomeningeal venous drainage were observed. Regarding the feeding arteries, MRDSA detected the main feeding artery in only 3 cases preoperatively and in one case postoperatively. The middle meningeal artery was seen on axial images (1 of 22 cases), and the occipital artery and the tentorial artery were seen on sagittal images (3 of 12 cases). The sensitivity for detecting feeding arteries was low (0%–33.3%). MR angiography source imaging was more useful for detecting feeding ar-

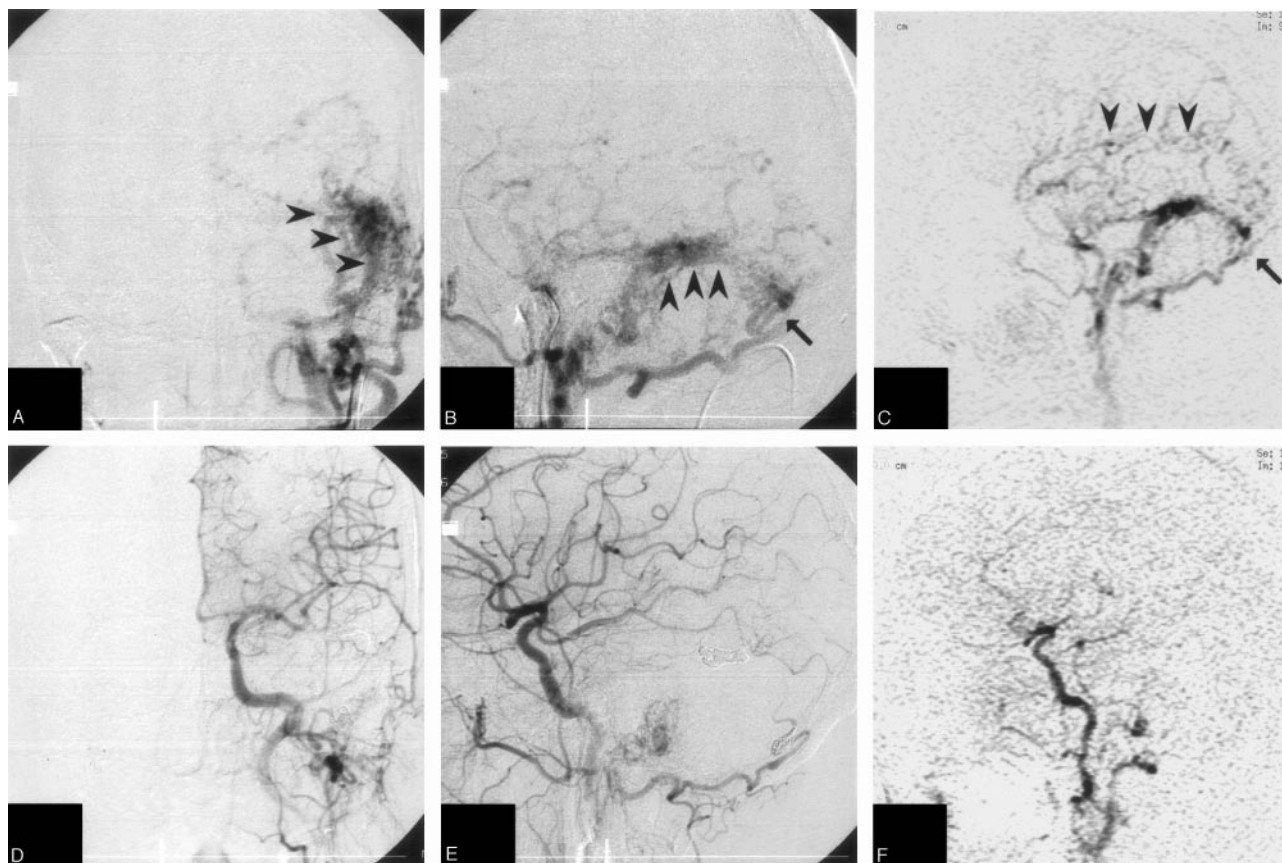
teries in all cases. In our series, the feeding arteries were easy to detect in aggressive lesions with varices or a pseudophlebitic pattern (Fig 2).

In the follow-up study, we performed MRDSA for 22 cases as outpatient examinations (mean follow-up of  $12.6 \pm 11.4$  months). One case with a cavernous dural AVF was suspected to have a recurrence based on the MRDSA findings at 26 months after the primary treatment, and these findings were compatible to those of the IADSA study. We performed a second embolization for this case. The detection rate for the recurrent dural AVFs after a complete obliteration was 100% (1/1), though it was a small number. Representative cases are illustrated in Figs 1–3.

## Discussion

Cranial dural AVFs and spinal dural AVFs can be classified as aggressive based on the presence of leptomeningeal venous reflux either with or without varices.<sup>25</sup> The presence of varices on a draining vein or leptomeningeal venous drainage has also been reported to increase the risk of hemorrhaging.<sup>22</sup> Moreover, Willinsky et al indicated that the cases with a pseudophlebitic pattern (tortuous and elongated veins on the venous phase) are associated with an aggressive presentation with or without retrograde leptomeningeal venous drainage in an IADSA study.<sup>26</sup> The rate of hemorrhaging in these lesions without previous bleeding was 1.8% per year.<sup>22</sup> With regard to





**Fig 2.** A 69-year-old woman with a left sigmoid sinus dural AVF presenting with intracranial hemorrhaging.

*A and B*, Preoperative IADSAs show a sigmoid sinus dural AVF with aggressive leptomeningeal drainage (*arrowheads*). The main feeding artery is shown to be the occipital artery (*arrow*). *C*, Preoperative MRDSA (sagittal) shows early venous filling with a pseudophlebitic pattern (venous congestion; *arrowheads*). The main feeding artery is shown to be the occipital artery (*arrow*).

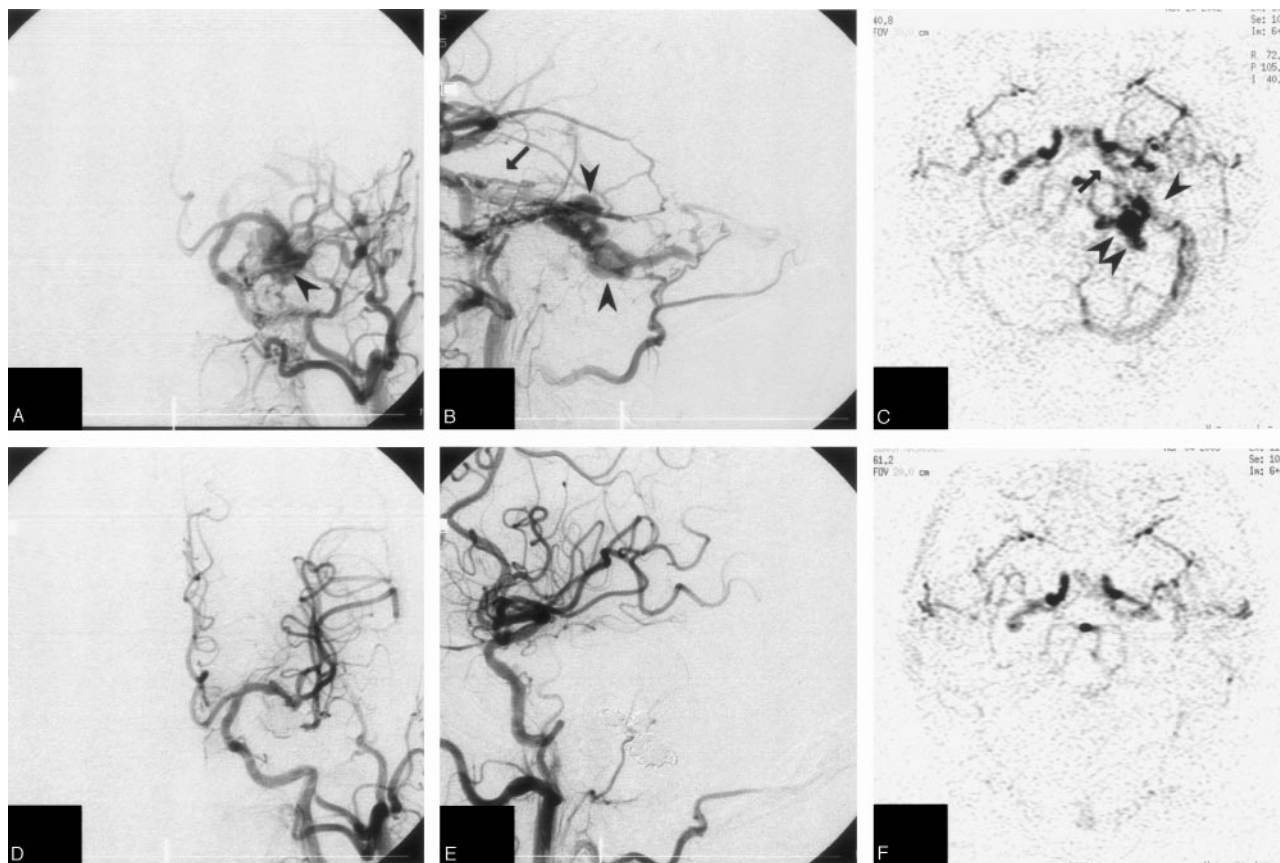
*D and E*, After TVE, IADSAs show the disappearance of the dural AVF. *F*, Postoperative MRDSA is unable to detect this shunt.

the rebleeding of dural AVFs exhibiting intracranial hemorrhaging, dural AVFs with retrograde leptomeningeal venous drainage have been reported to show a high risk of early rebleeding (35% within 2 weeks after the first hemorrhage) and normally with graver consequences than the first hemorrhage.<sup>27</sup> We, therefore, advocate complete and early treatment in all cases of dural AVFs with leptomeningeal venous drainage due to an intracerebral hemorrhage. On the basis of these previous reports, a clear angiographic analysis, primarily for the venous drainage systems, is thus suggested to be the first step in the treatment of dural AVFs. Moreover some reports have also suggested that a careful angiographic follow-up of patients is required even after successful therapy because they have a possibility to develop into either recurrent dural AVFs or second dural AVFs.<sup>28-31</sup>

In a radiographic analysis for dural AVFs, IADSA has been the standard technique. This technique, however, is invasive, with an estimated complication rate of approximately 0.5%–1.3%.<sup>11,12</sup> On the other hand, conventional CT and standard MR techniques are of limited value in the diagnosis and classification of dural AVFs.<sup>18</sup> These methods provide only static images of dural AVFs. Contrast-enhanced time-of-flight (TOF) MRA may allow the visualization of an abnormal arterial flow and a static venous anatomy, but only MRDSA provides a dynamic assessment of the cerebral circulation. An assessment of the dynamic flow patterns plays an important

role in the radiographic diagnosis of dural AVFs. Our goal in this study was to depict the hemodynamics of dural AVFs by using the 2D thick-section MRDSA.

Dynamic contrast-enhanced MR angiography has rapidly become the technique of choice for the assessment of lesions in the neck, aorta and its abdominal branches, as well as the pelvis, and extremities.<sup>13-16</sup> In the CNS area, hemodynamic information from images with a high temporal resolution is essential for accurately diagnosing specific cerebrovascular diseases, including an evaluation of collateral flows and leptomeningeal anastomosis in atherosclerosis or Moyamoya disease, the circulation time in sinus thrombosis, and for the observation of early venous filling of arteriovenous malformations (AVMs). Although spin-echo images and TOF angiography might show findings suggestive of dural AVFs, the impact of dynamic MR projection angiography on the improved detection of dural AVFs is evident.<sup>18</sup> Moreover, the use of subtraction seems to be quite effective in cases associated with hematoma.<sup>32</sup> In addition, a short measurement time is beneficial for MRDSA because motion artifacts are not encountered. Even so, motion artifacts have a tremendous effect on the image quality. To avoid such motion artifacts, we instructed the patient to remain still for the duration of scanning (40–50 seconds). Moreover, we used soft pads to fix the head. These techniques were sufficient to obtain clear subtracted images. We did not use any registration technique such as



**Fig 3.** A 69-year-old man with left tentorial sinus dural AVF presenting with an intracranial hemorrhage.

*A-C*, Preoperative IADSAs (*A* and *B*) show a tentorial sinus dural AVF with varices (arrowheads). The main feeding artery is shown to be the tentorial artery (arrow). *C*, Preoperative MRDSA (axial) shows early venous filling (arrowhead) with varices (double arrowhead). The main feeding artery is shown to be the tentorial artery (arrow).

*D-F*, After TVE, IADSAs (*D* and *E*) show the disappearance of the dural AVF. *F*, Postoperative MRDSA shows no abnormal pattern.

pixel shifting. The greatest advantage of MRDSA is that the display of 2D MRDSA mimics IADSA, which is a very familiar diagnostic tool for neuroradiologists and neurosurgeons. Some clinical studies have shown the usefulness of MRDSA in assessing AVMs<sup>17,32-34</sup> and brain tumors.<sup>35,36</sup> There have been no clinical evaluations reported so far, though several case studies have been reported on the significance of MRDSA for assessing dural AVFs.<sup>17-21</sup>

In the present study, MRDSA showed hemodynamic information that mimicked IADSA in all cases. Most MRDSA images detected early venous filling, sinus occlusion, and a pseudophlebitic pattern. As a result, abnormalities in MRDSA always indicate abnormalities in IADSA, but not vice versa. Moreover, MRDSA, like IADSA, detected aggressive lesions with leptomeningeal venous drainage (>75% sensitivity and 90.4% specificity) and varices (100% for both sensitivity and specificity), which were associated with a risk of hemorrhaging.<sup>22,25</sup> MRDSA can thus indicate the important hemodynamic abnormalities related to the risk of hemorrhaging. Regarding the angiographic grading such as Cognard classification,<sup>8</sup> which classified the venous drainage pattern, MRDSA could sufficiently classify the grades of Cognard without IADSA findings. MRDSA detected the venous flow pattern clearly in all cases. On the other hand, a careful follow-up examination is necessary after the treatment, because the complete obliteration rate has been reported to be 60% in TAE<sup>37</sup>

and 80% in TVE.<sup>38</sup> We consider this technique to be valuable especially for follow-up purposes after the treatment because it is less invasive than IADSA. MRDSA is very effective for identifying an abnormal flow not only preoperatively but also postoperatively.

There are some disadvantages when making assessments by using MRDSA. First, only one or 2 (axial, coronal, or sagittal) planes are obtained.<sup>39</sup> We chose the axial plane for assessing cavernous dural AVFs, tentorial dural AVFs, anterior condylar dural AVFs, and craniocervical dural AVFs, the sagittal plane for sigmoid dural AVFs, and the coronal plane for spinal dural AVFs, to avoid any overlapping with normal vessels. If we chose an inadequate direction of the image, it would be difficult to evaluate the hemodynamic information in detail on MRDSA, and therefore the findings would be misleading. Second, small feeding arteries are often obscured, probably because of a partial volume effect and a low spatial resolution.<sup>32,39</sup> In our study, MRDSA failed to detect small abnormalities such as feeding arteries and a residual shunt. MR angiography source images that performed along with the MRDSA help to detect the feeding arteries and maybe shunt surgery points in combination with MRDSA. The feeding artery, however, is not so important for diagnosing and classifying the dural AVFs. With regard to the presence of a residual shunt, we suspect it when there is a discrepancy between the symptoms and the MRDSA findings; however, most cases with

a low-flow residual shunt without leptomeningeal venous drainage or varices are treated conservatively. When a residual shunt grows into an aggressive fistula that requires an operation, follow-up MRDSA can certainly detect such an abnormality. Overall, MRDSA can show sufficient information regarding the angioarchitecture concerning flow pattern including early venous filling, sinus occlusion, leptomeningeal venous drainage, and varices.

At the present time, MRDSA cannot replace IADSA because of these disadvantages. The present findings, however, suggest that this technique is highly effective for evaluating dural AVFs, especially for aggressive lesions, which should be treated, in both perioperative and follow-up studies. The most important point is that MRDSA reduces the patient psychological burden because this technique is much less invasive than IADSA. MRDSA is useful, especially for outpatient examinations. We suppose that MRDSA will become the technique of choice for the assessment of dural AVFs. IADSA is necessary as an additional examination only when the treatment is necessary or recurrence is suspected on the basis of the MRDSA findings. Indeed, MRDSA was able to detect one recurrence in our series. This technique will allow neuroradiologists the ability to avoid performing IADSA for examinations.

## Conclusions

The 2D thick-section MRDSA technique is considered to be limited in depicting all the anatomic details of dural AVFs. MRDSA, however, is highly effective for evaluating dural AVFs, especially for the aggressive conditions that require treatment, in both perioperative and follow-up studies. We suppose that in the future MRDSA will become the technique of choice instead of IADSA for the assessment of dural AVFs.

## References

1. Thompson BG, Doppman JL, Oldfield EH. Treatment of cranial dural arteriovenous fistulae by interruption of leptomeningeal venous drainage. *J Neurosurg* 1994;80:617–23
2. Borden JA, Wu JK, Shucart WA. A proposed classification for spinal and cranial dural arteriovenous fistulous malformations and implications for treatment. *J Neurosurg* 1995;82:166–79
3. Barnwell SL, Halbach VV, Dowd CF, et al. Multiple dural arteriovenous fistulas of the cranium and spine. *AJNR Am J Neuroradiol* 1991;12:441–45
4. Bitoh S, Hasegawa H, Fujiwara M, et al. Traumatic arteriovenous fistula between the middle meningeal artery and cortical vein. *Surg Neurol* 1980;14:355–58
5. Kurl S, Vanninen R, Saari T, et al. Development of right transverse sinus dural arteriovenous malformation after embolisation of a similar lesion on the left. *Neuroradiology* 1996;38:386–88
6. Malik GM, Mahmood A, Mehta BA. Dural arteriovenous malformation of the skull base with intraosseous vascular nidus. Report of two cases. *J Neurosurg* 1994;81:620–3
7. Djindjian R. [Embolization of vascular abnormalities in the head-face region using superselective arteriography of the external carotid artery]. *Fortschr Kiefer Gesichtschir* 1977;22:164–67
8. Cognard C, Gobin YP, Pierot L, et al. Cerebral dural arteriovenous fistulas: clinical and angiographic correlation with a revised classification of venous drainage. *Radiology* 1995;194:671–80
9. Lalwani AK, Dowd CF, Halbach VV. Grading venous restrictive disease in patients with dural arteriovenous fistulas of the transverse/sigmoid sinus. *J Neurosurg* 1993;79:11–15
10. Barrow DL, Spector RH, Braun IF, et al. Classification and treatment of spontaneous carotid-cavernous sinus fistulas. *J Neurosurg* 1985;62:248–56
11. Heiserman JE, Dean BL, Hodak JA, et al. Neurologic complications of cerebral angiography. *AJNR Am J Neuroradiol* 1994;15:1401–407; discussion 1408–11
12. Willinsky RA, Taylor SM, TerBrugge K, et al. Neurologic complications of cerebral angiography: prospective analysis of 2,899 procedures and review of the literature. *Radiology* 2003;227:522–18. Epub 2003 Mar 13

13. Aoki S, Nakajima H, Kumagai H, et al. Dynamic contrast-enhanced MR angiography and MR imaging of the carotid artery: high-resolution sequences in different acquisition planes. *AJNR Am J Neuroradiol* 2000;21:381–85
14. Willig DS, Turski PA, Frayne R, et al. Mistretta CA, Grist TM. Contrast-enhanced 3D MR DSA of the carotid artery bifurcation: preliminary study of comparison with unenhanced 2D and 3D time-of-flight MR angiography. *Radiology* 1998;208:447–51
15. Prince MR. Gadolinium-enhanced MR aortography. *Radiology* 1994;191:155–64
16. Leung DA, McKinnon GC, Davis CP, et al. Breath-hold, contrast-enhanced, three-dimensional MR angiography. *Radiology* 1996;200:569–71
17. Klisch J, Strecker R, Hennig J, et al. Time-resolved projection MRA: clinical application in intracranial vascular malformations. *Neuroradiology* 2000;42:104–107
18. Aoki S, Yoshikawa T, Hori M, et al. MR digital subtraction angiography for the assessment of cranial arteriovenous malformations and fistulas. *AJR Am J Roentgenol* 2000;175:451–53
19. Wetzel SG, Bilecen D, Lyrer P, et al. Cerebral dural arteriovenous fistulas: detection by dynamic MR projection angiography. *AJR Am J Roentgenol* 2000;174:1293–95
20. Coley SC, Romanowski CA, Hodgson TJ, et al. Dural arteriovenous fistulae: noninvasive diagnosis with dynamic MR digital subtraction angiography. *AJNR Am J Neuroradiol* 2002;23:404–07
21. Farb RI, Kim JK, Willinsky RA, et al. Spinal dural arteriovenous fistula localization with a technique of first-pass gadolinium-enhanced MR angiography: initial experience. *Radiology* 2002;222:843–50
22. Brown RD, Jr., Wiebers DO, Nichols DA. Intracranial dural arteriovenous fistulae: angiographic predictors of intracranial hemorrhage and clinical outcome in nonsurgical patients. *J Neurosurg* 1994;81:531–38
23. van Dijk JM, terBrugge KG, Willinsky RA, et al. Clinical course of cranial dural arteriovenous fistulas with long-term persistent cortical venous reflux. *Stroke* 2002;33:1233–36
24. Satomi J, van Dijk JM, terBrugge KG, et al. Benign cranial dural arteriovenous fistulas: outcome of conservative management based on the natural history of the lesion. *J Neurosurg* 2002;97:767–70
25. Lasjaunias P, Chiu M, terBrugge K, et al. Neurological manifestations of intracranial dural arteriovenous malformations. *J Neurosurg* 1986;64:724–30
26. Willinsky R, Goyal M, terBrugge K, et al. Tortuous, engorged pial veins in intracranial dural arteriovenous fistulas: correlations with presentation, location, and MR findings in 122 patients. *AJNR Am J Neuroradiol* 1999;20:1031–36
27. Duffau H, Lopes M, Janosevic V, et al. Early rebleeding from intracranial dural arteriovenous fistulas: report of 20 cases and review of the literature. *J Neurosurg* 1999;90:78–84
28. Nakagawa H, Kubo S, Nakajima Y, et al. Shifting of dural arteriovenous malformation from the cavernous sinus to the sigmoid sinus to the transverse sinus after transvenous embolization. A case of left spontaneous carotid-cavernous sinus fistula. *Surg Neurol* 1992;37:30–38
29. Yamashita K, Taki W, Nakahara I, et al. Development of sigmoid dural arteriovenous fistulas after transvenous embolization of cavernous dural arteriovenous fistulas. *AJNR Am J Neuroradiol* 1993;14:1106–08
30. Kubota Y, Ueda T, Kaku Y, et al. Development of a dural arteriovenous fistula around the jugular valve after transvenous embolization of cavernous dural arteriovenous fistula. *Surg Neurol* 1999;51:174–76
31. Kiyosue H, Tanoue S, Okahara M, et al. Recurrence of dural arteriovenous fistula in another location after selective transvenous coil embolization: report of two cases. *AJNR Am J Neuroradiol* 2002;23:689–92
32. Tsuchiya K, Katase S, Yoshino A, et al. MR digital subtraction angiography of cerebral arteriovenous malformations. *AJNR Am J Neuroradiol* 2000;21:707–11
33. Griffiths PD, Hoggard N, Warren DJ, et al. Brain arteriovenous malformations: assessment with dynamic MR digital subtraction angiography. *AJNR Am J Neuroradiol* 2000;21:1892–99
34. Mori H, Aoki S, Okubo T, et al. Two-dimensional thick-slice MR digital subtraction angiography in the assessment of small to medium-size intracranial arteriovenous malformations. *Neuroradiology* 2003;45:27–33
35. Yoshikawa T, Aoki S, Hori M, et al. Time-resolved two-dimensional thick-slice magnetic resonance digital subtraction angiography in assessing brain tumors. *Eur Radiol* 2000;10:736–44
36. Tsuchiya K, Katase S, Yoshino A, et al. MR digital subtraction angiography in the diagnosis of meningiomas. *Eur J Radiol* 2003;46:130–38
37. Halbach VV, Higashida RT, Hieshima GB, et al. Transvenous embolization of dural fistulas involving the transverse and sigmoid sinuses. *AJNR Am J Neuroradiol* 1989;10:385–92
38. Urtasun F, Biondi A, Casaco A, et al. Cerebral dural arteriovenous fistulas: percutaneous transvenous embolization. *Radiology* 1996;199:209–17
39. Aoki S, Yoshikawa T, Hori M, et al. Two-dimensional thick-slice MR digital subtraction angiography for assessment of cerebrovascular occlusive diseases. *Eur Radiol* 2000;10:1858–64