



Providing Choice & Value

Generic CT and MRI Contrast Agents



**FRESENIUS
KABI**

CONTACT REP

AJNR

**Imaging of the Nervous System: Diagnostic
and Therapeutic Applications, Vols. 1 and 2**

AJNR Am J Neuroradiol 2006, 27 (5) 1158-1160

<http://www.ajnr.org/content/27/5/1158>

This information is current as
of July 29, 2025.

Surprisingly (and to this reviewer somewhat disheartening), the chapter, "Structural and Functional Magnetic Resonance Imaging in Neurodegenerative Diseases," has 2 authors, neither of whom is a neuroradiologist. Most images shown in this chapter came not from the authors' own experience but from other clinicians' files or previously published material. Although this feature is not, by itself, a major problem, one always likes to read chapters in which the authors present their own material, not material from others. As for the chapter itself, the authors say that it focuses on "nonroutine structural MR imaging," then other than some functional MR imaging (fMRI) images, they proceed to show virtually all routine MR imaging. One wonders where DTI, blood volume maps, and PWI are if this chapter covers nonroutine MR imaging? The authors mention MR microscopy as having "very high spatial resolution," but they do not tell the reader how they define high spatial resolution. Information on DWI, tractography, and DTI is so scant that it is not valuable, and to top it off, no representative images of the latter are shown. Findings are mentioned under many of the diseases (eg, under extrapyramidal disease) but are not illustrated, adding to the problems with the material in this chapter. A valuable item would have been a chart that lists individually the various dementias, extrapyramidal disorders, motor system disorders, and ataxias, enumerating the imaging findings in each. A more complete section of the chapter is one that deals with fMRI in neurodegenerative disease, in which the basic concepts of cortical activation are described and are accompanied by a few illustrations. In summary, this chapter is disappointing and would not be the recommended source for learning the imaging characteristics of neurodegenerative disease. If a new edition of the book is planned, the authors and coauthors of the structural MR imaging chapter should include a neuroradiologist.

The remaining 2 chapters in part 2 of the book, "Neuroimaging in Neurodegeneration," deal with single-photon emission CT/PET and MR spectroscopy of neurodegenerative illnesses and are basic and adequate. What the clinical role is or ever will be for spectroscopy in neurodegenerative disease is questionable, particularly phosphorus and carbon spectroscopy, on which the authors spend some time. The other part of the book that could have been of interest to the radiologist is the section, "Normal Aging." Here the 2 chapters describe the clinical aspects and neuropathology of normal aging. Although there is mention and 1 T1-weighted MR imaging example of a healthy older patient, the lack of a separate chapter on the imaging of aging with appropriate examples is a drawback of this part of the book.

For the neuroradiologist then, how would this book fit into his or her collection or a departmental library? It would be for those with a particular interest in the various clinical syndromes and diseases in neurodegeneration. For example, as would be expected, considerable space is devoted to Alzheimer disease (neuropathology genetics and the role of beta amyloid),

prion diseases, Parkinson disease/Parkinsonism and related movement disorders, and motor neuron disease. A lack of adequate imaging and a failure to integrate imaging in an important way in all of these chapters diminishes the potential interest of the book to neuroradiologists. Nonetheless, for those interested in a deeper clinical and neuropathologic understanding of these degenerative diseases, this book will be useful.

BOOK REVIEW

Imaging of the Nervous System: Diagnostic and Therapeutic Applications, Vols. 1 and 2


Edited by Richard E. Latchaw, John Kucharczyk, and Michael E. Moseley. Philadelphia, Pa: Elsevier Mosby; 2005, \$295.

The ever-growing field of neuroradiology requires knowledge of basic and clinical sciences, as well as multi-imaging techniques. The authors set out with the ambitious goal of providing an integrative approach to these subjects. To meet this goal, they recruited a total of 153 contributors, most of whom are well known in their respective fields. There is representation from neuroradiologists, physicists, neurologists, neurosurgeons, neuroanatomists, and physiologists. With their help, Drs. Latchaw, Kucharczyk, and Moseley have created a comprehensive textbook covering state-of-the-art diagnostic and therapeutic techniques, while providing the necessary scientific and clinical background to make the reader a more effective communicator with nonradiology colleagues.

The book is divided into 7 major parts. Part 1 addresses imaging principles. There is ample discussion of MR imaging, CT, positron-emission tomography (PET), single-photon emission CT or tomography (SPECT), functional MR imaging (fMRI), MR spectroscopy, magnetoencephalography (MEG), and magnetic source imaging (MSI). The second part is the most extensive. It is divided into 8 sections focusing on cerebrovascular disease.

The first 2 chapters are rarely found in a radiology textbook. They discuss the pathophysiology of cerebral ischemia and the epidemiology and clinical presentation of stroke and include animal models of ischemia and the biochemistry of stroke. The next chapter is one of this reviewer's favorites. It consists of a series of beautifully illustrated plates describing the functional anatomy of the brain as it relates to different vascular territories. These illustrations are followed by a detailed section on stroke imaging. It includes CT, MR imaging, diffusion-weighted imaging, diffusion tensor imaging, and sodium MR imaging.

The subsequent section gives a comprehensive discussion of cerebral perfusion imaging. Chapters cover xenon-enhanced CT, CT perfusion, contrast and arterial spin-labeled MR perfusion, and SPECT. The chapter on MR perfusion emphasizes the mathematics and physics behind this technique. Radiologists in private practice might not find this chapter interest-



ing; however, it contains a great table at the end summarizing suggested scanning parameters for a stroke protocol.

The following section emphasizes the vascular imaging of stroke and includes conventional angiography, MR angiography (MRA), CT angiography, and transcranial and carotid Doppler sonography. The MRA chapter proves to be the best one in this section. There is a thorough review of technique, pitfalls, and imaging optimization. The inclusion of transcranial Doppler sonography is interesting in a radiology textbook because this technique has been taken over primarily by neurologists. This chapter is well written and straightforward.

Section 5 seems to be most relevant for neurointerventional radiologists and stroke neurologists. It primarily describes different endovascular approaches used in the treatment of stroke and atherosclerotic disease. There is also discussion on the use of intravenous tissue plasminogen activator (tPA). This section is followed by a discussion of the pathophysiology, clinical presentation, and epidemiology of nontraumatic intracranial hemorrhage. The seventh section emphasizes the imaging of different causes for intracranial hemorrhage including a chapter on the appearance of blood on MR imaging at different stages. Part 2 of this book culminates in a discussion of the imaging and treatment of cerebral aneurysms and vascular malformations.

Part 3 discusses nonvascular disease entities of the brain. It is the second longest part and is divided into 8 sections. The first section covers both intra- and extra-axial brain neoplasms. There is a brief discussion on the evaluation of these entities with diffusion, perfusion, and PET imaging. The chapter on extra-axial masses provides valuable tables on the differential diagnosis of various lesions based on location. A chapter on metastatic disease will be a favorite of radiology residents studying for the boards as well as practicing radiologists. It provides a series of tables giving differential diagnoses based on imaging findings (eg, leptomeningeal enhancement). This chapter is followed by an equally excellent summary of head trauma imaging.

The next section deals with infectious, inflammatory, and demyelinating diseases of the brain. There are excellent chapters discussing infections in both the immunocompetent and immunocompromised host. These chapters emphasize the use of diffusion and perfusion imaging as well as MR spectroscopy. A brief chapter on demyelinating disease focuses on multiple sclerosis. The next section deals with orbital disease, including masses, trauma, and inflammation. It is comprehensive, well illustrated, well written, and is followed by an

equally excellent discussion of sellar and suprasellar lesions. Section 6 discusses brain and spine CSF flow with many CSF flow cine examples provided. Degenerative, metabolic, and neurobehavioral disease are well covered in the next section. The last section includes epilepsy imaging and provides emphasis on fMRI, PET, SPECT, MEG, and MSI.

Part 4 is a brief but excellent discussion of pediatric

imaging. Topics include normal brain development and cerebrovascular, metabolic, and neurodegenerative diseases, as well as epilepsy. There are examples of normal in utero development evaluated by MR imaging and also one of the most comprehensive tables this reviewer has seen on normal brain myelination. A chapter on metabolic diseases has exquisite images with MR spectroscopy correlation. The chapter on epilepsy presents material that has already been covered elsewhere in the book, and unfortunately, some of the images in this chapter are suboptimal.

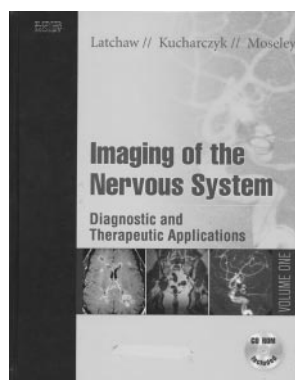
Part 5 is a bit unusual for a radiology textbook. It has an all-inclusive discussion of "Image Guidance for the Therapy of Parenchymal Disorders." CT- and MR imaging-guided neuronavigation systems and a chapter on intraoperative sonography are areas that would be most useful for a neurosurgeon. The next chapter on CT-guided aspirations and biopsies concentrates on skull base lesions; most radiologists who perform biopsies will enjoy reading it. The following chapters cover interventional MR imaging systems, cryotherapy, thermal therapy, MR imaging-guided endovascular procedures, and drug therapy. Although these chapters are interesting, they will probably be useful only for the small group of interventional neuroradiologists performing these highly subspecialized procedures.

Part 6 treats the reader to the emerging field of MR imaging of the peripheral nervous system and includes a very useful section on technique. The most common disease entities are well represented and are augmented by beautiful schematic representations.

The last part discusses spine imaging and intervention. It is divided into 2 sections: degenerative disease and pain management, and nondegenerative diseases. The first chapter discusses the most common subject that neuroradiologists face on a day-to-day basis—degenerative spine disease. It takes the reader through the natural history of classification and surgical complications of these diseases. It contains a plethora of crisp images that make the chapter very enjoyable. The next chapters discuss the controversial field of diskography and imaging-guided spine pain management. The second section of this part opens with spine trauma with an emphasis on CT and MR imaging, including a discussion on the importance of MR cine imaging in the diagnosis of delayed complications. A brief introduction to vertebroplasty is provided in the next chapter. Additional chapters discuss neoplasms and inflammatory and infectious processes of the spine. The book ends with excellent chapters on evaluation and treatment of vascular lesions of the spine, spine biopsies, and congenital anomalies of the spine. Some subjects that this reviewer would like to see within the spine section of the book in future editions include Guillain-Barré syndrome, chronic inflammatory demyelinating polyneuropathy, rheumatoid arthritis, ankylosing spondylitis, and hereditary motor and sensory neuropathies.

Also provided is a valuable CD-ROM, which contains all 3100 images with accompanying legends and case studies. It includes a search function that displays all the images related to 1 subject. Moreover, one can then import selected images into PowerPoint for Windows (Microsoft, Redmond, Wash) and create a presentation.

Overall, Drs. Latchaw, Kucharczyk, and Moseley have created a comprehensive and innovative book on the diagnosis



and treatment of the nervous system. Its integration of radiology, physics, physiology, and clinical medicine is a refreshing and unique approach on the subject. The book provides the reader state-of-the-art techniques and crisp images. Radiologists, neurologists, neurosurgeons, and physicists conducting nervous system research would very likely find this book extraordinarily useful.

BOOKS BRIEFLY NOTED

Radiology Oral Board Review: A Keyword Approach

Kristen Freestone, ed. Elsevier; 2005, 592 pages, 10 illustrations, \$69.95.

If one had in his or her radiology residency program an ambitious, compulsive, and copious note taker, and if that resident organized the notes according to specialty areas, a book like this would be the result. Snippets of information are presented in a staccato-like fashion; however, with no images or illustrations, one wonders about the educational value of such a product. The editor indicates that this publication is well suited for preparation for the oral boards in radiology, but this reviewer doubts that. The book may help with the written boards, but it will not serve as a primary vehicle for oral boards preparation. Topics of interest are followed by summary points on each entity. Most descriptions are adequate; other descriptions are too brief to be of great value. This book could be useful in the setting of fourth-year residents, showing one another cases as they prepare for the oral board examinations and using the information listed under each diagnosis to elicit more details on the entity shown. It certainly is not a book that will be read from cover to cover, but this might be a publication for a departmental library to purchase, as it may be a helpful adjunct for residents preparing for the written board examinations.

Radiology Review: Radiologic Physics

Edward L. Nickoloff, ed. Elsevier; 2005, 272 pages, 113 illustrations, \$59.95.

As the amount of material in radiologic physics that residents are required to know for their written board examinations grows, the need expands for straightforward, easily digestible material in physics. With this soft-cover publication, Dr. Nickoloff presents the reader with 21 chapters covering the properties and production of x-rays and their biologic effect on matter; the characteristics of x-ray tubes, filters, collimators, grids, and screens; film properties; computers; digital radiography; radiation biology and safety; mammography; fluoroscopy; computed tomography; magnetic resonance imaging; ultrasound; and nuclear medicine. What makes this book useful is the manner in which the material is presented. Specifically, in each chapter the basic concepts are clearly described with good tabular and graphic material, fol-

lowed by a series of multiple-choice questions. Answers to questions are then provided in the last portion of each chapter with succinct explanations of the material.

Not only would this book serve as an excellent source of information to prepare for the physics board examinations, but it could be used by all practicing radiologists who desire a straightforward and clear review of the important aspects of radiation physics.

Spinal Instrumentation Surgical Techniques

Daniel H. Kim, Alexander R. Vaccaro, and Richard G. Fessler.
Thieme Medical Publishers; 2006, 1330 pages, 1103 illustrations, \$299.95.

In a large (1330 pages) and complete textbook, Drs. Kim, Vaccaro, and Fessler have gathered in one volume the contributions of 239 authors who discuss and richly illustrate with plain radiographs, computed tomographs, magnetic resonance images, drawings, and photographs the varied aspects of spine instrumentation. With the increasing popularity of instrumented fusions, intradiscal devices, and new prosthetic material, the radiologist is frequently presented with hardware and constructs with which he or she is unfamiliar. With this exhaustive and complete publication, it would seem that virtually every system one would encounter on plain radiographs or on computed tomographs is covered.

In brief, the book is divided into 12 sections: Craniocervical Junction (7 chapters); Anterior Cervical Spine (31 chapters); Posterior Cervical Spine (31 chapters); Cervicothoracic Junction (5 chapters); Anterior Thoracic and Thoracolumbar Junction (20 chapters); Posterior Thoracic and Thoracolumbar Junction (16 chapters); Anterior Lumbar Spine (15 chapters); Posterior Lumbar Spine (33 chapters); Lumbosacral Junction and Sacrum (5 chapters); Allografts/Synthetics (7 chapters); and a miscellaneous section (3 chapters, including the very last chapter on Image-Guided Spinal Surgery). Clearly with 166 chapters and an estimated 8-pound payload, this is neither a book to read cover to cover or one to be carried about. Nonetheless, with its excellent drawings, detailed surgical descriptions, comments on surgical complications, and the wide-ranging imaging of instrumentation, this is a book that should be available in a department of radiology where imaging service is provided to a high volume of orthopedic and neurosurgical spine surgery.

BOOKS RECEIVED

Adrenaline and the Inner World: An Introduction to Scientific Integrative Medicine. David S. Goldstein, ed. Johns Hopkins University Press; 2006, 328 pages, 49 illustrations, \$65.

Motor Control and Learning. Mark Latash, ed. Springer; 2006, 170 pages, 100 illustrations, \$29.

Polyomaviruses and Human Diseases. Nasimul Ahsan, ed. Springer; 2006, 387 pages, 79 illustrations, \$169.