



Discover Generics

Cost-Effective CT & MRI Contrast Agents



FRESENIUS
KABI

WATCH VIDEO

AJNR

Imaging in Treatment Planning for Sinonasal Diseases

AJNR Am J Neuroradiol 2006, 27 (7) 1598-1599
<http://www.ajnr.org/content/27/7/1598>

This information is current as
of June 26, 2025.

Imaging in Treatment Planning for Sinonasal Diseases

R. Maroldi and P. Nicolai, eds. Berlin: Springer-Verlag: 2005. 304 pages, 620 illustrations, \$129.

He felt about books as doctors feel about medicines, or managers about plays - cynical, but hopeful."—*Dame Rose Macaulay*

I am always looking for the perfect textbook to add to my collection: a comprehensive radiology text on pathology and how the surgeon, clinician, or radiation oncologist is going to treat it. Of course, if this were possible, then our libraries would not be nearly so crowded. Despite my better judgment, in reviewing *Imaging in Treatment Planning for Sinonasal Diseases*, the latest in the Springer Medical Radiology Diagnostic Imaging series, I was hoping for such a book: a state-of-the-art reference covering all I need to report complex sinonasal tumor cases, inflammatory processes, or "perisinus" pathology affecting the paranasal sinuses. Although this textbook falls short of this goal and is at times an arduous read, it does provide novel information and superb images that make it a welcome addition to the Head and Neck Imaging literature.

The editors, Professors Maroldi and Nicolai, are from the departments of Radiology and Otorhinolaryngology, respectively, at the University of Brescia in Northern Italy (the Radiology department of Antonio Chiesa, MD). This combined radiology-surgery editorial approach to a sinonasal imaging text has many benefits, the most obvious of which is in educating the radiologist as to what the surgeon wants to know and plans to do about a disease process. Keeping the author list (there are 18 additional contributors) within a single academic institution also lends a consistency to management plans. However, it does not necessarily allow for a comprehensive text, and it does not ensure uniformity of writing style, topic emphasis, or attention to detail.

The text is divided into 4 sections: The first 5 chapters cover the basics of imaging techniques, anatomy, physiology, and the key concepts of surgical approaches to the nose and paranasal sinuses. The second section is nearly two thirds of the book and consists of 4 chapters covering the different pathologies from inflammatory sinus disease to benign and malignant neoplasms. Chapter 10 covers pathologies arising from the skull base, sella,

and jaw that might secondarily involve the paranasal sinuses, and the last chapter covers posttreatment findings and complications. The subject matter is notable for the brief treatment of 2 areas: congenital malformations and trauma, which are both mentioned only with reference to the diagnosis of CSF leaks. The authors acknowledge these omissions in the preface, and confess to less exposure to these areas in their

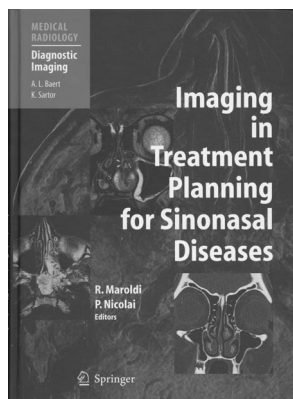
clinical practice. The other, more conspicuous omission is the lack of discussion of the role of fluorodeoxyglucose positron-emission tomography (PET) imaging in neoplastic sinonasal disease. A solitary PET case is presented at the end of the final chapter.

Aside from these omissions, the book's readability is hampered by 2 issues. The first is the multitude of grammatical errors and misuse of English phrases, and the second is the haphazard arrangement of chapters and of topics within chapters. In presenting a book in English written by non-native speakers, the publishers must ensure correct use of English terminology and grammar. There are numerous mishaps throughout the book that significantly interfere with appreciation of the content. A few examples include: "liquid signal intensity" instead of "CSF signal intensity," "primitive tumors" instead of "primary tumors," "trespassing" instead of "invading," and what in the world is "relevant and heterogeneous contrast enhancement"? The most irritating is the frequent use of the word "sinusal" (as in, for example, "sinusal disease"). Although this is the correct adjectival form of the noun "sinus," it is not a term commonly used in English expression and so leads to awkward sentences. Although most readers, I imagine, are happy to let a few aberrant phrases slip by, the descriptions in some figure legends (particularly in chapter 11) are so confusing as to make them almost indecipherable. This devalues the teaching points of otherwise excellent cases.

The second issue with this book is that the core chapters describing different pathologic processes are very unevenly organized. There is an apparently random order in which different pathologies are presented and a disproportionate emphasis on pathologies that are discussed. For example, in chapter 6, the authors devote 5 pages to the different imaging manifestations and types of fungal sinus infection (which, in my practice, is a not-infrequent and sometimes life-threatening problem) but also devote 5 pages to the discussion of sarcoidosis, which they acknowledge rarely involves the paranasal sinuses.

This reviewer suggests, for a future edition, rearranging the chapters and the subjects within them to ensure more even coverage of common or important entities. For example, a discussion of the imaging appearance of perineural tumor spread in chapter 9 would be better incorporated within chapter 4, which discusses the imaging appearance of the skull base and intracranial spread of sinus pathology. In addition, in chapter 9, the discussion of different sinonasal neoplasms should begin with a distinct section on squamous cell carcinoma, the most common malignancy, which is surprisingly located in the earlier discussion of the general imaging features of sinonasal tumors. Chapter 7, CSF leaks, is unsatisfyingly brief and might have been better placed in the chapter on postoperative/posttreatment imaging (chapter 11).

The chapters I most enjoyed reading were those that were *not* primarily about radiology but offered a different perspective on sinonasal disease. Chapter 3, "Physiology of the Nose and Paranasal Sinuses," offers some fabulous facts (did you know that stimulation of nasal mucosa can induce bradycardia?) and an interesting discussion of the different theories on why we have paranasal sinuses at all. Chapter 5, covering surgical techniques, is concisely written and well illustrated with diagrams to explain the surgical rationale and approach to the sinuses, both endoscopically and with open surgical techniques. Although chapter 8, "Benign Neoplasms and Tumor-Like Lesions," is not well organized



and offers incomplete radiology differentials, it features multiple endoscopic color photographs matched with imaging studies in the same patient.

The strength of many radiology textbooks rests on the presence of quality imaging cases, which is the core of this book. The normal anatomy and the garden variety pathologic MR and CT cases are of excellent image quality. In addition, it is gratifying to see many unusual or rare cases beautifully imaged and not merely taken from someone's archival cases. Indeed, it is apparent that the authors have collected a veritable treasure trove of superbly imaged pathology. Chapter 9, "Malignant Neoplasms," distinguishes itself here with excellent common and unusual cases, including an array of exquisite perineural tumor spread cases.

Any radiology text that attempts to better our understanding of sinonasal pathophysiology and the principles and techniques of surgical management of disease is worth adding to the radiologist's library. This book aims to—and accomplishes—those 2 things. In addition, the multitude of common, uncommon, and rare pathologies that are all of excellent image quality makes this text a good investment as a reference. However, I caution that this is not the definitive radiology text for the paranasal sinuses or even a comprehensive review of sinonasal imaging.


BOOK REVIEW

Pediatric CNS Tumors

Nalin Gupta, Anuradha Banerjee, Daphne Haas-Kogan, eds. Berlin: Springer: 2004. 283 pages, 108 illustrations, \$129.

Brain tumors represent the most common solid cancer in children and cause more cancer deaths than any other childhood cancer. Despite these facts, few comprehensive texts are dedicated to the topic of central nervous system tumors in children. This text, edited by the University of California, San Francisco Neuro-Oncology group, long recognized as one of the foremost comprehensive brain tumor centers in the United States, brings together experts in the fields of pediatric neurosurgery, pediatric oncology, and radiation therapy to provide a thoughtful overview. *Pediatric CNS Tumors* represents a welcome addition to the literature and will be an excellent resource for any professional involved in the care of children with cancer.

This text takes on the global topic of CNS tumors of children by dividing the subject matter sensibly by tumor type or location, as appropriate, as well as selected special topics. The chapters that cover tumors by location include supratentorial gliomas, brain stem gliomas, intramedullary spinal cord tumors; those organized by histology include ependymoma, craniopharyngioma, embryonal, neuronal, and choroid plexus tumors. The editors



have thoughtfully divided each of these chapters in an identical fashion, and these subsections are identified in the table of contents for ease of reference. The chapter subsections include epidemiology, pathology, clinical features, imaging, treatment, and outcome. The treatment portion of each chapter is then further divided into surgical indications, techniques, chemotherapy, and radiation therapy. By necessity, these subsections are covered with a concise overview and appropriate references. In addition, there are chapters on imaging, radiation therapy, chemotherapy, surgical techniques, and the phakomatoses.

The chapters are well illustrated with appropriate pathologic micrographs, representative diagnostic images, and informative tables. Figures and tables are accompanied by legends in contrasting colors and a readable font that complements the text. The images are, with a few notable exceptions, of excellent quality.

The shortcomings of this textbook are few. It is, as a survey book, not intended to be the authoritative text on imaging, surgery, chemotherapy, or radiation therapy for pediatric CNS tumors. As a neurosurgeon, I found the sections on surgery thin but concise and a good starting point for a medical student or junior resident. I'm sure that neuroradiologists and medical or radiation oncologists would feel similarly about the material covering their respective disciplines. It was these very sections, which are outside of my specialty, that I enjoyed the most. In addition, it is safe to say this text has a bit of an institutional slant; two thirds of the 28 contributors are from the University of California, San Francisco. Despite these minor drawbacks, I think this textbook will be a well-received addition to the literature that I will enjoy having in my library.

BOOK REVIEW

Neuroimaging Clinics of North America. Stroke I: Overview and Current Clinical Practice

Michael H. Lev, guest editor. Vol. 15, No. 2, May 2005. Philadelphia: WB Saunders. 240 pages, 121 illustrations, \$84.95.

A decade after the approval and availability of thrombolytics for the treatment of acute ischemic stroke, there has been a significant expansion of the discipline of cerebrovascular diseases. Some stroke victims are being treated emergently, stroke centers are being formed, and vascular neurology has been recognized as a certified subspecialty. In neuroradiology, this has translated to a need for emergent imaging, the use of progressively more sophisticated technologies for imaging vessels and tissue at risk, and, significantly, endovascu-

