



Get Clarity On Generics

Cost-Effective CT & MRI Contrast Agents



FRESENIUS
KABI

WATCH VIDEO

AJNR

Subdural Hematomas in Infants with Benign Enlargement of the Subarachnoid Spaces Are Not Pathognomonic for Child Abuse

P.D. McNeely, J.D. Atkinson, G. Saigal, A.M. O'Gorman
and J.-P. Farmer

This information is current as
of August 12, 2025.

AJNR Am J Neuroradiol 2006, 27 (8) 1725-1728
<http://www.ajnr.org/content/27/8/1725>

ORIGINAL
RESEARCH

P.D. McNeely
J.D. Atkinson
G. Saigal
A.M. O’Gorman
J.-P. Farmer

Subdural Hematomas in Infants with Benign Enlargement of the Subarachnoid Spaces Are Not Pathognomonic for Child Abuse

BACKGROUND AND PURPOSE: Patients who have benign enlargement of the subarachnoid spaces (BESS) have long been suspected of having an increased propensity for subdural hematomas either spontaneously or as a result of accidental injury. Subdural hematomas in infants are often equated with nonaccidental trauma (NAT). A better understanding of the clinical and imaging characteristics of subdural hematomas that occur either spontaneously or as a result of accidental trauma may help distinguish this group of patients from those who suffer subdural hematomas as a result of NAT. The purpose of this study is to describe the clinical and imaging characteristics of subdural hematomas that occur either spontaneously or as a result of accidental injury in infants with BESS.

METHODS: We conducted a retrospective review of all patients with BESS complicated by subdural hematomas evaluated at a single institution from 1998 to 2004. Data concerning the patient’s clinical presentation, physical findings, imaging, and management are described.

RESULTS: During the study period, 7 patients with BESS complicated by subdural hematoma were identified. Their mean age at identification of the subdural hematoma was 7.4 months of age. In 5 cases, there was no recognized trauma before identification of the subdural hematoma. In 3 cases, baseline CT or MR imaging was available, showing prominent subarachnoid spaces without any evidence of subdural hemorrhage.

CONCLUSION: Although suspicious for NAT, subdural hematomas can occur in children either spontaneously or as a result of accidental trauma. Caution must be exercised when investigating for NAT based on the sole presence of subdural hematomas, especially in children who are otherwise well and who have BESS.

Benign enlargement of the subarachnoid spaces (BESS) is frequently found on imaging in otherwise normal infants.^{1,2} These patients are often macrocephalic,¹ though this is not a prerequisite for the diagnosis.³ Generally, this condition is self-limiting and requires no specific intervention. BESS has also been referred to in the literature as external hydrocephalus, extraventricular obstructive hydrocephalus, benign extra-axial collections of infancy, and benign subdural effusions of infancy.³ It has long been suspected that the presence of BESS increases the risk of subdural hematoma from minor, accidental head injury, and some studies have showed the same.³⁻⁹ Conversely, it is widely held that the presence of a subdural hematoma in an infant is suspicious for nonaccidental trauma (NAT), particularly when hemorrhage is found in the parafalcine region and also when hemorrhage of different ages is found on imaging studies.¹⁰⁻¹⁴

Although BESS in infants is suspected to predispose to subdural hematomas, this relationship has never been clearly proved. A better understanding of the clinical and imaging characteristics of subdural hematomas that occur either spontaneously or as result of accidental trauma in patients who have BESS may help distinguish this group of patients from those who suffer subdural hematomas from NAT. The purpose of this study is to describe the clinical and imaging char-

acteristics of subdural hematomas in patients with BESS. NAT was ruled out in every case.

Methods

We performed a retrospective review of patients younger than 18 months of age evaluated at the Montreal Children’s Hospital between 1998 and 2004 who were found to have BESS and concomitant subdural hemorrhage on imaging studies. Sonography studies of the subarachnoid space in infants have found that the 95th percentile for the craniocortical width on coronal images at the level of the foramen of Monro is 4 mm.¹⁵ For the purpose of this study, BESS was defined as a minimum distance of 5 mm between the surface of the brain and the inner table of the skull. Patients who were found to have suffered NAT were excluded. Patients with an underlying bleeding diathesis were also excluded. Data were collected concerning the patient’s age at diagnosis of subdural hematoma, sex, presenting symptoms and physical findings, and results of imaging. Information was also recorded concerning the type of trauma sustained (if known), the patient’s clinical course, and treatment. A comprehensive review of the history in each case and an extensive investigation and interview process was done in each case by the hospital’s child abuse services team to rule out the possibility of NAT. Fundus examination was also performed in every case as a part of NAT work-up. Except for case 7 (who had suffered extensive trauma), none of the patients showed retinal hemorrhages.

Results

During the study period, 7 children (5 of whom were boys) with BESS complicated by subdural hemorrhage were identified. The patients ranged from 3.6 to 17.8 months of age. Accidental trauma could be identified in 2 of these cases: 1 patient was involved in a motor vehicle accident and 1 patient fell from his own height resulting in a nondisplaced linear fracture

Received April 21, 2005; accepted after revision December 20.

From the Division of Neurosurgery, Department of Surgery (P.D.M.), IWK Health Centre, Dalhousie University, Halifax, Nova Scotia, Canada; and Division of Neurosurgery, Department of Surgery (J.D.A., J.-P.F.), and the Department of Radiology (G.S., A.M.O.), Montreal Children’s Hospital, McGill University, Montreal, Quebec, Canada.

Address correspondence to P. Daniel McNeely, MD, FRCSC, Division of Neurosurgery, IWK Health Centre, 5850 University Ave, P.O. Box 9700, Halifax, NS, B3K 6R8 Canada; e-mail: dmcneely@dal.ca

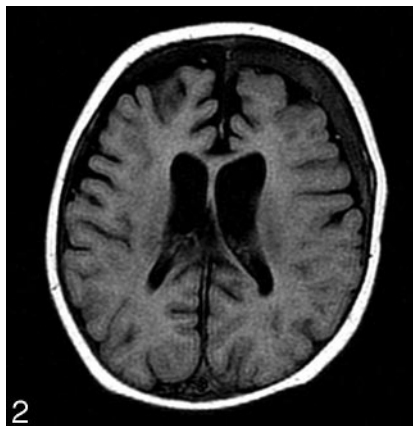
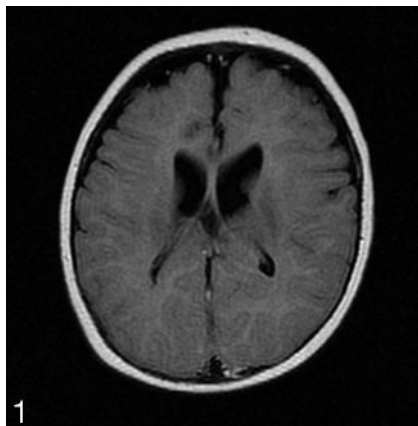


Fig 1. Axial fluid-attenuated inversion recovery MR image showing prominent CSF equivalent subarachnoid spaces in both frontal regions. No subdural hemorrhage is noted.

Fig 2. Axial fluid-attenuated inversion recovery MR of same patient as in Fig 1 done 19 days later (patient remained hospitalized) now showing an isointense area in the left subdural space, consistent with a hematoma. The subarachnoid CSF space is seen clearly separate from the overlying subdural space containing the hematoma.

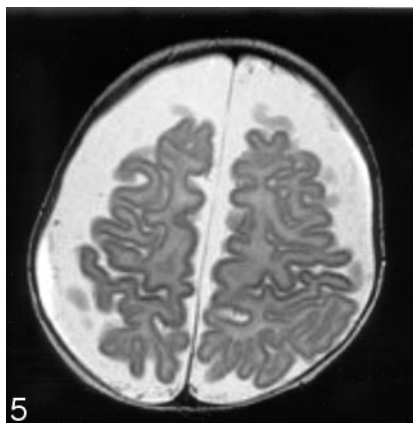
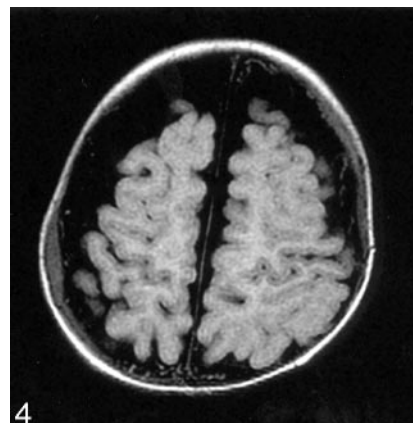
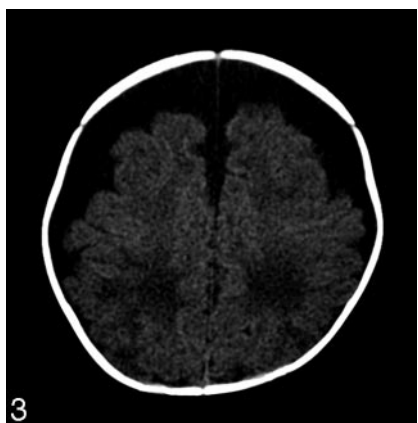

Fig 3. Axial CT scan showing prominent subarachnoid spaces in both frontal regions.

Fig 4. Axial fluid-attenuated inversion recovery MR sequence showing thin bilateral subdural hematomas that are seen separate from the underlying subarachnoid space.

Fig 5. Axial T2-weighted MR image also showing the thin bilateral subdural hematomas.

of the right parietal bone. In 3 cases, baseline imaging in the form of either a CT or MR imaging scan was available, showing prominent pericerebral fluid spaces but no subdural hemorrhage. Macrocephaly was present in 3 of the 7 cases. Surgical procedures were performed in 3 of the 7 cases. One of the patients who developed a subdural hematoma as a result of a motor vehicle crash has experienced seizures that have been easily controlled with anticonvulsant medications. The details of the clinical presentation, radiologic investigations, treatment, and follow-up for all 7 cases can be found in Table 1.

Illustrative Cases

Case 1. This female patient was admitted to our hospital at 5 months of age with a 3-day history of fever and symptoms of upper respiratory tract infection. She was previously well. On the day of admission, she presented with seizures, lethargy, and decreased level of consciousness. She was investigated extensively; as a part of her work-up, MR imaging was performed. The initial MR imaging (Fig 1) showed hypoplasia of the corpus callosum and prominent subarachnoid spaces without any evidence of subdural hemorrhage. Over the course of her hospitalization, she developed diabetes insipidus. A repeat MR imaging with focused pituitary imaging was requested to elucidate the cause of the diabetes insipidus. This follow-up MR imaging (Fig 2), done 19 days later (while she was still hospitalized), showed an ectopic posterior pituitary as

well as a new left frontal subdural hematoma measuring 8 mm in maximal thickness. She appeared to be asymptomatic as far as the subdural hematoma was concerned, and it was decided to follow this with serial imaging. The ophthalmologic examination was normal and demonstrated no retinal hemorrhages. The child abuse services team excluded any remote possibility of NAT either at home or in the hospital. She was finally discharged 1 month after her admission. A follow-up CT scan was done 1 week later and showed no progression of the subdural collections. She has remained asymptomatic as far as the subdural hematoma is concerned.

Case 2. This patient was born at gestational week 29 and suffered from meconium peritonitis as well as respiratory distress syndrome in early life. He was being followed with serial cranial ultrasonography because he had been found to have increased extra-axial fluid, without evidence of intraventricular hemorrhage. Progression on follow-up sonography with an increasing head circumference prompted a neurosurgical referral at 3 months of age. At this time, his head circumference was 42 cm (greater than the 98th percentile for this age when corrected for his prematurity). He was developing normally for his corrected age and had no health problems at the time of his initial consultation. CT of the head showed an excess of CSF over the convexity of the cerebral hemispheres but did not suggest the presence of any hemorrhagic products (Fig 3). MR imaging done 3 weeks later showed that there was hemorrhage in the subdural compart-

Clinical and imaging characteristics of patients*					
Patient	Age at Diagnosis of Subdural Hematoma (mo)/Sex	Head Circumference at Subdural Hematoma Diagnosis (cm)	Presenting Signs and Symptoms	Imaging Findings	Treatment
1	8.5/M	47.5 (normal)	Bulging fontanelle, nausea, and lethargy	4-mm-thick right acute SDH	Observation alone
2	3.9/M	44 (macrocephalic)	Macrocephalic but otherwise asymptomatic; HC >98th percentile corrected for age; normal fundi; developmentally normal	Thin SDH present bilaterally measuring 5 mm thick	Observation alone
3	4.7/F	45.8 (macrocephalic)	Macrocephalic, bulging fontanelle; irritable, spasticity	Bilateral 18-mm-thick chronic SDHs	1. Bilateral subdural–peritoneal shunts 2. Bifrontal craniotomy
4	17.8/M	50 (normal)	Fall from own height causing linear right parietal skull fracture and bilateral SDHs; returned 6 weeks later with irritability and bulging fontanelle	Bilateral subacute SDHs measuring 10 mm on right and 9 mm on left, and right parietal linear nondisplaced skull fracture	1. Burrhole drainage 6 weeks following trauma 2. Required bilateral subdural peritoneal shunts 12 weeks after the trauma
5	3.6/M	45.9 (macrocephalic)	Macrocephalic but otherwise asymptomatic; fundus normal	Prominent pericerebral fluid spaces noted on referral for evaluation of macrocephaly; MRI 1 week later showed thin bilateral subdural hemorrhage with membranes (11 mm on right and 18 mm on left)	1. Bilateral burrhole drainage 19 days following referral 2. Left subdural peritoneal shunt inserted 1 week later
6	6.3/F	Not recorded	Fever and upper respiratory tract infection symptoms, lethargy, and spasticity	Initial MRI showed prominent SAS; second MRI done during hospitalization showed an 8-mm left subdural hematoma	Observation alone
7	7/M	45.5	Motor vehicle crash—Patient was in a proper car seat, not ejected; Presented with decreased level of consciousness, vomiting, and respiratory pauses, and was therefore intubated and admitted to an intensive care unit. Found to have retinal and preretinal hemorrhages on fundoscopy	Initial CT showed an 11-mm-thick left acute SDH with a 4-mm midline shift and pericerebral fluid collections. MRI done in the days that followed was interpreted as showing SDHs of various ages in multiple compartments including the perifalcine region	No surgical intervention for the subdural hematoma; developed seizures that were treated with carbamazepine

HC indicates head circumference; SDH, subdural hematoma; SAS, subarachnoid space.

* Patients younger than 18 months of age evaluated at Montreal Children's Hospital between 1998 and 2004 who were found to have BESS and a concomitant subdural hematoma on imaging. NAT was ruled out in every case.

ment bilaterally measuring 5 mm in maximal diameter (Figs 4 and 5). The fundus examination was normal. Coagulation profile, including blood platelet level and prothrombin time (PT) and partial thromboplastin time (PTT), was normal. Repeat MR imaging at 11 months of age showed the persistence of very large subarachnoid spaces, without the presence of hemorrhage in the subdural space. His head circumference has remained above the 98th percentile. The patient has remained clinically and develop-

mentally well without surgical intervention at the age of 14 months.

Discussion

In the past, many studies have stated that child abuse is the cause of subdural hematomas in most children younger than 2 years. In 1946, Caffey¹⁶ reported 6 patients who suffered a combination of subdural hematomas and long-bone fractures

as a result of NAT. Since this early description, the association between subdural hematoma and NAT has been made in several publications.^{9,12,14,17-21} In the patients with child abuse, the prognosis has been shown to be usually poor with a high incidence of deaths and neurologic sequelae.

It is increasingly being recognized, however, that retinal hemorrhages and subdural hematomas in infants are not exclusively caused by NAT.²²⁻²⁵ Recently, a few reports have demonstrated the presence of subdural hematomas in patients with BESS.⁴⁻⁸ The subdural hematomas are asymptomatic and are incidentally detected on imaging studies. Azais et al,⁴ in their study of 41 patients with BESS, showed that 3 of the children had incidental findings of subdural hematomas. Two of the infants had mild hypotonia initially, but all of them had normal neurologic examination and development during follow-up. Similarly, Ravid and Maytal⁸ reported incidental subdural hematomas in 3 children with BESS. In 2 of these children, the hematoma completely resolved, and the infants remained neurologically intact and demonstrated normal developmental milestones in a 1-year follow-up. The third patient was completely asymptomatic but was sent for a neurosurgical consultation and underwent drainage of the collection. No adverse neurologic sequela was seen in this patient.

It is suspected that patients with BESS have an increased susceptibility for the development of subdural hematomas.^{4-8,24} The current hypothesis is that stretching of the bridging veins in the subdural space due to enlargement of the CSF spaces may result in a predisposition to developing subdural hematomas. In fact, Papasian and Frim,⁶ in a mathematic model of the cranial vault, showed a relationship between venous stretching and the width of the extra-axial spaces, thereby concluding that very minor degrees of trauma could predispose patients with BESS to developing subdural hemorrhages.

Extra-axial blood collections could be in the subarachnoid or the subdural space. Imaging studies (such as MR imaging) have been shown to be able to differentiate between subdural hematomas and BESS.²⁶ Color Doppler helps to identify the cortical veins within the subarachnoid space and has also been shown to be similarly useful to differentiate between BESS and subdural collections.²⁷

In our study, we report 7 patients with underlying BESS younger than 18 months who were found to have subdural hematomas that occurred either spontaneously or as a result of accidental trauma. In 3 of these patients, baseline CT or MR imaging studies were available demonstrating the presence of BESS without subdural hemorrhage. In the remaining 4 patients, enlarged CSF spaces were identified concurrently with the subdural hematoma. These patients suffered no recognized trauma, had no coagulation anomaly, and were not the victims of abuse. The pattern of subdural hemorrhage on imaging mimicked the presence of chronic subdural hematomas sometimes seen as a result of NAT. There were no associated intraparenchymal imaging changes, such as contusions, contrary to what is occasionally seen in cases of inflicted trauma. Surgical evacuation was deemed necessary by the treating surgeon in 3 cases.

The patients in our study had a generally benign clinical course, which contrasts markedly with series in which inflicted trauma was the cause of an infant's subdural hematoma.^{11,13,14} A high incidence of mortality and neurologic morbidity is generally reported in young patients who suffer subdural hematoma as a result of NAT.

Conclusion

Based on our observations, we believe that subdural hematomas may occur either spontaneously or as result of a minor or unrecognized trauma in patients with BESS. Physicians should maintain an awareness of potential child maltreatment when evaluating young patients who are victims of trauma. Care should be exercised, however, when evaluating patients who have BESS who are found to have an isolated subdural hematoma. When other stigmata of NAT are absent, a subdural hematoma in isolation cannot be used as presumptive evidence of NAT.

References

- Hamza M, Bodensteiner JB, Noorani PA, et al. **Benign extracerebral fluid collections: a cause of macrocrania in infancy.** *Pediatr Neurol* 1987;3:218-21
- Robertson WC Jr, Chun RW, Orrison WW, et al. **Benign subdural collections of infancy.** *J Pediatr* 1979;94:382-86
- Barkovich AJ. *Pediatric Neuroimaging*, 3rd ed. New York: Lippincott Williams & Wilkins; 2000.
- Azais A, Echenne B. **Idiopathic subarachnoid space enlargement (benign external hydrocephalus) in infants.** *Ann Pediatr* 1992;39:550-58
- Pittman T. **Significance of a subdural hematoma in a child with external hydrocephalus.** *Pediatr Neurosurg* 2003;39:57-59
- Papasian NC, Frim DM. **A theoretical model of benign external hydrocephalus that predicts a predisposition towards extra-axial hemorrhage after minor head trauma.** *Pediatr Neurosurg* 2000;33:188-93
- Mori K, Sakamoto T, Nishimura K, et al. **Subarachnoid fluid collection in infants complicated by subdural hematoma.** *Childs Nerv Syst* 1993;9:282-84
- Ravid S, Maytal J. **External hydrocephalus: a probable cause for subdural hematoma in infancy.** *Pediatr Neurol* 2003;28:139-41
- Kleinman PK. *Diagnostic Imaging of Child Abuse*. 2nd ed. Toronto: Mosby; 1998.
- Tzioumi D, Oates RK. **Subdural hematomas in children under 2 years. Accidental or inflicted? A 10-year experience.** *Child Abuse Negl* 1998;22:1105-12
- Duhaime AC, Alario AJ, Lewander WJ, et al. **Head injury in very young children: mechanisms, injury types, and ophthalmologic findings in 100 hospitalized patients younger than 2 years of age.** *Pediatrics* 1992;90:179-85
- Billmire ME, Myers PA. **Serious head injury in infants: accident or abuse?** *Pediatrics* 1985;75:340-42
- Hoskote A, Richards P, Anslow P, et al. **Subdural haematoma and non-accidental head injury in children.** *Childs Nerv Syst* 2002;18:311-17
- Jayawant S, Rawlinson A, Gibbon F, et al. **Subdural haemorrhages in infants: population based study.** *BMJ* 1998;317:1558-61
- Libicher M, Troger J. **US measurement of the subarachnoid space in infants: normal values.** *Radiology* 1992;184: 749-51
- Caffey J. **Multiple fractures in the long bones of infants suffering from subdural hematoma.** *Am J Roentgenol* 1946;56:163-73
- Caffey J. **On the theory and practice of shaking infants. Its potential residual effects of permanent brain damage and mental retardation.** *Am J Dis Child* 1972;124:161-69
- Caffey J. **The whiplash shaken infant syndrome: manual shaking by the extremities with whiplash-induced intracranial and intraocular bleedings, linked with residual permanent brain damage and mental retardation.** *Pediatrics* 1974;54:396-403
- Hadley MN, Sonntag VK, Rekeate HL, et al. **The infant whiplash-shake injury syndrome: a clinical and pathological study.** *Neurosurgery* 1989;24:536-40
- Kempe CH, Silverman FN, Steele BF, et al. **The battered-child syndrome.** *JAMA* 1962;181:17-24
- Duhaime AC, Christian CW, Rorke LB, et al. **Nonaccidental head injury in infants—the “shaken-baby syndrome.”** *N Engl J Med* 1998;338:1822-29
- Fung EL, Sung RY, Nelson EA, et al. **Unexplained subdural hematoma in young children: is it always child abuse?** *Pediatr Int* 2002;44:37-42
- Lantz PE, Sinal SH, Stanton CA, et al. **Perimacular retinal folds from childhood head trauma.** *BMJ* 2004;328:754-56
- Piatt JH. **A pitfall in the diagnosis of child abuse: external hydrocephalus, subdural hematoma, and retinal hemorrhages.** *Neurosurg Focus* 1999;7(4) Available at: <http://www.aans.org/education/journal/neurosurgical/oct99/7-4-4.asp>
- Aoki N, Masuzawa H. **Infantile acute subdural hematoma. Clinical analysis of 26 cases.** *J Neurosurg* 1984;61:273-80
- Wilms G, Vanderschueren G, Demaerel PH, et al. **CT and MR in infants with pericerebral collections and macrocephaly: benign enlargement of the subarachnoid spaces versus subdural collections.** *AJNR Am J Neuroradiol* 1993;14:855-60
- Chen CY, Chou TY, Zimmerman RA, et al. **Pericerebral fluid collection: differentiation of enlarged subarachnoid spaces from subdural collections with color Doppler US.** *Radiology* 1996;201:389-92