



## Get Clarity On Generics

Cost-Effective CT & MRI Contrast Agents



FRESENIUS  
KABI

WATCH VIDEO

# AJNR

## Lingual Hamartoma in an Infant: CT and MR Imaging

A.L. Goold, B.L. Koch and J.P. Willging

*AJNR Am J Neuroradiol* 2007, 28 (1) 30-31

<http://www.ajnr.org/content/28/1/30>

This information is current as  
of August 5, 2025.

## CASE REPORT

A.L. Goold  
B.L. Koch  
J.P. Willging

# Lingual Hamartoma in an Infant: CT and MR Imaging

**SUMMARY:** Lingual hamartoma is a rare tongue mass, primarily diagnosed in childhood. In most cases in the literature, the masses were surgically removed without preoperative imaging. There are only 3 cases reported in the clinical literature that describe preoperative imaging findings. We report the clinical and imaging findings in an infant with lingual hamartoma and review the literature.

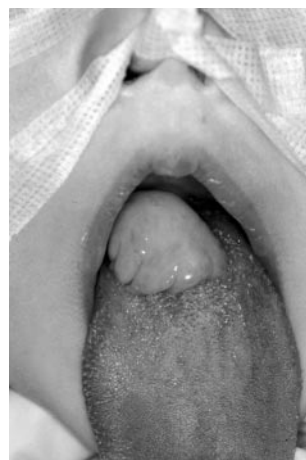**L**ingual hamartoma is a rare benign tumorlike malformation of the tongue composed of tissue indigenous to the area in which it is found, but abnormally arranged. These malformations may occur as isolated lesions or in association with syndromes such as oral-facial-digital syndrome. Although one might expect that they would occur in Cowden syndrome (multiple hamartoma syndrome), the classic lesion of the tongue in these patients is a scrotal tongue rather than a focal lingual hamartoma.<sup>1</sup> In the clinical literature, the imaging characteristics (in 2 children and 1 adult) have been reported as hypointense on T1-weighted images, hyperintense on T2-weighted images, and intermediate attenuation on CT. We report the clinical, CT, and MR imaging findings in an infant with an asymptomatic lingual hamartoma.

## Case Report

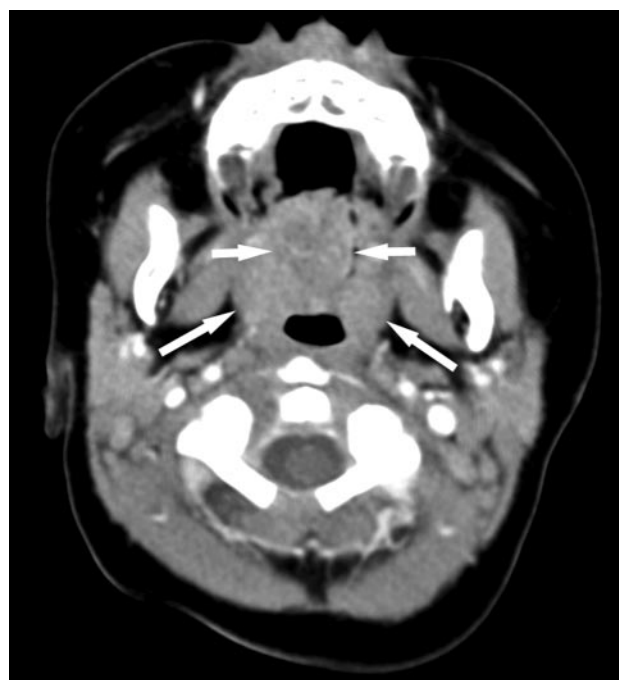
A 5-month-old male infant presented with a posterior tongue mass visible initially by his mother, only when he laughed with his mouth wide open (Fig 1). Subsequent evaluation by the otolaryngologist demonstrated a smooth yellowish mass arising near the foramen cecum, thought to be potentially a lingual thyroid. The mass did not interfere with deglutition or respiration. The family history was unremarkable and the child was otherwise healthy.

Imaging was requested to characterize the lesion better, evaluate the extent of deep tongue involvement, and aid in preoperative planning to determine whether surgery would be via an intraoral approach or an open procedure through the neck. CT scans revealed a round intermediate-attenuation soft-tissue mass arising from the midline posterior tongue. There was only minimal heterogeneous contrast enhancement (Fig 2). A homogeneously enhancing bilobed normal-appearing thyroid gland was present in the lower neck (image not shown). MR imaging showed a well-defined mass at the surface of the posterior tongue, mildly hypointense on T1-weighted images and having mixed signal intensity on T2-weighted images, with a hyperintense irregular center and a hypointense periphery (Fig 3).

At surgery, the smooth and slightly lobulated mass measured  $2.3 \times 2 \times 1.2$  cm and arose near the foramen cecum. It was noted to have a short 5-mm-thick stalk, which was amputated by using elec-



**Fig 1.** Preoperative photograph of the infant in the operating room after anesthesia induction and nasotracheal intubation, with manual traction applied to the patient's tongue, shows a lobulated midline tongue base mass.



**Fig 2.** Axial postcontrast CT scan shows a lobulated soft-tissue midline posterior tongue mass with minimal heterogeneous enhancement (short arrows). On this axial image, the mass is at the same level as the normal-appearing palatine tonsils (long arrows).

trocautery. Surrounding mucosa and a thin layer of tongue musculature were removed without complication. Histology confirmed a hamartoma composed mainly of smooth muscle with components of squamous epithelium and mucous glands.

## Discussion

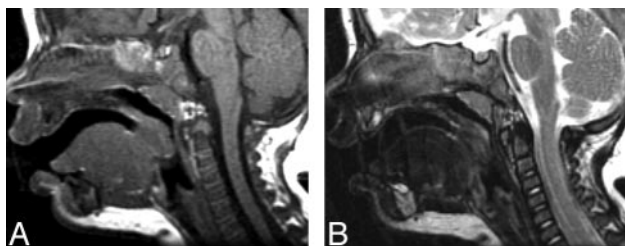
Hamartoma is a benign tumorlike overgrowth in which normal tissue components of the organ of origin are abnormally

Received December 7, 2005; accepted after revision December 22.

From Eastern Virginia Medical School (A.L.G.), Norfolk, Va; and Cincinnati Children's Hospital Medical Center (B.L.K., J.P.W.), Cincinnati, Ohio.

Paper previously presented at: Annual Meeting of the American Society of Head and Neck Radiology, October 1–4, 2003; Rancho Mirage, Calif.

Please address correspondence to: Bernadette L. Koch, MD, Department of Radiology, Cincinnati Children's Hospital Medical Center, 3333 Burnet Ave, Cincinnati, OH 45229; e-mail: koch.bl@cchmc.org



**Fig 3.** A, Sagittal T1-weighted image demonstrates a mildly hypointense well-defined mass arising from the posterior aspect of the tongue abutting the inferior surface of the uvula. B, T2-weighted image demonstrates a central area of hyperintensity with irregular margins and hypointense periphery.

arranged, most commonly located in the liver, spleen, kidney, lung, skin, and pancreas. Lingual hamartoma was first described in 1945 by Stamm and Tauber<sup>2</sup> and may occur in isolation or in association with syndromes such as oral-facial-digital syndrome (originally described by Gorlin and Psaume as orodigitofacial dysostosis).<sup>3</sup> Lingual hamartomas presenting as an isolated anomaly are extremely rare, with only 15 previously reported patients, 13 of whom were children.<sup>2,4-16</sup> Isolated lingual hamartomas occur as solitary lesions on the dorsum of the tongue, usually posterior and midline in the area of the foramen cecum. Most lingual hamartomas are polypoid and more common in females, with a female-to-male ratio of almost 2:1. Multiple hamartomas in the tongue have been reported, but such occurrence has been limited to an association with other syndromes, such as oral-facial-digital syndrome,<sup>17</sup> incomplete cleft palate,<sup>18</sup> and tuberous sclerosis.<sup>15</sup> Cowden syndrome (multiple hamartoma syndrome) is known to feature multiple hamartomas throughout the body, including the mucous membrane of the oral cavity. However, the classic lesion of the tongue in Cowden syndrome is a scrotal tongue, not a lingual hamartoma.<sup>1</sup>

Differential diagnosis of congenital tongue lesions in children includes lingual thyroid, thyroglossal duct cyst, vascular malformation, and duplication cyst. Pediatric tongue neoplasms include teratoma and sarcoma.<sup>19</sup> Of these lesions, lingual thyroid and thyroglossal duct cyst (TGDC) occur in the region of the foramen cecum, as do lingual hamartomas. The lesion in this report was not cystic on imaging or clinical appearance; therefore, TGDC and duplication cyst were unlikely possibilities. The presence of a normal-appearing thyroid in the lower neck did not exclude lingual thyroid. However, the lesion in this report was not as hyperattenuated on CT as lingual thyroid usually is. The lesion did not contain fat or calcium, which would have increased the likelihood of a diagnosis of teratoma.

To our knowledge, imaging findings are discussed in only 3 clinical reports in the English literature.<sup>5,6,15</sup> Halfpenny et al<sup>5</sup> reported a 4-year-old girl with a left posterior tongue mass,

with MR imaging showing a predominately cystic nonenhancing lesion, hypointense on T1-weighted images and hyperintense T2-weighted images. Takimoto et al<sup>6</sup> reported a 6-year-old girl with a left-of-midline posterior tongue mass, hyperintense on T1-weighted images and moderately hyperintense on T2-weighted images. Wallace et al<sup>15</sup> reported a 41-year-old woman with tuberous sclerosis and a large base-of-tongue mass, intermediate in attenuation on postcontrast CT. In our patient, the lesion was mildly hypointense on T1-weighted images and heterogeneous on T2-weighted images, with only minimal postcontrast enhancement on CT.

## Conclusion

Lingual hamartoma is a rare cause of tongue base mass, with only 15 previously reported cases occurring without associated syndromes. To our knowledge, there are only 3 reports in the clinical literature that describe the imaging findings of lingual hamartomas. Imaging features are nonspecific. However, the differential diagnosis of a posterior midline tongue mass, in the region of the foramen cecum in a child, should include lingual hamartoma.

## References

1. Lloyd KM 2nd, Dennis M. Cowden's disease: a possible new symptom complex with multiple system involvement. *Ann Intern Med* 1963;58:136-42
2. Stamm C, Tauber R. Hamartoma of tongue. *Laryngoscope* 1945;140-46
3. Gorlin RJ, Psaume J. Orodigitofacial dysostosis: a new syndrome—a study of 22 cases. *J Pediatr* 1962;61:520-30
4. Owen G, Berry J, Bicknell P. Hamartoma of the tongue. *J Laryngol Otol* 1993; 107:363-67
5. Halfpenny W, Odell EW, Robinson PD. Cystic and glial mixed hamartoma of the tongue. *J Oral Pathol Med* 2001;30:368-71
6. Takimoto T, Yoshizaki T, Umeda R. Hamartoma of the tongue. *Int J Pediatr Otorhinolaryngol* 1989;18:157-61
7. Herzog S, Bressman J, Giglio JA. Case 61: tongue mass in an infant. *J Oral Maxillofac Surg* 1986;44:463-66
8. Takato T, Fukuda O, Ohhara Y, et al. Hamartoma of the tongue: two case reports. *Plast Reconstr Surg* 1985;75:258-62
9. Cutchavaree A, Rungruxsivorn S, Suphanakorn S. Hamartoma of the tongue. *J Med Assoc Thai* 1985;68:216-19
10. Becker GD, Ridolfi R, Ingber C. Lingual hamartoma in a newborn. *Otolaryngol Head Neck Surg* 1984;92:357-59
11. Kobayashi A, Amagasa T, Okada N. Leiomyomatous hamartoma of the tongue: case report. *J Oral Maxillofac Surg* 2001;59:337-40
12. Horn C, Thaker HM, Tampakopoulou DA, et al. Tongue lesions in the pediatric population. *Otolaryngol Head Neck Surg* 2001;124:164-69
13. Goldsmith P, Soames JV, Meikle D. Leiomyomatous hamartoma of the posterior tongue: a case report. *J Laryngol Otol* 1995;109:1190-91
14. Hinshaw CT Jr. Unusual lesions of the tongue: hamartoma. *J Kans Med Soc* 1963;64:154-57
15. Wallace H, Davis A, Spedding A. Tongue-base hamartoma in tuberous sclerosis. *J Laryngol Otol* 2001;115:149-50
16. Perri FA. Myoepithelial hamartoma of tongue. *AMA Arch Otolaryngol* 1956;64: 289-90
17. Doege TC, Thuline HC, Priest JH, et al. Studies of a family with the oral-facial-digital syndrome. *N Engl J Med* 1964;271:1073-78
18. Ishii T, Takemori S, Suzuki JL. Hamartoma of the tongue. *Arch Otolaryngol* 1968;88:79-81
19. Donnelly LF, Jones BV, Strife JL. Imaging of pediatric tongue abnormalities. *AJR Am J Roentgenol* 2000;175:489-93