



## Get Clarity On Generics

Cost-Effective CT & MRI Contrast Agents



FRESENIUS  
KABI

WATCH VIDEO

# AJNR

## PocketRadiologist-PedsNeuro: Top 100 Diagnoses

*AJNR Am J Neuroradiol* 2007, 28 (2) 395-396  
<http://www.ajnr.org/content/28/2/395>

This information is current as  
of August 11, 2025.

in other chapters of this book often is accompanied by correlative intraoperative photographs and/or histopathologic material. In fairness however, this radiology chapter was probably intended to be just a very short survey, which it is.

What specific material would be of value and unfamiliar to the neuroradiologist? The chapter on the “Pathology of Tumors of the Spine” by Dr. Coons from the Barrow Neurologic Institute is a key component of the book. In its 70 pages, the material covers nervous system tumors (central, peripheral, and meningeal), vertebral tumors, and soft-tissue tumors. There are many features of special interest to the neuroradiologist, including immunohistochemistry stains and the significance of their reactivity; the WHO grading for tumors; the varieties of meningiomas; a clear explanation and demonstration of the differentiation of Schwannomas from neurofibromas, neuroblastic tumors, and various germ cell tumors; and the pathology of vertebral column tumors. Of particular interest to this reviewer is a frank discussion of the issues surrounding the often contentious debate (and aired a number of years ago in the *AJNR*) concerning the diagnosis of gangliogliomas of the spinal cord. Widely discrepant numbers in the frequency of gangliogliomas versus pilocytic astrocytomas exist, and after reading this section, one begins to have an inkling of why this debate occurs and why some believe ganglion cell tumors are more common than generally acknowledged, whereas others question the validity of this diagnosis. That particular issue is highlighted in this review because it serves as an example of the straightforward manner in which this chapter is written. One gains insights as to why the statistics concerning the incidence of different tumor types vary so greatly from study to study and why the terminology for tumors is variable or seems to be a moving target. Readers not familiar with the details of histopathology of these tumors may believe that the standard specimens are underlabeled and not as fully described in the legends as they should have been; that would be a valid criticism for an otherwise excellent chapter. The 149 color plates of the pathology do, however, give one the opportunity of viewing a wide variety of spine tumors. The following chapter on “Cellular and Molecular Biology of the Central Nervous System and Peripheral Nervous System Neoplasms” complements the pathology chapter by reviewing the genetics, growth factors, and cell cycles involved in these tumors.

Therapy for spinal tumors is reviewed in short chapters on systemic and intrathecal chemotherapy, embolization techniques, and radiation therapy (external radiation, brachytherapy, stereotactic radiation, and Cyberknife). These sections would hold only minimal interest for the neuroradiologist—the chapter on the embolization is too short to be of great value to anyone actually doing endovascular surgery of the spine.

There is considerable redundancy in this book because different authors go about illustrating and discussing many of the same issues and cases. Cross referencing would have been of

value. For example, when osteoid osteomas in chapter 2 were described, the appropriate image in chapter 5 could have been cited. Perhaps that type of problem is inevitable in a multiauthored text, but tighter editing with an effort to combine material would have made a shorter and equally valuable publication.

On the other hand, there are topics in the latter one third of the book about which the radiologist rarely reads but encounters indirectly through imaging. These include treatment decisions, techniques of spine reconstruction/fixation, and surgical approaches to all of these tumors. Operative approaches to the craniovertebral junction, the cervical spine, the cervicothoracic junction, the transthoracic/transabdominal approach to the spine, thoracoscopic surgery, along with other anterior and lateral approaches to the spine are described. These chapters contain vivid drawings, intraoperative photographs, and postoperative imaging, so the radiologist is able to gain a full perspective of the challenges and surgical issues involved. Many of the instrumented constructs radiologists encounter on a daily basis are dealt with in an interesting and well-illustrated manner. These are, incidentally, topics infrequently covered in the radiology literature, so the information in this book becomes even more valuable. A short chapter on percutaneous vertebroplasty and kyphoplasty summarizes the current status, techniques, and complications of these procedures for benign and malignant tumors.

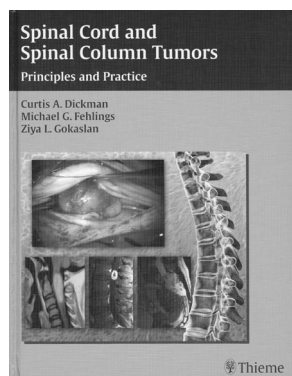
Overall the imaging is properly described throughout the book; relatively few and minor problems crop up, such as inaccurately described images or showing an image and describing the findings but never stating the diagnosis or the surgical outcome. As indicated previously, however, the value of this publication lies in areas outside imaging itself. In summary, this book would be a valuable addition to the library of a department in which there are a large number of referrals from spine surgeons because it allows the radiologist to appreciate the many problems and issues that confront our surgical colleagues.

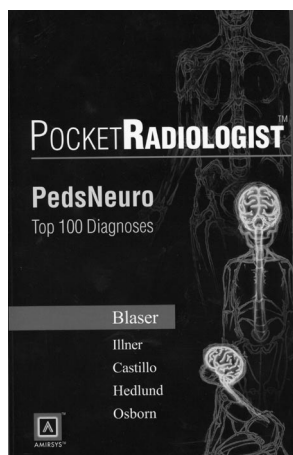
## BOOK REVIEW

### PocketRadiologist-PedsNeuro: Top 100 Diagnoses

Susan I. Blaser, Anna Illner, Mauricio Castillo, Gary L. Hedlund, Anne G. Osborn, eds. Salt Lake City: Amirsys; 2003, 330 pages, 200 drawings and radiographic images, paperback \$64.95.

Another in the *PocketRadiologist* series, this one edited by Drs. Blaser, Illner, Castillo, Hedlund, and Osborn, is *PedsNeuro*. It follows the same format as the other publications in the series (reviewed in the *AJNR Am J Neuroradiol* 2005;26:436; *AJNR Am J Neuroradiol* 2003;24:770). A compilation of 100 cases, designated by the editors as the “top diagnoses” are demonstrated with pertinent imaging, followed by a series of bulleted points under the headings of “Key Facts,” “Imaging Findings,” “Differential Diagnosis,” “Pathology,” “Clinical Issues,” and “Selected References.” Major diagnoses are included in the following disease categories: congenital, neu-





rocutaneous, infection, inflammation, vascular, ischemic, metabolic/toxic, metabolic/inherited, neoplastic, trauma, and CSF spaces. Although some of the entities have been covered in the other books in the neuroimaging set, this particular 330-page soft-cover publication nicely complements the entire series. Once again (and as we now are accustomed to seeing in these books), the images are of high quality and appear to be of re-

cent vintage. I counted 32 beautiful color drawings (not to be greedy, but this reviewer wished there could have been close to 1 such drawing for each of the diagnoses, but the metabolic disorders, for example, did not lend themselves well to an artist's rendition). I believe the drawings will stick in the reader's mind better than the MR images themselves—that is not a disadvantage but rather a testimony to the value of the drawings.

The title of this book belies, to some extent, the contents. By "Top 100 Diagnoses," one would think the 100 most common diagnoses would be the focus of the book. That is not the situation. Maybe these are in the editors' minds the 100 most interesting cases, but they are certainly not the most common. For instance, included here are entities such as the Kallman syndrome, neurocutaneous melanosis, and rhomboencephalosynapsis. For the latter, it is said that only 20 cases have been

reported in the literature, and that places the diagnosis of rhomboencephalosynapsis and others in the collection well beyond inclusion in a common group. Missing are many spine diagnoses that are not as rare, such as cord tumors of various sorts, demyelinating processes, spinal abscesses, and so forth.

All of this is not said to detract from the value of the book but is mentioned so a prospective buyer knows that he or she is getting many zebras mixed in with the more commonly encountered diseases. I particularly like the inclusion of a fair number of pediatric ear, nose, and throat cases, both congenital and acquired, which made the book even more valuable. One area in pediatric neuroradiology that frequently arises is the issue of the pattern, time sequencing, and MR imaging techniques/pulse parameters to use in evaluating the 0- to 18-month-old infant. Although it is understood that such an insertion would not fit easily into a top 100 diagnoses, if the editors plan a new edition, this reviewer would urge a section at the beginning of the book on this topic. With that information in one's pocket, the book would be consulted often in reading sessions.

In summary, this would be a valuable book for anyone involved with a substantial amount of pediatric neuroradiology.

---

## BOOKS RECEIVED

*Molecular Biology and Genomics*. Cornel Mülhardt, ed. Burlington, Mass: Elsevier Academic Press; 2006. 272 pages, 50 line illustrations, \$44.95.