



**Get Clarity On Generics**

Cost-Effective CT & MRI Contrast Agents

**FRESENIUS  
KABI**

**WATCH VIDEO**

**AJNR**

**New Symptomatic Compression Fracture  
after Percutaneous Vertebroplasty at the  
Thoracolumbar Junction**

C.C. Lin, I.H. Chen, T.C. Yu, A. Chen and P.S. Yen

*AJNR Am J Neuroradiol* 2007, 28 (6) 1042-1045

doi: <https://doi.org/10.3174/ajnr.A0520>

<http://www.ajnr.org/content/28/6/1042>

This information is current as  
of August 9, 2025.

ORIGINAL  
RESEARCH

C.C. Lin  
I.H. Chen  
T.C. Yu  
A. Chen  
P.S. Yen

# New Symptomatic Compression Fracture after Percutaneous Vertebroplasty at the Thoracolumbar Junction

**BACKGROUND AND PURPOSE:** The purpose of this study was to investigate the risk factors for new symptomatic vertebral compression fractures after vertebroplasty at the thoracolumbar junction.

**MATERIALS AND METHODS:** We conducted a retrospective analysis of 53 patients treated with percutaneous vertebroplasty at the thoracolumbar junction (T12, L1). The follow-up period was 15–27 months. The occurrence of new symptomatic vertebral compression fractures was recorded after vertebroplasty. We evaluated patient age and sex, amount of injected cement, vacuum clefts in the collapsed bodies, initial wedge angle of the compression fracture, change of the wedge angle after vertebroplasty, intradiskal cement leak, and percentage of height restoration of the vertebral body. In this report, we surveyed the possible risk factors for new symptomatic vertebral compression fractures.

**RESULTS:** Thirty-nine (74%) of the 53 patients had fluid and/or air in the compression fracture at the thoracolumbar junction (T12, L1). Eight (20.5%) of the 39 patients with vacuum clefts had new symptomatic compression fracture after vertebroplasty between 1 month and 4 days after surgery to 23 months and 4 days after surgery. The patients with new symptomatic compression fracture had higher initial wedge angle and wedge angle change (more than 7°) after vertebroplasty than those without fractures; these data were considered statistically significant.

**CONCLUSIONS:** The incidence of vacuum clefts in the compression fracture at the thoracolumbar junction is high (74%). The severity of initial wedge angle and wedge angle change affects the incidence of new symptomatic compression fracture.

Flexion and extension of the spine is most dynamic at the thoracolumbar junction.<sup>1</sup> Vertebral insufficiency fractures at these levels would be less likely to undergo complete healing than the other vertebral levels, which are comparatively immobile. One study reported that elderly patients with a severely collapsed or deformed fracture at the thoracolumbar junction were at high risk of developing a nonunion of the fracture.<sup>2</sup> This unhealed fracture appeared as an air-filled cleft on conventional radiograph or as fluid-filled cavities on MR imaging. Although some long-term follow-up studies<sup>3,4</sup> have discussed the association between new compression fracture and vertebroplasty, the risk factors associated with new symptomatic compression fracture and vertebroplasty are still under investigation. In this study, we evaluated possible risk factors of developing new symptomatic compression fracture after vertebroplasty at the thoracolumbar junction.

## Materials and Methods

Between September 2002 and October 2004, our medical center performed percutaneous vertebroplasty procedures on 174 patients with 201 levels of vertebral bodies. Of these 174 patients, we excluded those who did not have a compression fracture at the thoracolumbar junction (T12, L1) and who did not have preoperative or postoperative radiographs. We also excluded patients who had laminectomy and

screw fixation, a history of steroid use, and multiple myeloma or pathologic fracture.

Only 53 patients (42 female, 11 male; mean age, 76.1 years) with 61 vertebral body fractures (T12 or L1, 53; 8 at other levels) were eligible for the study. The preoperative spine MR imaging and conventional radiographs were taken about 1–7 days before the procedure. The image protocol included sagittal T1-weighted (TR, 600–650 ms; TE 9–11 ms) and T2-weighted (TR, 3500–3750 ms; TE, 100–116 ms) spin-echo images, short  $\tau$  inversion recovery (STIR) images (TR, 3800 ms; TE, 38 ms; TI, 150 ms) with 4-mm section thickness. The first radiograph was taken about 1–3 days after the vertebroplasty. The final follow-up images were obtained and reviewed 15–27 months after the procedure. Only patients with new symptomatic fracture after vertebroplasty had follow-up MR imaging. The indication for vertebroplasty was painful compression fracture with hyperintensity on sagittal STIR images with or without a vacuum cleft. Patients with chronic compression fractures without abnormal signal intensity change on spine MR imaging were excluded.

Two experienced neuroradiologists (P.S.Y., C.C.L.) performed the procedure using a modified form of the method used by Jensen et al.<sup>5</sup> The patient was in the prone position under local anesthesia. An 11- or 13-gauge bone marrow biopsy needle was used to puncture the collapsed vertebral body through one of the pedicles, and the needle was advanced to the anterior third of the vertebral body or into the vacuum cleft, under fluoroscopic guidance. One 20-mL syringe kept under negative pressure was connected to the biopsy needle to suck out the fluid or bone marrow. The bone cement (Surgical Simplex P; Stryker Howmedica Osteonics, Limerick, Ireland) was prepared by mixing the copolymer powder with sterile barium sulfate and monomer liquid for polymerization. The bone cement was injected manually under fluoroscopic guidance. The injection was stopped if the bone cement 1) filled the vacuum cleft, 2) reached the posterior

Received August 2, 2006; accepted after revision October 4.

From the Departments of Medical Imaging (P.S.Y., C.C.L., A.C.), Orthopedics (I.H.C., T.C.Y.), and Anesthesiology (A.C.), Buddhist Tzu Chi General Hospital, Tzu Chi University, Hualien, Taiwan.

Address correspondence to Dr. Pao-Sheng Yen, Department of Radiology, Buddhist Tzu Chi General Hospital, Tzu Chi University, 707, Section 3, Chung Yang Road, Hualien, Taiwan; e-mail:cc@tma.tw

DOI 10.3174/ajnr.A0520

**Table 1: Patients undergoing vertebroplasty at thoracolumbar junction with and without vacuum clefts**

Group	No of Patients	Age (yrs)	Sex (F/M, no.)	Cement (mL)	Intradiskal Leak (u disk*:l disk†)	Initial Wedge Angle (°)‡	Wedge Angle Change§	Improved Percentage of Height¶
I	14	71.6	11/3	3.8	3:1	15.3	1.2	9.0
II	39	77.7	31/8	5.3	6:2	14.5	6.3	48.3
<i>P</i> value		.01		.006		.42	<.001	.001

**Note:**—F indicates female; M, male; u, upper; l, lower.

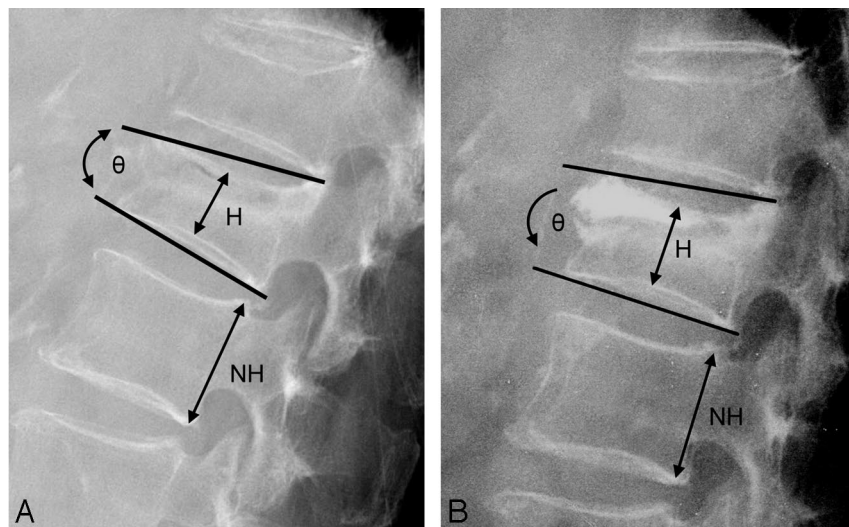
\* Cement leakage into the upper disk.

† Cement leakage into the lower disk.

‡ Wedge angle of the collapsed body before vertebroplasty.

§ (Wedge angle change) before — (wedge angle) after vertebroplasty.

¶ [(H/HN) post — (H/HN)pre]/(H/HN) pre.



**Fig 1.** Measurement of the collapsed vertebral body before (A) and after (B) vertebroplasty. (H indicates the height of the collapsed body at the center; NH, the height of the posterior border of an adjacent normal vertebral body;  $\theta$ , the wedge angle as described by Teng et al.<sup>7</sup>)

fourth of the vertebral body, or 3) was leaking into the perivertebral veins or significantly leaking into the disk space.

The preoperative spine MR imaging and plain film were reviewed to identify a vacuum cleft. The vacuum clefts of the vertebral bodies are depicted as fluid- or air-filled clefts inside the vertebral body. Fluid-filled clefts were defined as well-demarcated, linear, or ellipsoid areas of T2 prolongation, which were isointense relative to CSF on T2-weighted images acquired in the sagittal plane.<sup>6</sup> All the images were blindly reviewed by the 2 neuroradiologists (P.S.Y., C.C.L.). If they disagreed on interpretation of the images, they reviewed the data together to establish a consensus. The patients were divided into 2 groups: group I consisted of patients with no vacuum clefts in the collapsed vertebral body, and group II consisted of those with vacuum clefts (Table 1). The digital files of each patient's radiographs before and after the vertebroplasty were used to measure the following: 1) wedge angle of the compressed vertebral body, 2) height at the center of the collapsed vertebral body, and 3) height of the posterior border of an adjacent normal vertebral body. We used the method described by Teng et al<sup>7</sup> to measure the wedge angle and the height of the collapsed vertebral body. The height improvement at the center of the vertebral body was also calculated as follows: [(H/HN)post — (H/HN)pre]/[(H/HN)pre] (Fig 1). The 2 neuroradiologists (P.S.Y., C.C.L.) measured the collapsed levels at T12 or L1 in the 53 patients. The intraobserver and interobserver reproducibility of the measurements was evaluated by intraclass correlation coefficients. We ignored the bony spur and focal protrusion of the bone cement to avoid possible biases in taking the measurements before and after the procedure. The measurements were discussed between the authors to establish consensus. The intervals of new compression fracture were recorded according to the time between the initial vertebroplasty and

the follow-up MR imaging, which showed new compression fracture.

We used the single-tail Student *t* test to evaluate the difference between groups I and II. To analyze the risk factors in group II, logistic regression with SPSS software (SPSS, Chicago, Ill) was applied. We set  $\alpha$  value equal to 0.05 as statistically significant.

## Results

The intraclass correlation coefficients for the height of the vertebral body and the wedge angle were 0.94 and 0.92

(C.C.L.) and 0.97 and 0.96 (P.S.Y.). The interobserver reproducibility between the 2 authors was 0.92 and 0.88 for the vertebral body height and wedge angle, respectively.

Of the 53 patients, vacuum clefts were found in 39 (74%) treated vertebral bodies at the thoracolumbar junction. Eight (15.1%) of the 53 patients developed a new compression fracture after vertebroplasty. The mean age and sex distributions were not significantly different between groups I and II, though the mean age was a little higher in group II. The amount of injected cement, wedge angle change, and percentage of height restoration were significantly higher in group II than in group I.

We further analyzed group II with logistic regression to evaluate the correlation of these factors: age, sex, initial wedge angle, intradiskal leakage, wedge angle change, and percentage of change of height. Initial wedge angle, change in wedge angle, and percentage of height restoration had significantly increased odds ratio (Table 2). As a result of the correlation between wedge angle change and percentage change of height, putting these 2 factors in 1 model would cause a colinear problem. To avoid the colinear problem, we performed the logistic regression of wedge angle change with adjustment of the age and sex factors. The odds ratio was 1.46. (Table 3). The odds ratio of the initial wedge angle to sustaining a new compression fracture was 1.59 after correlation of the age and sex factors (Table 4).

The details of the 8 patients are summarized in Table 5. There were 11 total new compression fractures in the 8 patients. Eight (72.7%) of the 11 new compression fracture levels were adjacent to the previously treated vertebral body. In Ta-

**Table 2: Risk factor analysis in group II with logistic regression**

Factors	Odds Ratio	95.0% CI		P Value
		Lower	Upper	
Age	1.05	0.92	1.20	.44
Sex	2.04	0.21	19.53	.54
Cement	1.06	0.70	1.62	.79
Intradiskal leak	2.55	0.27	24.06	.42
Initial wedge angle	1.42	1.11	1.81	.005
Wedge angle change	1.02	1.00	1.03	.02
Improved percentage of height	1.02	1.00	1.03	.03

Note:—CI indicates confidence interval.

**Table 3: Risk predictor-wedge angle change of new-onset compression fracture after adjusting for age and sex in group II**

Factors	Odds Ratio	95.0% CI		P Value
		Lower	Upper	
Wedge angle change	1.46	1.11	1.91	.006
Age	1.07	0.90	1.28	.44
Sex	0.17	0.002	18.84	.46

Note:—CI indicates confidence interval.

**Table 4: Risk predictor-initial wedge angle of new-onset compression fracture after adjusting for age and sex in group II**

Factors	Odds Ratio	95.0% CI		P Value
		Lower	Upper	
Initial wedge angle	1.59	1.17	2.17	.003
Age	1.31	1.01	1.70	.04
Sex	8.95	0.08	1027.5	.37

Note:—CI indicates confidence interval.

ble 6, the group II patients were divided into 3 subgroups according to the initial wedge angle. Eight of the 39 patients had initial wedge angles of more than 20°, and 6 (75%) of these 8 patients developed new symptomatic compression fracture after vertebroplasty. In Table 7, the group II patients were subdivided into 2 subgroups according to the wedge angle change. Nineteen of the 39 patients had wedge angle reduction of more than 7°. Eight (42%) of 19 patients sustained new symptomatic compression fracture after vertebroplasty.

## Discussion

The association between percutaneous vertebroplasty and newly sustained symptomatic compression fracture is still under investigation. New symptomatic compression fracture after vertebroplasty has been reported in some studies.<sup>3,4</sup> In those studies, the incidence of new vertebral body fracture after percutaneous vertebroplasty was reported to be 12.4%<sup>3</sup> and 21.7%.<sup>4</sup> In our study, the incidence was 15.1%. This incidence was not higher than in other studies, though we limited the treated vertebral level to the thoracolumbar junction. Group I (patients without vacuum clefts), showed no new symptomatic compression fracture after vertebroplasty. Vacuum clefts of vertebral bodies can represent unhealed fracture and can appear as fluid-filled cavities on MR imaging or as gas-filled cavities on conventional radiographs.<sup>6</sup> Two studies<sup>2,7</sup> have reported high frequency of these clefts at the thoracolumbar junction. The flexion and extension dynamic mobility of the spine was thought to be responsible for insufficient fracture at the thoracolumbar junction. In our study, 39 (74%) of the 53 patients had compression fracture with vacuum clefts

at the thoracolumbar junction. Almost three fourths of the patients with fracture at the thoracolumbar junction were found to have vacuum clefts.

Several studies<sup>6,8,9</sup> have demonstrated that vertebroplasty can effectively improve vertebral body height and wedge angle. However, the long-term outcome associated with restoration of the height and correction of wedge angle was not reported. In our study, when we put the wedge angle change and percentage of height restoration into a single logistic regression model, there was correlation between these 2 factors. The wedge angle change was more remarkable than the percentage of height restoration. This might be attributed to the following factors: 1) the increased height and wedge angle was proportional and 2) the bone cement was deposited mainly in the anterior three fourths of the vertebral body. The 8 patients in group II who sustained new symptomatic compression fracture after vertebroplasty showed greater initial wedge angle and wedge angle change (21.4° and 12.6°) than the group II patients without new fractures (12.7° and 4.7°) and the patients in group I (15.3° and 1.2°). In those 8 patients, the wedge angle change ranged from 7° to 20°. In previously published studies,<sup>6,8,9</sup> the mean reduction of the wedge angle ranged from 3.5° to 7.4°. The odds ratio of wedge angle change to sustaining new symptomatic compression fracture was 1.46. This means that if the wedge angle change increased 1 degree, then the risk of the new-onset fracture has increased 0.46 times. In addition, 8 (42%) of 19 patients (Table 5) who had a wedge angle change of more than 7° sustained new symptomatic compression fractures. The incidence was higher than the incidence reported and also higher than our average.

The initial wedge angle is another factor shown to increase the risk of new symptomatic compression fracture. When we put the initial wedge angle and wedge angle change into 1 logistic model with age and sex adjustment, the initial wedge angle was more remarkable than the wedge angle change. This may indicate that wedge angle changes are affected by the initial severity of the wedge deformity. Furthermore, the odds ratio of initial wedge angle to sustaining new symptomatic compression fracture is 1.59, which means that the risk of new compression fracture increased 0.59 times if the initial wedge angle increased 1 degree. However, this was a retrospective study with nonrandomized data. To definitively demonstrate the risks of these 2 possible factors (wedge angle change and initial wedge angle) to cause new symptomatic compression fracture will require well-designed, randomized, controlled trials comparing vertebroplasty with conservative therapy.

Currently, maximum or sufficient filling during vertebroplasty is still controversial.<sup>10</sup> The average injected amount of cement was 3.8 mL in the patients without vacuum clefts and 5.3 mL in the patients with vacuum clefts. Vacuum clefts required more cement to fill the space, but the average injected amount of cement in group II demonstrated no difference in the development of new compression fracture. Thus, the amount of cement injection did not influence the development of an adjacent new compression fracture in our study.

One study<sup>11</sup> reported that cement leakage into the disk during vertebroplasty increases the risk of a new fracture of adjacent vertebral bodies. In our study, 4 patients in group I and 8 patients in group II experienced cement leakage into the upper or lower disk. However, only 1 patient from group II



**Table 5: Patients who sustained new compression fractures after undergoing vertebroplasty**

Pt No.	Age	Sex	PVP Level	Fluid/Air*	Ad Fx po PVP† (mo/d)	Level of Ad Fx	Cement (mL)	Initial Wedge Angle (°)	Wedge Angle Change	Restoration Percentage of Height (%)	Disk Rupture‡
1	87	M	T12	F	23/4	T11, L1	8	24	20	176.6	Lower
2	82	F	L1	F/A	2/22	T12	8	21	18	62.0	Upper
3	72	F	T12	A	1/4	T9, T11	4	26	9	163.4	Upper
4	73	F	T12	F	1/24	L1	5	24	16	170.9	Nil
5	82	F	T12	A	15/7	T9, T11	3	22	8	36.0	Upper
6	71	F	T12	A	5/16	T11	5	27	13	20.4	Upper
7	78	F	L1	F	12	L2	4	17	7	25.4	Nil
8	88	F	L1	F	3/15	L5	3.5	10	10	30.2	Nil

**Note:**—PVP level indicates treated level of percutaneous vertebroplasty; Fx, fracture; Ad, adjacent.

\* Vacuum cleft with fluid or air in the PVP level.

† Interval from the date of PVP to the follow-up MRI in which new symptomatic compression fracture was depicted.

‡ Disk rupture with migration toward the new adjacent compression level in the follow-up MRI.

**Table 6: Association of initial wedge angle and new compression fracture in group II patients**

Initial wedge angle	≤10	11–20	>20
No. of patients	7	24	8
New fracture*	1	1	6
Percentage (%)	14	4	75

\* Patient sustained new symptomatic compression fracture after undergoing vertebroplasty.

**Table 7: Association of wedge angle change and new compression fracture in group II patients**

Wedge Angle Change*	<7	≥7
No. of patients	20	19
New fracture†	0	8
Percentage (%)	0	42

\* (Wedge angle) before vertebroplasty — (wedge angle) after vertebroplasty.

† Patient developed new symptomatic compression fracture after undergoing vertebroplasty.

sustained a new, nonadjacent compression fracture 3 months after the vertebroplasty. Therefore, we did not find a connection between disk leakage and new adjacent compression fracture.

There were several limitations in this study. We did not have data to survey the severity of osteoporosis in different groups, which was thought to be a significant factor for progression of compression fracture. Furthermore, the number of patients in our study was small. Another limitation is that only patients who had symptomatic new compression fracture received MR imaging in the follow-up period. Asymptomatic new compression fracture with only MR imaging signal intensity change may have been missed.

## Conclusions

The incidence of vacuum clefts in the compression fracture at the thoracolumbar junction is high (74%). This study showed

that increased initial wedge angle and change in wedge angle increased the incidence of new symptomatic compression fracture. To definitively demonstrate the relationship between these 2 possible causative factors (wedge angle change and initial wedge angle) and the incidence of new-onset vertebral fracture will require well-designed, randomized, controlled trials comparing vertebroplasty with conservative therapy.

## References

1. Lindh M. **Biomechanics of the lumbar spine.** In: Frankel H, Nordin M, eds. *Basic Biomechanics of the Skeletal System.* Philadelphia: Lea and Febiger; 1981:255–90
2. Mirovsky Y, Anekstein Y, Shalmon E, et al. **Vacuum clefts of the vertebral bodies.** *AJNR Am J Neuroradiol* 2005;26:1634–40
3. Uppin AA, Hirsch JA, Centenera LV, et al. **Occurrence of new vertebral body fracture after percutaneous vertebroplasty in patients with osteoporosis.** *Radiology* 2003;226:119–24
4. Syed MI, Patel NA, Jan S, et al. **New symptomatic vertebral compression fractures within a year following vertebroplasty in osteoporotic women.** *AJNR Am J Neuroradiol* 2005;26:1601–04
5. Jensen ME, Evans AJ, Mathis JM, et al. **Percutaneous polymethylmethacrylate vertebroplasty in the treatment of osteoporotic vertebral body compression fractures: technical aspects.** *AJNR Am J Neuroradiol* 1997;18:1897–904
6. Lane JI, Maus TP, Wald JT, et al. **Intravertebral clefts opacified during vertebroplasty: pathogenesis, technical implications, and prognostic significance.** *AJNR Am J Neuroradiol* 2002;23:1642–46
7. Teng MM, Wei CJ, Wei LC, et al. **Kyphosis correction and height restoration effects of percutaneous vertebroplasty.** *AJNR Am J Neuroradiol* 2003;24:1893–900
8. Dublin AB, Hartman J, Latchaw RE, et al. **The vertebral body fracture in osteoporosis: restoration of height using percutaneous vertebroplasty.** *AJNR Am J Neuroradiol* 2005;26:489–92
9. Carlier RY, Gordji H, Mompoin DM, et al. **Osteoporotic vertebral collapse: percutaneous vertebroplasty and local kyphosis correction.** *Radiology* 2004;233:891–98
10. Baroud G, Heini P, Nemes J, et al. **Biomechanical explanation of adjacent fractures following vertebroplasty.** *Radiology* 2003;229:606–07; author reply 607–08
11. Lin EP, Ekholm S, Hiwatashi A, et al. **Vertebroplasty: cement leakage into the disc increases the risk of new fracture of adjacent vertebral body.** *AJNR Am J Neuroradiol* 2004;25:175–80