



Get Clarity On Generics

Cost-Effective CT & MRI Contrast Agents



FRESENIUS
KABI

WATCH VIDEO

AJNR

New catheter for tortuous vertebral artery.

F C Guinto, Jr

AJNR Am J Neuroradiol 1982, 3 (1) 85-86

<http://www.ajnr.org/content/3/1/85.citation>

This information is current as
of August 13, 2025.

New Catheter for Tortuous Vertebral Artery

Faustino C. Guinto, Jr.¹

The difficulty of catheterizing markedly tortuous vertebral arteries is well known to cerebral angiographers. When catheterization by the transfemoral approach fails, a left retrograde brachial flush injection or transaxillary vertebral catheterization may be performed as alternative techniques in opacifying posterior fossa vessels. These additional approaches can be obviated by using a J tip catheter, tailored specifically for the very tortuous left vertebral artery origin.

Technique

The new catheter tip configuration is fashioned out of a straight, 5 French, red, polyethylene catheter (Cook, Bloomington, Ind.). Its distal primary curve is formed by holding the catheter in a tight J configuration over a jet of steam (fig. 1A). A 12 cc plastic syringe is useful in holding the end of the catheter over the steam; it also protects the tapered

Fig. 1.—A, Forming the primary curve. End of catheter is inserted into tip of 12 cc plastic syringe and held in J configuration over steam. B, Configuration of new vertebral catheter.

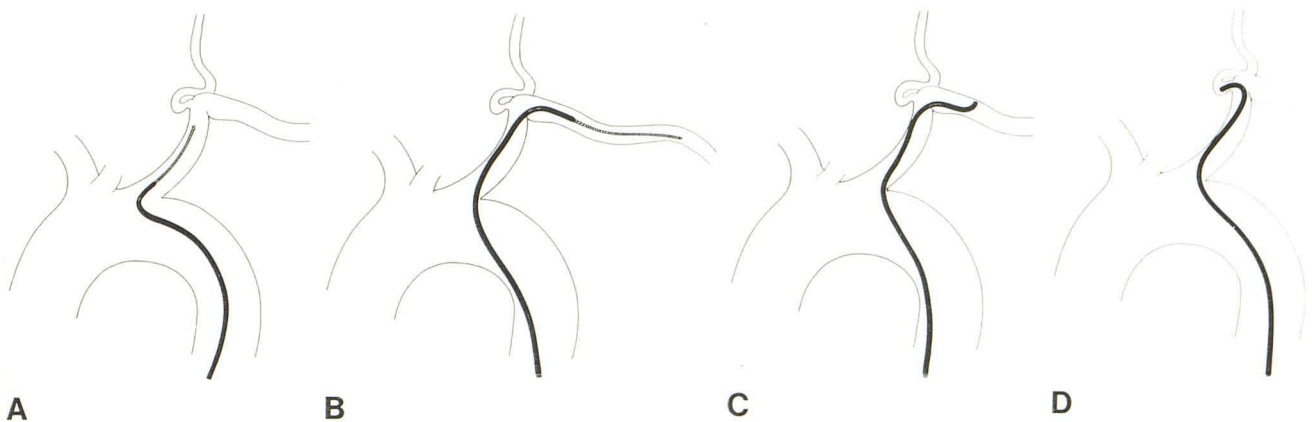
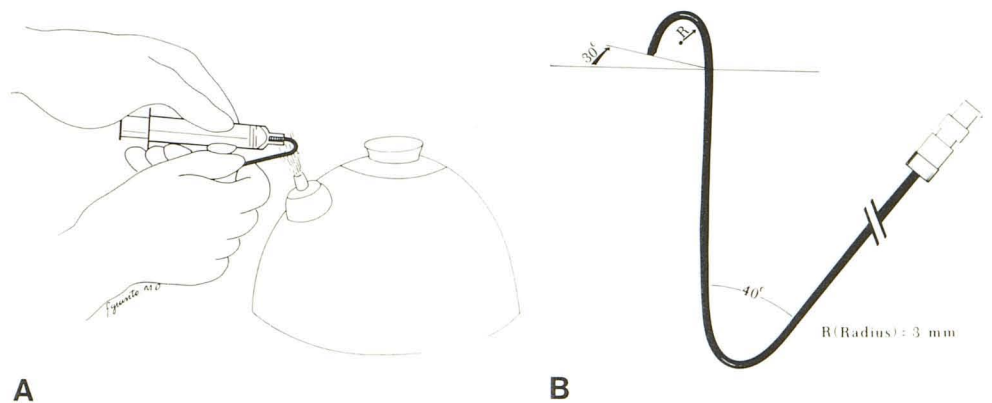


Fig. 2.—Technique of catheter placement. A, Catheter leads guide wire into left subclavian artery. B, Guide wire advanced as far as axillary artery followed by advancement just beyond thyrocervical trunk. At this point, guide

wire is removed. C, Catheter gently withdrawn until reformed tip catches and hooks into vertebral artery. D, Final position of catheter.

Received August 7, 1981; accepted September 9, 1981.

¹ Department of Radiology, Division of Neuroradiology, University of Texas Medical Branch, Galveston, TX 77550.

AJNR 3:85-86, January/February 1982 0195-6108/82/0301-0085 \$00.00 © American Roentgen Ray Society

tip from flaring from direct heat. A secondary curve is then applied 7 cm from the primary J curve. Its purpose is to counteract and prevent the tip from rotating away from the vertebral artery origin. The orientation of the primary curve relative to the secondary curve is very important. The tip must be oriented posteriorly by about 30° to conform with the direction of take-off of the vertebral artery (fig. 1B).

Figure 2 depicts technique of catheter placement. The object is to seat the tip at the tortuous portion of the vessel for injection. An injection rate of 6 ml/sec for a total of 9 ml

of contrast material should result in satisfactory opacification of the posterior fossa vasculature.

Discussion

Of more than 500 vertebral angiographies over a 3 year period, 14 patients were found to have tortuous left vertebral arteries in whom commercially available catheters of various shapes failed. Application of the new catheter proved successful in all 14 patients. No complications were encountered.