



## Get Clarity On Generics

Cost-Effective CT & MRI Contrast Agents

**FRESENIUS  
KABI**

[WATCH VIDEO](#)

# AJNR

## **Percutaneous Transluminal Angioplasty of the Brachiocephalic Arteries**

Amir Motarjeme, John W. Keifer and Albert J. Zuska

*AJNR Am J Neuroradiol* 1982, 3 (2) 169-174

<http://www.ajnr.org/content/3/2/169>

This information is current as  
of August 18, 2025.

# Percutaneous Transluminal Angioplasty of the Brachiocephalic Arteries

Amir Motarjeme<sup>1</sup>  
John W. Keifer  
Albert J. Zuska

Percutaneous transluminal angioplasty was used to treat atherosclerotic lesions in 22 brachiocephalic arteries in 20 patients during a 2½ year period. Seven subclavian, 13 vertebral, one external carotid, and one common carotid arteries were involved. Nineteen arteries were successfully dilated, but dilatation of two vertebral arteries and attempted recanalization of one subclavian artery failed. The first patient treated was still asymptomatic at 30 months and no symptoms recurred in any of the successfully treated patients. No complications were encountered during these procedures

Since the introduction of the balloon dilatation catheter by Grüntzig and Hopff [1] in 1974, transluminal angioplasty, originally described by Dotter and Judkins [2], has been widely used to treat atherosclerotic occlusive disease of the coronary, renal, iliac, and femoral arteries [3–9]. However, transluminal angioplasty of brachiocephalic arteries has been only rarely performed due to fear of cerebral emboli. We have reported successful dilatation of the vertebral arteries [10], and, in this paper, we describe our experience in dilatation of the brachiocephalic arteries during a 2½ year period.

## Subjects and Methods

Transluminal angioplasty of seven subclavian, 13 vertebral, one external carotid, and one common carotid arteries was attempted in 13 men and seven women 57–84 years old.

### *Subclavian Artery*

Seven patients, two women and five men, were treated for subclavian stenosis, all on the left side. Two patients had claudication and numbness of the arm due to severe subclavian stenosis distal to the vertebral artery. Five patients had occlusive disease proximal to the vertebral artery, three with symptoms of subclavian steal, all complaining of severe dizziness. Interarterial pressures were measured in all patients, both in pre- and poststenotic areas. The gradients were greater than 70 mm Hg in all patients and as high as 100 mm Hg in one with subclavian steal.

After selective catheterization of the subclavian artery, the stenosis and the origin of the vertebral artery were marked on the skin with a lead marker to point out the site of dilatation and to prevent accidental dilatation at the origin of the vertebral artery. Stenoses in symptomatic subclavian arteries are usually tight and do not accommodate a J guide wire, thus a selective catheter is placed just proximal to the stenosis and a soft, straight guide wire is carefully advanced past the stenosis, then followed by the angiographic catheter. The straight guide wire is then exchanged for a long exchange J guide wire, which is inserted well beyond the stenosis into the axillary artery. The angiographic catheter is then exchanged for a proper sized balloon catheter (a balloon 1 cm longer than the length of the stenosis with a diameter 1 mm smaller than the normal artery distal to the stenosis). A balloon diameter of 8–9 mm is usually required for dilatation of proximal lesions. It is advisable to keep the guide wire in place during dilatation of proximal lesions to prevent the balloon catheter from sliding back into the aorta. The balloon is inflated by hand using

This article appears in the March 1982 issue of *AJR* and the March/April 1982 issue of *AJNR*.

Received April 28, 1981; accepted after revision November 2, 1981.

Presented at the annual meeting of the American Roentgen Ray Society, San Francisco, March 1980.

<sup>1</sup> All authors: Department of Radiology, St. Anne's Hospital, 4950 W. Thomas St., Chicago, IL 60651. Address reprint requests to A. Motarjeme.

*AJNR* 3:169–174, March/April 1982  
0195–6108/82/0033-0169 \$00.00  
© American Roentgen Ray Society



dilute contrast medium. A postangioplasty arch aortogram is obtained in all patients with proximal lesions, and subclavian arteriograms are obtained in patients with lesions distal to the vertebral artery.

#### *Vertebral Artery*

Dilatation of 13 vertebral arteries was attempted in 11 patients (both vertebral arteries in two patients) complaining of the typical symptoms of vertebral basilar insufficiency: dizziness, blurred vision, ataxia, and drop-attack. A complete angiographic assessment of the cerebral circulation, including both carotid arteries and vertebral basilar system, was made in all patients. Five patients had isolated vertebral artery disease, while the others had had carotid artery stenosis treated by arterectomy without relief of symptoms. Both vertebral arteries were successfully dilated in one patient. Transluminal angioplasty was performed only when stenoses were at the origin of the vertebral artery and only when there was no additional occlusion of the vertebral basilar system. Patients with both vertebral and carotid artery stenosis were first treated with carotid endarterectomy and vertebral artery dilatation was only considered if the symptoms were not relieved. Furthermore, transluminal dilatation was performed when reconstructive vascular surgery was warranted and, in some, already planned.

After selective catheterization of the vertebral artery, via femoral artery, an exchange guide wire, usually straight, was advanced well beyond the point of stenosis. With the guide wire in place, the angiographic catheter was exchanged for a 7 French Grüntzig balloon catheter, having a balloon 1 cm long and 4 mm in diameter. The balloon was inflated by hand using dilute contrast medium for about 5 sec and repeated two or three times. The balloon catheter was then withdrawn back to the subclavian artery and a postangioplasty subclavian arteriogram was routinely obtained. No intraarterial pressures were measured since the catheter occludes the lumen of the vertebral artery. Dilatation was considered successful when the postangioplasty arteriogram showed a normal-appearing artery or considerably increased lumen of the artery (at least 50%) and if the vertebral basilar insufficiency symptoms were relieved.

#### *Carotid Artery*

Angioplasty of one external and one common carotid artery was attempted in two patients. Both procedures were performed intraoperatively during carotid bifurcation endarterectomy. The external carotid artery was dilated in a patient who underwent endarterectomy for treatment of an ulcerated plaque at carotid bifurcation. The common carotid artery was dilated in a man who had stenosis of both the proximal common carotid and the internal carotid arteries. The stenoses were approached through the endarterectomy incision using a J guide wire to lead the angioplasty catheter through the stenosis. The internal carotid artery was occluded by a Javid shunt during dilatation of the common carotid artery. A 9 French catheter, having a balloon 3 cm long and 9 mm in diameter, was required for dilatation of the common carotid artery.

No anticoagulation treatment was used during or after angioplasty procedures in the first 15 cases, but the rest of the patients were treated with 8,000 U of heparin intraarterially immediately after initial catheterization. The heparin anticoagulation was always reversed with protamine before removal of the catheter. No anticoagulation treatment was given after the dilatation procedure but patients were treated with Persantine 75 mg three times a day before and after transluminal angioplasty.

## **Results**

### *Subclavian Artery*

Of seven patients with occlusive lesions of the subclavian artery, five were successfully treated with percutaneous transluminal angioplasty. Two had stenoses distal and three proximal to the vertebral artery. One of the proximal lesions was associated with subclavian steal, which was corrected immediately by dilatation. Postangioplasty arteriograms revealed normal-appearing arteries, and pressure gradients were abolished. All five patients became symptom-free.

Partial dilatation was achieved in proximal subclavian artery stenosis in a 58-year-old man with subclavian steal, complaining of severe dizziness. Arterial pressure gradient was diminished from 100 mm Hg to 40 mm Hg, but no immediate reversal of the vertebral artery flow was seen. Postangioplasty arteriogram showed increased lumen of the disease subclavian artery. The patient's dizziness improved, but was not totally alleviated.

Attempted recanalization of a totally occluded subclavian artery in a patient with subclavian steal failed. This patient was subsequently treated with carotid subclavian bypass.

### *Vertebral Artery*

Eleven vertebral arteries, eight on the left and three on the right, were successfully dilated in 13 attempts. The procedure failed in two arteries due to tortuosity of the vertebral artery in one and the right subclavian artery in one. Both vertebral arteries were successfully dilated in one patient. Carotid endarterectomy was ineffective in relieving symptoms in four patients having both vertebral and carotid stenoses, but the symptoms were relieved with dilatation of the vertebral artery. Arteriotomy and venous patch of the left vertebral artery in a patient with bilateral vertebral artery stenosis diminished his dizziness, but it was only entirely relieved after successful dilatation of the right vertebral artery.

### *Carotid Artery*

An external and a common carotid artery were successfully dilated intraoperatively in two patients. The external carotid artery was seen to be completely dilated on a 6 month postangioplasty arteriogram (fig. 1). A 50% stenosis of a common carotid artery was improved to a 20% stenosis.

## **Representative Case Reports**

### *Case 1*

An 84-year-old woman had numbness and claudication of her left arm for 6 months. Brachial systolic blood pressure was 190 mm Hg on the right but only 104 mm Hg on the left. A selective left subclavian arteriogram showed severe stenosis distal to the vertebral artery (fig. 2A). An 80 mm Hg gradient was measured across the stenosis. The stenosis was dilated using a 7 French Grüntzig



Fig. 1.—61-year-old man with weakness of right arm. Carotid arteriogram showed ulcerated plaque of common and internal carotid arteries in addition to severe stenosis of external carotid artery. External carotid artery was dilated intraoperatively. **A**, Ulcerated plaque of posterior aspect of internal carotid artery. Severe stenosis of external carotid artery (*arrow*). **B**, Postangioplasty arteriogram 6 months later. Complete dilatation of external carotid artery (*arrow*). Small linear defects are surgical clips used during carotid endarterectomy.

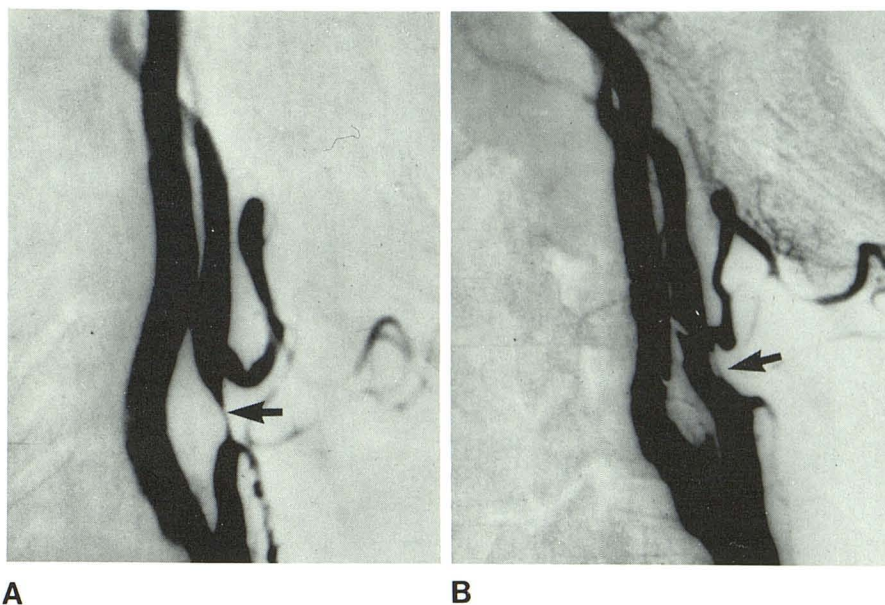
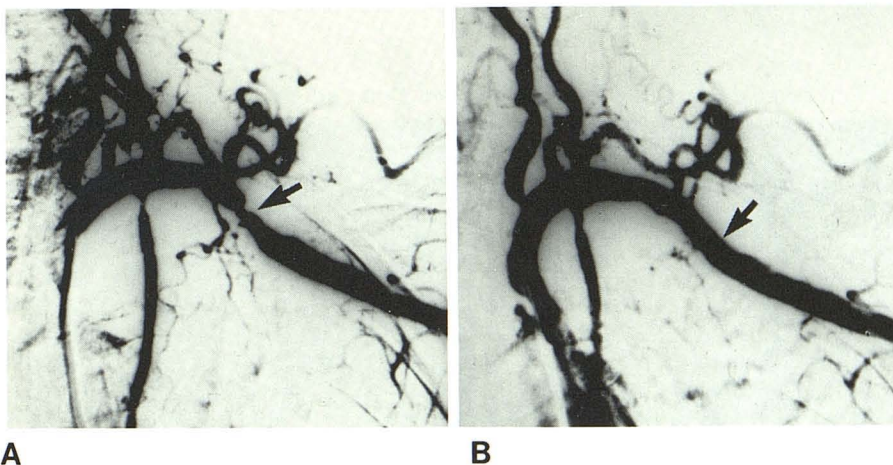


Fig. 2.—Case 1, 84-year-old woman with claudication and numbness of left arm. **A**, Selective subclavian arteriogram. Severe stenosis distal to vertebral artery (*arrow*). **B**, Postangioplasty arteriogram. Complete dilatation and normal-appearing arterial lumen (*arrow*).



balloon catheter 1 cm long and 6 mm in diameter. Postangioplasty intraarterial pressure measurements showed no gradient, and a postangioplasty arteriogram showed a normal-appearing artery (fig. 2B). Claudication and numbness disappeared and the patient was still asymptomatic after 2½ years.

#### Case 2

A 54-year-old man had dizziness for 1 year. A four-vessel cerebral arteriogram showed no carotid artery disease, but there was severe stenosis of the proximal left subclavian and the origin of the right vertebral arteries (figs. 3A and 3B). There was 70 mm Hg gradient across the stenosis of the subclavian artery. Percutaneous transluminal angioplasty of the left subclavian artery relieved the stenosis and the arterial gradient (fig. 3C). The patient had no further dizziness and was still asymptomatic after 2 years.

#### Case 3

A 72-year-old man had dizziness. A four-vessel cerebral arteriogram revealed no carotid artery disease, but there was severe stenosis of the origin of both vertebral arteries (fig. 4A). Percutaneous transluminal angioplasty of both vertebral arteries was attempted, but only the left one was successfully dilated (fig. 4B). Dilatation of the right vertebral artery was technically unsuccessful due to tortuosity of the right subclavian artery. The dizziness was alleviated and the patient was still asymptomatic 6 months after the procedure.

#### Case 4

A 62-year-old man had severe dizziness and occasional numbness of the left arm. A four-vessel cerebral arteriogram revealed no carotid artery or intracranial occlusive disease, but there was severe



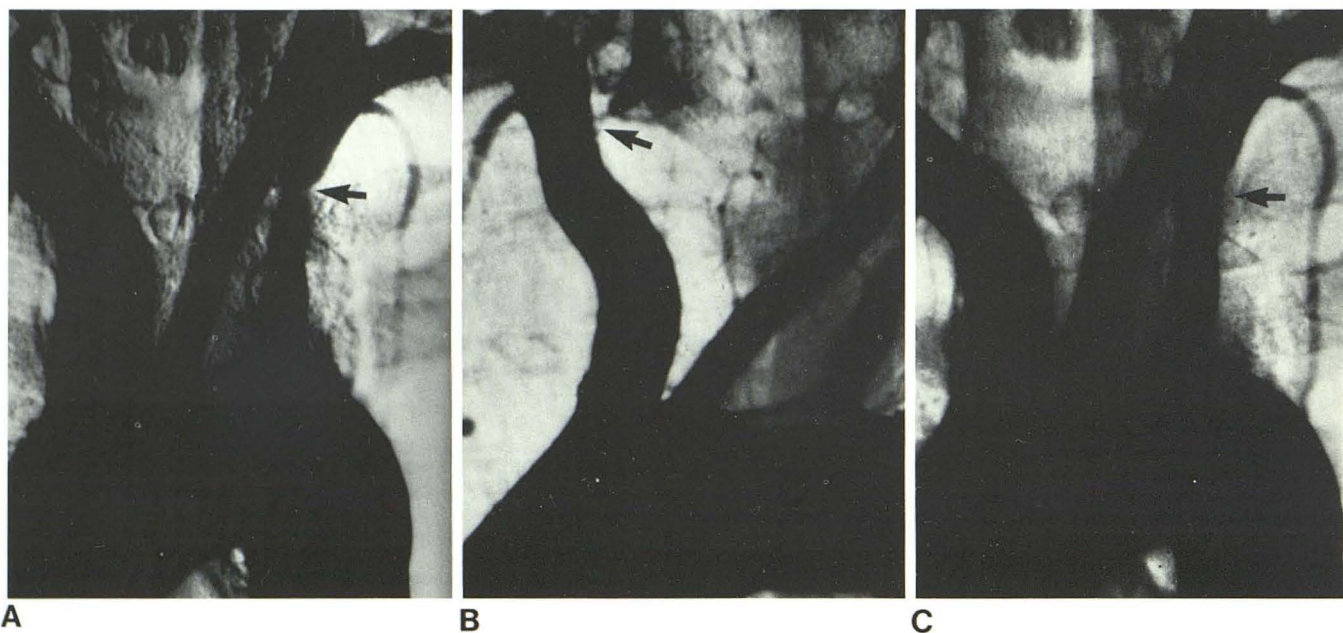


Fig. 3.—Case 2, 54-year-old man with dizziness. **A**, Stenosis of proximal left subclavian artery (arrow). **B**, Arch aortogram in oblique position. Stenosis

of right vertebral artery (arrow) also. **C**, Postangioplasty arteriogram. Dilatation of left subclavian artery (arrow).

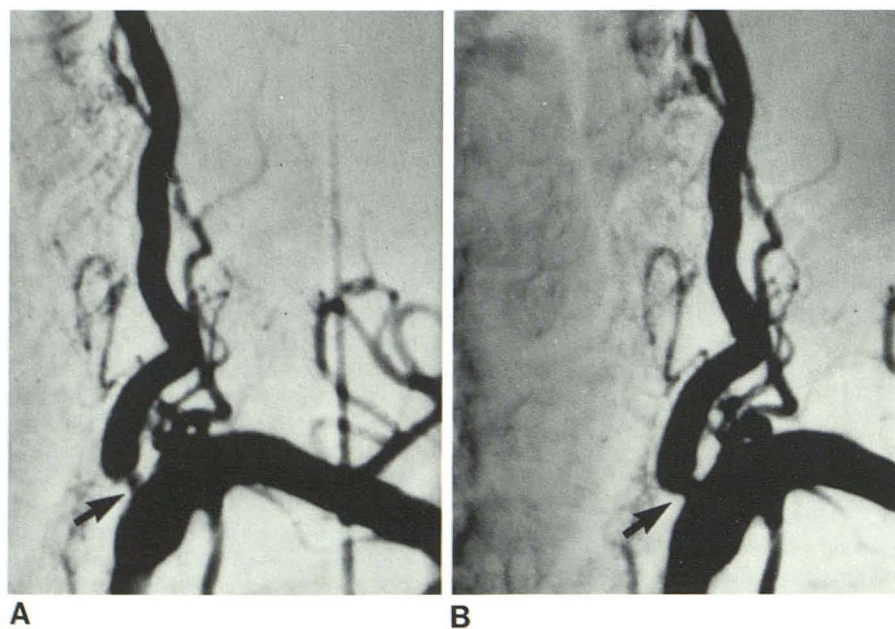


Fig. 4.—Case 3, 72-year-old man with severe dizziness that prevented walking. Carotid arteriogram (not shown) showed no occlusive disease. **A**, Left subclavian arteriogram. Severe stenosis of origin of left vertebral artery (arrow). **B**, Postangioplasty subclavian arteriogram. Dilatation of vertebral artery stenosis (arrow).

stenosis of the left subclavian artery with a subclavian steal (figs. 5A and 5B). There was 100 mm Hg pressure gradient across the stenosis. The subclavian artery was dilated, but the subclavian steal was not immediately corrected (fig. 5C). Postangioplasty arterial pressure measurements indicated a 40 mm Hg residual pressure gradient. The patient continued to have occasional mild dizziness, but refused the option of reconstructive vascular surgery.

## Discussion

Enderarterectomy of the carotid artery bifurcation is a rather simple and generally effective procedure, but surgical treatment of subclavian vertebral artery disease is more complex. Many patients with subclavian artery disease undergo an intrathoracic operation for endarterectomy or bypass sur-



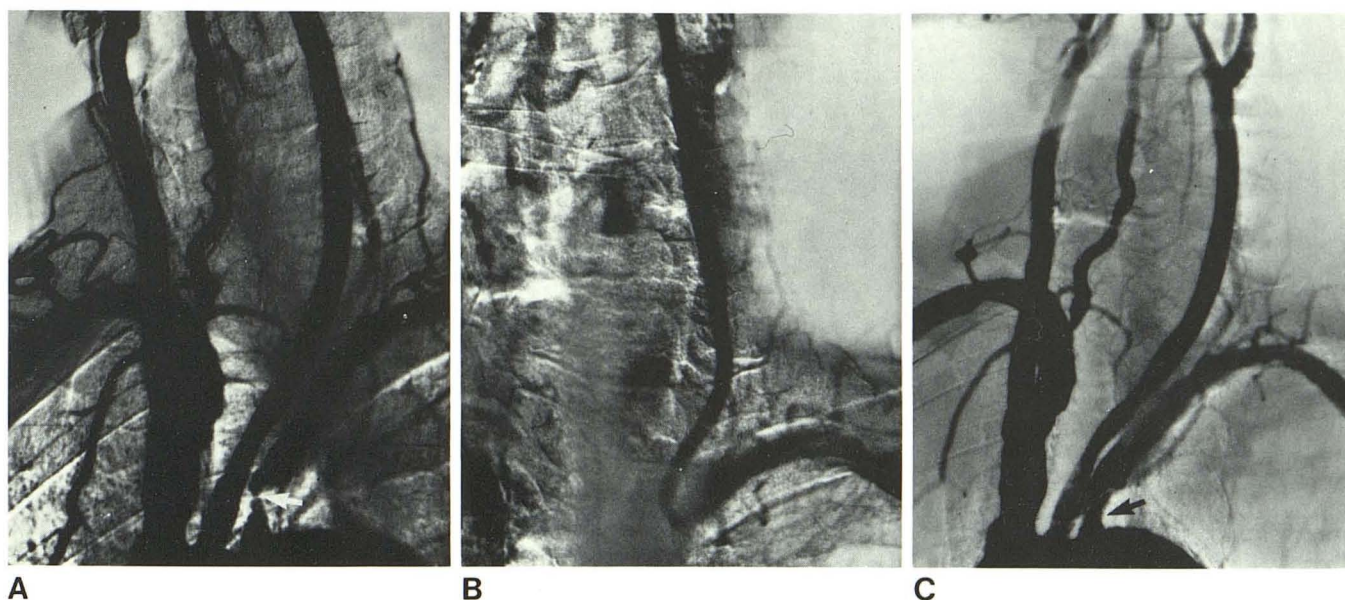


Fig. 5.—Case 4, 62-year-old man with severe dizziness, occasional numbness of left arm, and one episode of drop attack. **A**, Arch aortogram. Almost total occlusion of proximal subclavian artery in subclavian steal (arrow). **B**,

Retrograde flow of vertebral artery in subclavian steal. **C**, Postangioplasty arch aortogram. Improved stenosis of subclavian artery (arrow), however, subclavian steal is not corrected.

gery. More recently extrathoracic approaches, such as carotid subclavian, axilloaxillary, and femoroaxillary bypass graft, have been used [11]. Complication rates of both the intrathoracic and extrathoracic operations are similar and reported to be as high as 23% [11]. Chylothorax, endarterectomy thrombosis, pneumothorax, pleural effusion, neck lymph fistula, phrenic nerve palsy, and Horner syndrome are among the most serious and worthy of mention.

We believe transluminal angioplasty, on the other hand, is an effective nonsurgical treatment with fewer complications when it is applied in selected cases. Our series, although small in number, shows favorable results, especially in the case of the vertebral artery, and no significant complications. This is mainly due to careful selection of cases and exclusion of potentially high-risk patients. This is especially true in patient selection for vertebral artery angioplasty. Dilatation of a vertebral artery stenosis was never attempted if the diseased vertebral artery was the only contributor to the basilar system circulation; neither was an isolated vertebral artery dilated if it was feeding an isolated posterior inferior cerebellar artery.

Substantial experience in arterial dilatation is a prerequisite for any angiographer before attempting to dilate a vertebral artery stenosis. If catheterization of the vertebral artery or insertion and advancing the guide wire within the vertebral artery is technically difficult, the procedure should be terminated. Dilatation of carotid stenoses bears a high risk of cerebral emboli from an ulcerated plaque; however, ulcerated plaques are rarely seen in the vertebral artery. Stenotic lesions of the vertebral artery occur mainly at the origin of the artery and are nonulcerated. We consider vertebral artery angioplasty only when the stenotic lesion is

at the origin of the artery and in the absence of additional atherosclerotic disease in the vertebral basilar system or carotid arteries. Vertebral artery dilatation should only be attempted if surgery is warranted and can be scheduled as a back-up measure.

The importance of the external carotid artery as a source of collateral blood supply in carotid artery occlusion is well established [12]. There are several reports of total recovery from recurrent transient cerebral ischemia after endarterectomy of the external carotid artery in patients with an occluded carotid artery [13–15]. If the internal carotid artery is occluded and there is no cross-filling of the ipsilateral anterior and middle cerebral arteries from the contralateral carotid artery, the ipsilateral external carotid artery may be the only source of perfusion of the cerebral hemisphere. Since the blood flow is through a number of small collateral arteries, transluminal angioplasty of the external carotid artery in these cases does not bear a high risk of cerebral emboli, thus offering an alternative to surgical endarterectomy. Although our case of external carotid artery stenosis was treated intraoperatively, we would attempt a percutaneous approach in treatment of nonulcerated stenosis of the external carotid artery. The complications of transluminal angioplasty, including hematoma, arterial thrombosis, distal emboli, and dissection, have been reported by us [16] and others, but there were no complications during or after the procedures reported here.

#### REFERENCES

1. Grüntzig A, Hopff H. Perkutane Rekanalisation chronischer arterieller Verschlüsse mit einem neuen Dilatationskatheter

- Modifikation der Dotter-Technik. *Dtsch Med Wochenschr* **1974**;99:2502-2505
2. Dotter CT, Judkins MP. Transluminal treatment of arteriosclerotic obstruction. Description of a new technic and a preliminary report of its application. *Circulation* **1964**;30:654-670
  3. Grüntzig A, Myler R, Stertzer S, Kaltenback M, Turina M. Coronary percutaneous transluminal angioplasty: preliminary results (abstr). *Circulation* **1978**;57 & 58:II-56
  4. Grüntzig A, Vetter W, Meier B, Kuhlmann U, Lütolf U, Siegenthaler W. Treatment of renovascular hypertension with percutaneous transluminal dilatation of a renal artery stenosis. *Lancet* **1978**;1:801-820
  5. Tegtmeier CJ, Dyer R, Teates CD, et al. Percutaneous transluminal dilatation of the renal arteries. *Radiology* **1980**;135:589-599
  6. Schwarten DE, Yune HY, Klatte EC, Grim CE, Weinberger MH. Clinical experience with percutaneous transluminal angioplasty (PTA) of the stenotic renal arteries. *Radiology* **1980**;135:601-604
  7. Katzen BT, Chang J. Percutaneous transluminal angioplasty with the Grüntzig balloon catheter. *Radiology* **1979**;130:623-626
  8. Motarjeme A, Keifer JW, Zuska AJ. Percutaneous transluminal angioplasty of the deep femoral artery. *Radiology* **1980**;135:613-617
  9. Motarjeme A, Keifer JW, Zuska AJ. Percutaneous transluminal angioplasty of the iliac arteries: 66 experiences. *AJR* **1980**;135:937-944
  10. Motarjeme A, Keifer JW, Zuska AJ. Percutaneous transluminal angioplasty of the vertebral artery. *Radiology* **1981**;139:715-717
  11. Beebe HG, Stark R, Johnson ML, Jolly PC, Hill LD. Choices of operation for subclavian-vertebral artery disease. *Am J Surg* **1980**;139:616-623
  12. Jackson BB. The external carotid as a brain collateral. *Am J Surg* **1967**;113:375-378
  13. Clayson KR, Edwards WH. Importance of the external carotid artery in extracranial cerebrovascular occlusive disease. *South Med J* **1977**;70:904-909
  14. Dietrich EB, Liddicoat JE, McCutchen JJ, De Bakey ME. Surgical significance of the external carotid artery in the treatment of cerebrovascular insufficiency. *J Cardiovasc Surg (Torino)* **1968**;9:213-223
  15. Countee RW, Vijayanathan T. External carotid artery in internal carotid artery occlusion. Angiographic, therapeutic and prognostic considerations. *Stroke* **1979**;10:450-460
  16. Motarjeme A, Keifer JW, Zuska AJ. Percutaneous transluminal angioplasty and case selection. *Radiology* **1980**;135:573-581